

# Research Paper: Radiologic Assessment for Evaluating the Post-operative Reduction of Syndesmosis: A Retrospective Study



Ali Yeganeh<sup>1</sup> , Mehdi Moghtadaei<sup>1</sup> , Babak Otoukesh<sup>1</sup> , Mohammad Soleymani<sup>1</sup>, Seyed Mani Mahdavi<sup>1</sup> , Shayan Amiri<sup>2\*</sup>

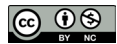1. Department of Orthopaedic Surgery, Faculty of Medicine, Iran university of Medical Sciences, Tehran, Iran.

2. Department of Orthopaedic Surgery, Rasoul Akram Hospital, Iran university of Medical Sciences, Tehran, Iran.



**Citation** Yeganeh A, Moghtadaei M, Otoukesh B, Soleymani M, Mahdavi SM, Amiri Sh. Radiologic Assessment for Evaluating the Post-operative Reduction of Syndesmosis: A Retrospective Study. 2021; 8(1):29-36. <http://dx.doi.org/10.32598/JROSJ.8.1.746.1>

**doi**: <http://dx.doi.org/10.32598/JROSJ.8.1.746.1>



## Article info:

**Received:** 17 Nov 2020

**Revised:** 25 Nov 2020

**Accepted:** 15 Jan 2021

**Available Online:** 01 February 2021

## Keywords:

Syndesmosis failure, Ankle fracture, CT scan, Plain radiographs

## ABSTRACT

**Background:** Assessing the reduction of syndesmosis is highly recommended due to the complications occurring after the malreduction of the syndesmosis. This study evaluated the post-operative Computed Tomography (CT) scans and standard plain radiographs for assessing the reduction of syndesmosis post-operatively.

**Objectives:** Evaluating the radiologic assessments of post-operative reduction of syndesmosis.

**Methods:** In this retrospective cohort study, 45 patients presented with ankle fractures and syndesmosis failure to the emergency department of our hospital between 2015 and 2019 were evaluated by post-operative CT scans and plain radiographs.

**Results:** Diastasis was demonstrated in 18 patients (40%) in plain radiographs, in 4 patients (8%) by tibial clear space, in 5 patients (11%) by medial clear space, in 10 patients (22%) by AP tibiofibular overlap, and in patients 8 (17%) by mortise tibiofibular overlap. Diastasis was demonstrated in 24 patients (53%) in CT scans, of whom 18 patients had abnormal radiographic parameters, while 6 patients had normal radiographic parameters.

**Conclusion:** We found a post-operative CT scan more useful than standard plain radiographic measurement for assessing the reduction of the syndesmosis. We suggest the use of post-operative CT scan as a routine to evaluate the syndesmosis reduction.

## \* Corresponding Author:

Shayan Amiri, MD.

**Address:** department of Orthopaedic Surgery, Rasoul Akram Hospital, Iran university of Medical Sciences, Tehran, Iran.

**Phone:** +98 (912) 4578109

**E-mail:** amiri.shayan23@gmail.com

## 1. Introduction

**S**yndesmosis injuries may occur either isolated or with ankle fractures. Reduction of syndesmosis is imperative due to the poor subjective outcomes and accelerated ankle arthrosis caused by malreduction and syndesmosis instability [1]. This injury is problematic due to the complexities of diagnosis and treatment and post-operation evaluation [2]. In order to assess the integrity of the ankle and syndesmosis, several radiographic parameters are used, measured on Anteroposterior (AP) and mortise views of the ankle [3-5]. However, several studies have demonstrated that the traditional radiographic parameters may not be delicate to assess the syndesmosis reduction [6, 7]. Another diagnostic tool for evaluating the integrity of syndesmosis is Computed Tomography (CT) scanning, which is more sensitive and can detect the syndesmosis malreduction, which can hardly be detected in plain radiography [2, 8].

Due to the high incidence of this injury and the importance of evaluating the post-operative reduction, surgeons require to be aware of different radiologic evaluations and their accuracy rate.

In the present study, we evaluated the accuracy of the post-operational routine plain radiograph versus CT scan for assessing the reduction of the syndesmosis in a series of patients with ankle fractures and syndesmotic failure.

## 2. Patients and Methods

This study was approved by the review board of our institute, and patients provided written consent to use their medical data for publication. In a retrospective cohort, 45 patients presented with ankle fractures and syndesmosis failure to the emergency department of our hospital between 2015 and 2019 were evaluated. Preoperative diagnosis of syndesmosis failure was made by the surgeons' experience using plain radiographs and CT scans, and it was confirmed by intra-operative fluoroscopic stress tests. Open reduction and internal fixation were done using the routine surgical techniques by one specified surgeon. The syndesmosis reduction was made by screw application under fluoroscopic evaluation using a large pointed clamp with the foot in 10 degrees of dorsiflexion. After the syndesmotic screw fixation, the surgeon repeatedly performed the fluoroscopic stress tests and applied a short-leg-splint for all patients. The patients were discharged after 2 days and they were visited in the clinic after 2 weeks. One and 3 months after

the surgery and in the third month, the screws were removed. All patients had an AP and mortise radiographic series and an axial CT scan post-operatively to assess the syndesmosis reduction. The plain radiographs and CT scans were evaluated by three radiologists, and the average values were measured for analysis. We used the normal tibiofibular relationship criteria as Tibiofibular Clear Space (TCS) less than 6 mm, Tibiofibular Overlap (TFO) greater than 6 mm in AP view, TFO greater than 1 mm in mortise view, and Medial Clear Space (MCS) less than 5 mm [3, 5, 9-11]. The anterior difference was considered as the distance between the incisura's most anterior point and the fibula's nearest most anterior point, posterior difference as the difference between the incisura's most posterior point and the fibula's nearest most posterior point, middle difference as the difference between tibia and fibula in the middle of incisura, Anterior Tibiofibular Interval (ATF) as the distance between the anterior tibia and the anterior fibula, Tibial Clear Space (TCS) as the interval between the posterior tibial tubercle's tip and the medial fibula, Tibiofibular Overlap (TFO) as the interval between the anterior tibial tubercle and the medial fibula, and fibular rotation as the angle between two lines: the line tangential to the anterior and posterior tibial tubercles and the line that goes through the anterior and posterior fibular tubercles [12].

For evaluating the reduction of syndesmosis in the CT scan, we used the distance between the fibula and the facets of the incisura anteriorly and posteriorly along a line perpendicular to the joint space. More than 2 mm differences between the anterior and posterior measurements were considered incongruous. Our hospital CT scan slice thickness is 2.5 mm; therefore, the fourth CT cuts above the tibiofibular joint level, approximately 1 cm proximal to the joint was used [10].

SPSS software v. 16 was used for the statistical analysis of the data. Descriptive statistics were expressed as Mean±Standard Deviation and number and percentage. Moreover, we compared the pre-operation and post-operation radiologic measurements using a one-sample t-test. A P-value of <0.05 was considered significant.

## 3. Results

In this study, 45 patients were evaluated, of whom 30 were males (67%) and 15 females (33%). Furthermore, the injury was in the right leg in 29 patients (64.4%) and the left leg in 16 others (35.6%). The mean age of participants was 40.4 years, with an age range of 16 to 73 years.

**Table 1.** Pre-operative and post-operative values in plain radiographs

Variables	Mean±SD		P
	Preoperative	Postoperative	
Tibial clear space	5.26±3.12 mm	3.25±1.99 mm	<0.001*
Medial clear space	6.32±6.23 mm	3.61±2.03 mm	0.011*
AP TFO	6.25±3.79 mm	8.29±3.58 mm	0.008*
Mortise TFO	3.05±3.89 mm	6.88±7.34 mm	0.569

\* Statistically significant difference (P<0.05).

Journal of Research in  
**Orthopedic Science**

**Table 2.** Pre-operative and post-operative values of the CT scan

Variables	Mean±SD		P
	Preoperative	Postoperative	
Tibial clear space	2.58±1.94 mm	2.18±1.45 mm	0.29
TFO	1.05±1.68 mm	5.03±3.80 mm	0.24
ATF	12.6±5.96 mm	10.28±3.20 mm	0.13
Anterior difference	13.9±9.37 mm	6.08±3.59 mm	0.112
Middle difference	7.36±4.74 mm	2.08±1.39 mm	0.003*
Posterior difference	11.03±6.46 mm	7.08±2.42 mm	0.238
Fibular rotation	11.19°±9.72°	8.84°±11.44°	0.094

\* Statistically significant difference (P<0.05).

Journal of Research in  
**Orthopedic Science**

**Table 3.** Number and frequencies of diastasis by each index

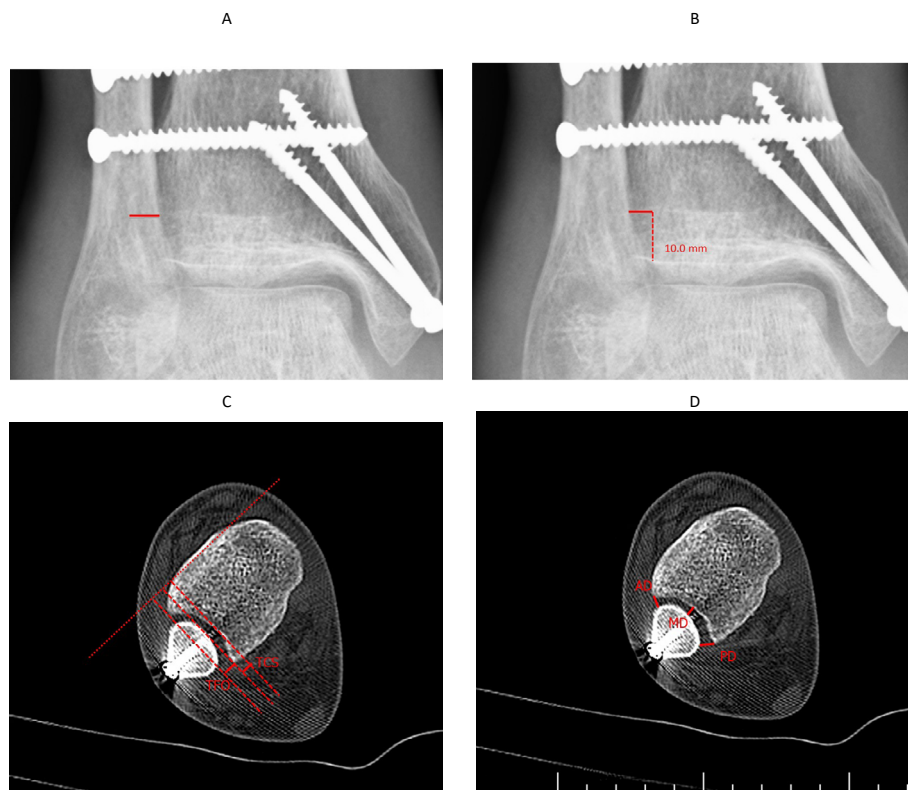
Index (Before)	No. (%)	Index (After)	No. (%)
Tibial clear space	31 (68)	Tibial clear space	4 (8)
Medial clear space	23 (51)	Medial clear space	5 (11)
AP TFO	23 (51)	AP TFO	10 (22)
Mortise TFO	25 (45)	Mortise TFO	8 (17)
CT tibial clear space	21 (46)	CT tibial clear space	14 (31)
CT TFO	20 (42)	CT TFO	15 (33)
CT ATF	19 (42)	CT ATF	5 (11)
Anterior difference	40 (88)	Anterior difference	17 (37)
Middle difference	37 (82)	Middle difference	13 (28)
Posterior difference	30 (66)	Posterior difference	14 (41)
Fibular rotation	23 (51)	Fibular rotation	16 (35)

Journal of Research in  
**Orthopedic Science**

**Table 4.** Number of outliers in each value

Index (Before)	Number of Outliers	Index (After)	Number of Outliers
Tibial clear space	1	Tibial Clear Space	0
Medial clear space	3	Medial Clear Space	2
AP TFO	0	AP TFO	0
Mortise TFO	4	Mortise TFO	4
CT tibial clear space	1	CT Tibial Clear Space	0
CT TFO	2	CT TFO	1
CT ATF	1	CT ATF	0
Anterior difference	2	Anterior Difference	1
Middle difference	0	Middle Difference	0
Posterior difference	2	Posterior Difference	1
Fibular rotation	3	Fibular Rotation	0

Journal of Research in  
**Orthopedic Science**



Journal of Research in  
**Orthopedic Science**

**Figure 1.** Plain radiography and CT scan

A. Post-operative Tibiofibular Overlap (TFO) in the plain radiograph; B. Post-operative Tibiofibular Clear Space (TCS) in the plain radiograph; C. Post-operative Tibiofibular Clear Space (TCS) and Tibiofibular Overlap (TFO) in CT scan; D. Post-operative anterior and posterior differences in CT scan.

We assessed TCS and MCS using AP radiographs. TFO was measured using both AP and Mortise view radiographs (Table 1). Plain radiographs before the operation displayed diastasis in 31 (68%), 23 (51%), 23, (51%), and 25 (45%) patients using TCS, MCS, AP TFO, and mortise TFO, respectively. Diastasis was demonstrated in 18 patients (40%) in plain radiographs, in 4 patients (8%) by TCS, in 5 patients (11%) by MCS, in 10 patients (22%) by AP TFO, and in 8 patients (17%) by Mortise TFO.

Moreover, by using axial CT scans, we assessed TCS, TFO, ATF, anterior difference, middle difference, posterior difference, and fibular rotation Table 2. Preoperative CT scans showed diastasis in 21 (46%), 20 (42%), 19 (42%), 40 (88%), 37 (82%), 30 (66%), and 23 (51%) patients through TCS, TFO, ATF, anterior difference, Middle difference, posterior difference, and fibular rotation, respectively (Figure 1). Diastasis was demonstrated in 24 patients (53%) in post-operative CT scans in total, of which 18 patients had abnormal radiographic parameters, while 6 patients had normal radiographic parameters. TCS in CT scan showed diastasis in 14 patients (31%) in which 6 (13%) had normal radiographs. TFO in CT scan demonstrated diastasis in 15 patients (33%), in which 3 (6%) had normal radiographs. ATF, anterior difference, middle difference, posterior difference, and fibular rotation displayed diastasis in 5 (11%), 17 (37%), 13 (28%), 14 (41%), and 16 (35%) patients, respectively. In Table 3, we presented the number and frequencies of diastasis by each index and in Table 4, we provided the number of outliers in each value.

Analyzing TCS and TFO, which were assessed in both plain radiographs and CT scans, displayed diastasis in more patients in CT scans than in plain radiographs. Furthermore, anterior difference, posterior difference, and fibular rotation, obtained from CT scan, demonstrated diastasis, which was assumed to be absent through interpreting radiographs. However, ATF and middle difference parameters on the CT scan indicated that the syndesmosis injury was corrected.

#### 4. Discussion

Syndesmosis, located in the distal tibiofibular joint, consists of four ligaments: the interosseous ligament, the anterior inferior tibiofibular ligament, the posterior inferior tibiofibular ligament, and the inferior transverse ligament. Ankle joint motion is completely dependent on the rotation, translation, and migration of the fibula at the syndesmosis level [13]. Malreduction of syndesmosis leads to several complications, such as joint degeneration, causing osteoarthritis, instability of the ankle

joint, load distribution insufficiency, pain, and limping. The importance of a good reduction is always an important concern for orthopedic surgeons. Leads et al. [14] assessed 34 patients with ankle fractures associated with syndesmosis injury and reported that an adequate reduction of the syndesmosis is mandatory to reduce the injury complications. However, assessing the reduction of the syndesmosis, especially after the operative interventions, is still a topic of debate.

The present study results confirmed the previous studies, demonstrating low sensitivity of standard radiographic measurement in evaluating the syndesmosis reduction [6, 15, 16]. Gardner et al. (2006) studied 25 patients who underwent post-operational plain radiographic series and CT scans to assess syndesmosis reduction and reported that many syndesmoses were malreduced regarding the CT scan; however, they were not detected by interpreting plain radiographs [2]. Our results were similar to their study; among 45 patients, a post-operational CT scan showed malreduction in 24 patients, while only 18 patients had abnormal radiographic findings. In 1997, Ebrahim et al. used 12 cadaveric lower limbs to assess the syndesmosis by radiographs and CT scans. They detected minor syndesmotoc diastasis in CT scans that were not visible on routine radiographs [8].

In the literature, as in our study, a CT scan is superior to traditional radiographs to assess the syndesmosis [2, 5, 6, 8, 10, 17-19]. Beumer et al. in 2004, obtained radiographs of 20 plastinated human cadaveric lower legs in 12 positions of rotation and their results showed that no optimal radiographic parameter exists for assessing syndesmotoc congruency [6]. However, because of normal anatomic variations between individuals and anatomic measurements of genders in different parts of the body, CT scan sensitivity may be questioned. Gregory et al. (2012) evaluated 30 healthy volunteers who underwent a CT scan assessment of bilateral ankle fracture [20]. Although they found anatomic variability between individuals and genders, they reported that tibiofibular intervals do not vary by more than 2.3 mm, and the rotation of the fibula does not vary by more than 6.5 degrees between ankles of the same person. These criteria allow for the detection of variations in the tibiofibular relationships indicating instability. They also demonstrated that the measurements of tibiofibular relationships made on axial CT images are reliable.

This research was a retrospective study with limited patients without long-term clinical and radiological follow-up. Therefore, future large-scale studies are required to confirm the result of this study.

## 5. Conclusion

Reduction of syndesmosis has an important role in the stability and function of the ankle joint, and evaluating the post-operative reduction of syndesmosis is necessary. We found a post-operative CT scan more useful than standard plain radiographic measurement for assessing the reduction of the syndesmosis, and surgeons should use the post-operative CT scan as a routine to evaluate the syndesmosis reduction.

## Ethical Considerations

### Compliance with ethical guidelines

This study ethically approved by the Ethics Committee of Iran University of Medical Sciences. also it observed the Helsinki Declaration and its later amendments and before the study, the patients gave their informed consent to participate in this study.

### Funding

This research did not receive any grant from funding agencies in the public, commercial, or non-profit sectors.

### Authors' contributions

All authors contributed in preparing this article.

### Conflict of interest

The authors declared no conflict of interest.

## References

- [1] Procter P, Paul JP. Ankle joint biomechanics. *J Biomech.* 1982; 15(9):627-34. [DOI:10.1016/0021-9290(82)90017-3]
- [2] Gardner MJ, Demetrakopoulos D, Briggs SM, Helfet DL, Lorch DG. Malreduction of the tibiofibular syndesmosis in ankle fractures. *Foot Ankle Int.* 2006; 27(10):788-92. [DOI:10.1177/107110070602701005] [PMID]
- [3] Harper MC, Keller TS. A radiographic evaluation of the tibiofibular syndesmosis. *Foot Ankle.* 1989; 10(3):156-60. [DOI:10.1177/107110078901000308] [PMID]
- [4] Joy G, Patzakis MJ, Harvey Jr JP. Precise evaluation of the reduction of severe ankle fractures: Technique and correlation with end results. *J Bone Joint Surg Am.* 1974; 56(5):979-93. [DOI:10.2106/00004623-197456050-00010] [PMID]
- [5] Sclafani SJ. Ligamentous injury of the lower tibiofibular syndesmosis: Radiographic evidence. *Radiology.* 1985; 156(1):21-7. [DOI:10.1148/radiology.156.1.4001407] [PMID]
- [6] Beumer A, van Hemert WLW, Niesing R, Entius CAC, Ginai AZ, Mulder PGH, et al. Radiographic measurement of the distal tibiofibular syndesmosis has limited use. *Clin Orthop Relat Res.* 2004; (423):227-34. [DOI:10.1097/01.blo.0000129152.81015.ad] [PMID]
- [7] Nielson JH, Sallis JG, Potter HG, Helfet DL, Lorch DG. Correlation of interosseous membrane tears to the level of the fibular fracture. *J Orthop Trauma.* 2004; 18(2):68-74. [DOI:10.1097/00005131-200402000-00002] [PMID]
- [8] Ebraheim NA, Lu J, Yang H, Mekhail AO, Yeasting RA. Radiographic and CT evaluation of tibiofibular syndesmosis diastasis: A cadaver study. *Foot Ankle Int.* 1997; 18(11):693-8. [DOI:10.1177/107110079701801103] [PMID]
- [9] Bozic KJ, Jaramillo D, DiCanzio J, Zurakowski D, Kasser JR. Radiographic appearance of the normal distal tibiofibular syndesmosis in children. *J Pediatr Orthop.* 1999; 19(1):14-21. [DOI:10.1097/00004694-199901000-00005] [PMID]
- [10] Ebraheim NA, Elgafy H, Padanilam T. Syndesmosis disruption in low fibular fractures associated with deltoid ligament injury. *Clin Orthop Relat Res.* 2003; 409:260-7. [DOI:10.1097/01.blo.0000052935.71325.30] [PMID]
- [11] Takao M, Ochi M, Oae K, Naito K, Uchio Y. Diagnosis of a tear of the tibiofibular syndesmosis: The role of arthroscopy of the ankle. *J Bone Joint Surg Br.* 2003; 85(3):324-9. [DOI:10.1302/0301-620X.85B3.13174] [PMID]
- [12] Nault ML, Hébert-Davies J, Laflamme GY, Leduc S. CT scan assessment of the syndesmosis: A new reproducible method. *J Orthop Trauma.* 2013; 27(11):638-41. [DOI:10.1097/BOT.0b013e318284785a] [PMID]
- [13] Beumer A, Valstar ER, Garling EH, Niesing R, Ransam J, Löfvenberg R, et al. Kinematics of the distal tibiofibular syndesmosis: Radiostereometry in 11 normal ankles. *Acta Orthop Scand.* 2003; 74(3):337-43. [DOI:10.1080/00016470308540850] [PMID]
- [14] Leeds HC, Ehrlich MG. Instability of the distal tibiofibular syndesmosis after bimalleolar and trimalleolar ankle fractures. *J Bone Joint Surg Am.* 1984; 66(4):490-503. [DOI:10.2106/00004623-198466040-00002]
- [15] Muratlı HH, Biçimoğlu A, Çelebi L, Boyacıgil S, Damgacı L, Tabak AY. Magnetic resonance arthrographic evaluation of syndesmosis diastasis in ankle fractures. *Arch Orthop Trauma Surg.* 2005; 125(4):222-7. [DOI:10.1007/s00402-004-0721-2] [PMID]
- [16] Takao M, Ochi M, Naito K, Iwata A, Kawasaki K, Tobita M, et al. Arthroscopic diagnosis of tibiofibular syndesmosis disruption. *Arthroscopy.* 2001; 17(8):836-43. [DOI:10.1016/S0749-8063(01)90007-6] [PMID]
- [17] Magid D, Michelson JD, Ney DR, Fishman EK. Adult ankle fractures: Comparison of plain films and interactive two- and three-dimensional CT scans. *AJR Am J Roentgenol.* 1990; 154(5):1017-23. [DOI:10.2214/ajr.154.5.2108536] [PMID]
- [18] Chan KB, Lui TH. Isolated anterior syndesmosis diastasis without fracture. *Arch Orthop Trauma Surg.* 2007; 127(5):321-4. [DOI:10.1007/s00402-007-0296-9] [PMID]
- [19] Lindsjö U, Hemmingsson A, Sahlstedt B, Danckwardt-Lillieström G. Computed tomography of

the ankle. *Acta Orthop Scand.* 1979; 50(6):797-801. [DOI:10.3109/17453677908991312] [PMID]

- [20] Dikos GD, Heisler J, Choplin RH, Weber TG. Normal tibi-ofibular relationships at the syndesmosis on axial CT imaging. *J Orthop Trauma.* 2012; 26(7):433-8. [DOI:10.1097/BOT.0b013e3182535f30] [PMID]

---

This Page Intentionally Left Blank

---