



*Original Article*

## Surgical approach to posterior dislocation of the elbow combined with radial head and coronoid fractures (terrible triad): report of 19 cases

Kaveh Gharanizadeh<sup>1</sup>, \*Farid Najd Mazhar<sup>2</sup>, Sepideh Pezeshki<sup>3</sup>  
Mahgol Farjadnia<sup>4</sup>, Behrooz Givechian<sup>5</sup>, Hooman Shariatzadeh<sup>6</sup>

Department of Hand Surgery, Shafa Orthopedic Hospital, Iran University of Medical Sciences, Tehran, Iran.

Received: 20 Sep 2012    Revised: 20 Nov 2012    Accepted: 25 Jan 2013

### Abstract

**Background:** Terrible triad injury of the elbow has been a real challenge for surgeons. New standard methods of treatment have significantly improved outcomes, but yet complications occur frequently and rate of reoperation is still noticeable.

**Methods:** The outcomes of lateral surgical approach in 19 patients with terrible triad injury were evaluated through Mayo Elbow Performance Score (MEPS) and Disabilities of the Arm, Shoulder and Hand (DASH) score.

**Results:** A concentric congruency was achieved for 18 cases. The average of MEPS was  $87.11 \pm 12.05$ . Therefore, 17 patients had excellent and good and two fair and poor results. Average of DASH score was  $17 \pm 13.83$ . Due to early postoperative dislocation joint stiffness occurred in one patient.

**Conclusion:** In our experience, lateral approach provides an adequate view to access and reconstruct all stabilizing elements and could be considered as an acceptable option in terrible triad injury treatment.

**Keywords:** Complication, Elbow, Lateral approach, Terrible triad.

### Introduction

Isolated dislocation of elbow usually can be managed without serious complications. Nonetheless, when this dislocation is complicated with radial head and coronoid fractures (terrible triad), surgical management usually yields poor outcome (1).

The terrible triad common postoperative

ly osteoarthritis and joint stiffness (2). Unfortunately, most of victims with complex elbow dislocation are among active youths and faced with partial disability of elbow, imposed financial burdens and long term complications.

Recent insight into biomechanical structure of elbow joint has evolved surgical protocols with respect to the surrounding structures which stabilize the elbow. Previous studies (3,4) showed that the adherence to standard protocols, reconstruction of coronoid process and radial head and surrounding soft tissue yield more acceptable results.

The terrible triad is uncommon; however, due to large number of patients referred to our center (i.e. Shafa Orthopedic Hospital), we could collect sufficient data to investigate the subject and report the outcomes. The current study aimed to denote improvement of current surgical techniques and help to minimize the subsequent complications of the elbow dislocation injuries.

1. MD., Assistant Professor of Orthopedic Surgery, Shafa Orthopedic Hospital, Iran University of Medical Sciences, Tehran, Iran. [kavehgharani@gmail.com](mailto:kavehgharani@gmail.com)

2. (**Corresponding author**) MD., Assistant Professor of Orthopedic Surgery, Shafa Orthopedic Hospital, Iran University of Medical Sciences, Tehran, Iran. [najdmazhar.f@iums.ac.ir](mailto:najdmazhar.f@iums.ac.ir)

3. MD., Iran University of Medical Sciences, Tehran, Iran. [sepid.p80@gmail.com](mailto:sepid.p80@gmail.com)

4. MD., Iran University of Medical Sciences, Tehran, Iran. [mahgolfarjadnia@gmail.com](mailto:mahgolfarjadnia@gmail.com)

5. MD., Resident of Orthopedic Surgery, Shafa Orthopedic Hospital, Iran University of Medical Sciences, Tehran, Iran. [behrooz1725@yahoo.com](mailto:behrooz1725@yahoo.com)

6. MD., Assistant Professor of Orthopedic Surgery, Shafa Orthopedic Hospital, Iran University of Medical Sciences, Tehran, Iran. [shariatzadeh\\_h@hotmail.com](mailto:shariatzadeh_h@hotmail.com)

## Methods

After receiving required ethical permissions, we retrospectively recruited data including medical records and radiographs of all patients who underwent surgical intervention for terrible triad injury from 2005 to 2009.

The coronoid and radial head fractures were categorized according to Regan-Morrey (5) and Mason-Johnston radiologic classifications (6), respectively.

All operations were performed by two attending surgeons under general anesthesia and supine position. Direct lateral incision of the elbow was used and after dissecting the fascia, existed avulsion or rupture in the lateral collateral ligament (LCL) was expanded. When the ligament was intact, the Extensor Digitorum Communis (EDC) and the anterior one third of the lateral collateral ligament were longitudinally split and the lateral ulnar collateral ligament was preserved. Hemarthrosis was evacuated and the joint was explored for debridement of crushed chondral fragments that were rather common on the humeral side.

We used transosseous suture fixation to manage the coronoid fracture as described in O'Driscoll et al study (6). Two holes were drilled on the coronoid fragment and a non-absorbable suture was passed through the fragment and the attached part of the anterior capsule. After making a small 2cm incision over the ulnar metaphysis, two 2mm wide holes were drilled on the proximal posterior part of the ulna aiming to the base of coronoid process using "free hand technique". Sutures were subsequently passed through the holes and held for later repair at the end of the surgery.

It was planned to reconstruct all types of radial head fractures. 1.5, 2 and 2.7mm mini fragment screws along with 2 and 2.7mm miniplates were applied. T plate was used in cases with radial neck fractures or comminuted fractures. For type III radial head fracture we performed either resection or radial head arthroplasty to manage the fracture. We performed resection in three cases and radial head arthroplasty in one type III radial

head fracture. A metal prosthesis (Evolve, Modular Radial Head System, Wright Medical Technology) was used in this case.

In 90° of flexion, last step of transosseous fixation of coronoid fragment and the attached part of anterior capsule were completed and the sutures were tied. Major part of the lateral collateral ligament was transosseously fixed on the footprint of its attachment site to the lateral epicondyle using nonabsorbable sutures.

Finally, the stability of the elbow was assessed in pronation, taken through a flexion-extension arc of motion.

In cases with severe soft tissue injury that entire soft tissue attachment was shaved from distal humerus, an anteroposterior hole was drilled on lateral margin of distal humerus and the facia of anterior and posterior compartments were intraosseously fixed to enhance the stability of the joint. A long arm splint was applied and the arm was positioned in 90° of flexion with the forearm in 45° pronation to protect the lateral collateral ligament (LCL).

Postoperatively, all patients received 25 mg indomethacin three times a day for four weeks to prevent heterotopic ossification.

The splint was usually removed between 3 to 4 weeks after surgery based on the severity of pain. Physical therapy exercises were started with active range of motion and continuous passive motion (CPM). The patients were then evaluated weekly for 6 weeks. Thereafter, they were assessed clinically and radiologically in 3<sup>rd</sup>, 6<sup>th</sup>, 9<sup>th</sup>, and 12<sup>th</sup> month and then yearly.

At the last follow up visit, results of the surgery were assessed using Mayo Elbow Performance Score (MEPS) and Disabilities of the Arm, Shoulder and Hand "DASH" score.

Radiography was used for evaluation of congruency state, appropriate reduction of elbow joint and union of radial head and coronoid process. Complications like heterotopic ossification and re-dislocation or subluxation of the elbow joint were also radiologically assessed.

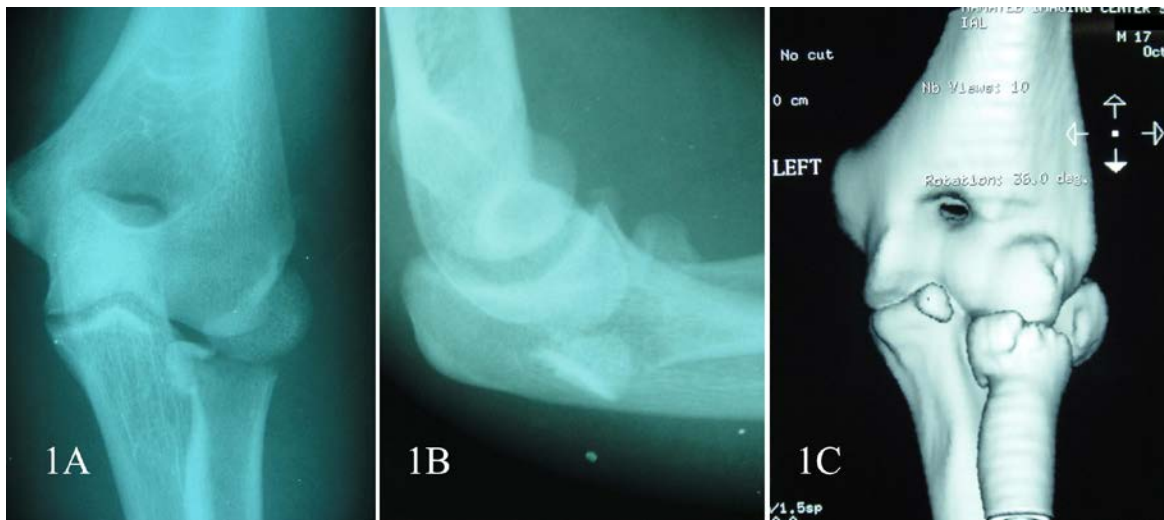## Results

We obtained data of 19 skeletally mature patients (13 males and 6 females) with average age of 32.16 (16-54) years. Fifteen patients were injured after a simple fall, two after a fall from height and two after motor-bike accident. There was a radial nerve injury in one case which recovered spontaneously after 12 weeks. No one had open wounds. The mean follow up period was  $24.32 \pm 11.09$  months.

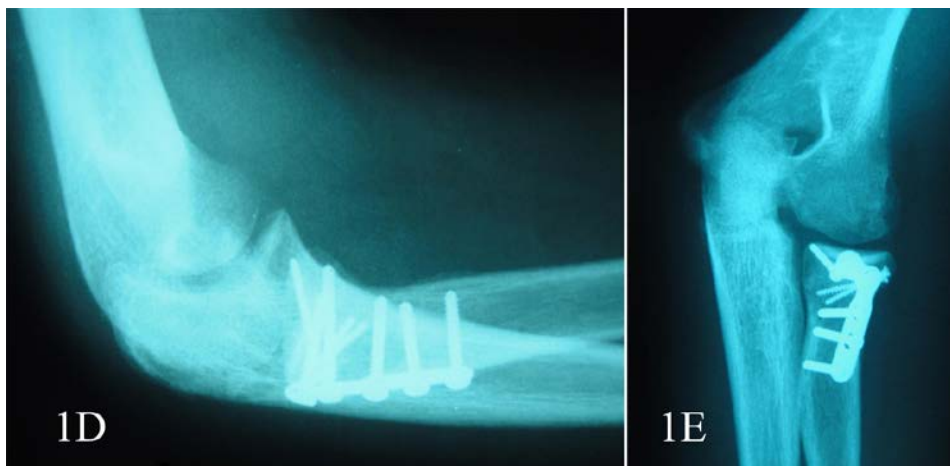
According to Regan and Morrey category, we had 9 type I and 10 type II coronoid fractures. Sixteen cases were fixed transosseously via nonabsorbable sutures, two with screws and one with a 2mm mini-fragment palate.

Based on the Mason classification, there were 3 type I, 7 type II and nine type III radial head fractures.

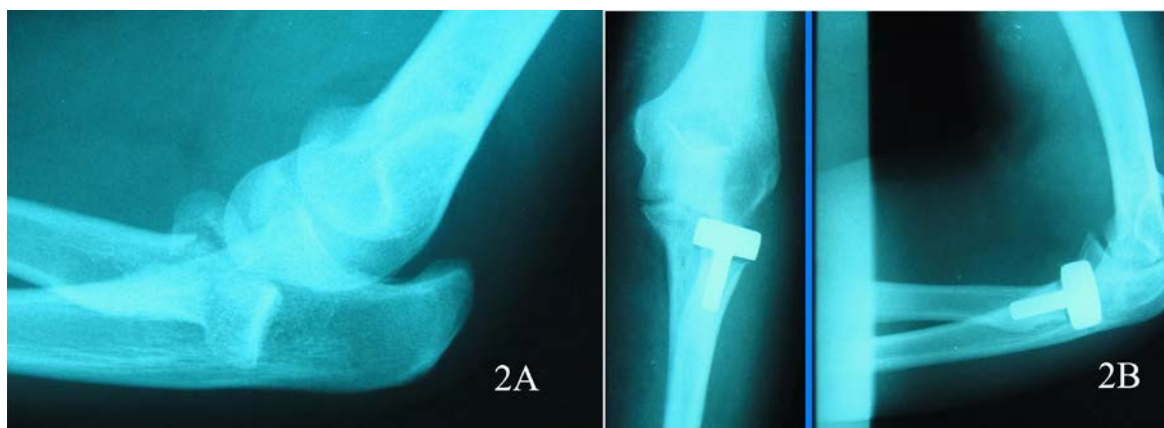In nine cases radial heads were fixed by mini-fragment 2 and 2.7mm T plates (Fig. 1. A, B, C, D, &E). The screw was applied to fix 4 radial head fractures as the only fixation device. Two small type I fractures were conservatively managed. They were neither resected nor reconstructed. One fracture was managed by arthroplasty (Fig. 2. A&B). The left three radial heads could not be restored and were resected. We could not perform arthroplasty in these cases due to unavailability of prosthesis at the operation time.



1. A &B. Anteroposterior and lateral radiography of radial head fracture in terrible triad.  
C. The same elbow CT scan.



1. D &E. The elbow after open reduction and internal fixation with mini plate.



2. A. The comminuted fracture of radial head in terrible triad. B. the radial head arthroplasty.

The mean flexion-extension arc of the elbow was  $102.63^\circ \pm 33.22^\circ$  ( $5^\circ$  to  $140^\circ$ ). The mean arc of pronation and supination were  $60.53^\circ \pm 14.32^\circ$  ( $40^\circ$ - $80^\circ$ ) and  $60^\circ \pm 13.72^\circ$  ( $30^\circ$ - $80^\circ$ ), respectively.

Union of all osseous structures was documented radiologically and concentric elbow joint restoration was achieved in all but one patient.

The mean MEPS postoperatively was  $87.11 \pm 12.05$  (55-100). Accordingly, 6 patients had excellent, 11 good, 1 fair and 1 poor results.

The average DASH score was  $17 \pm 13.83$ . Regarding the normalized DASH scores, 6 patients (31.5%) resumed better performance compared to 50% of the normal population. Nine had DASH scores less than one standard deviation away from the normal population and their function was better than 16% and worse than 50% that of the normal population. Function of the 3 patients was better than that of 5% and one worse than that of 99.5% of the normal population

### Discussion

Closed reduction of the elbow joint dislocation combined with radial head and coronoid process fractures is almost invariably disappointing (7-12).

Three components in close interaction stabilize the elbow joint including: osseous articulation (especially radial head), capsuloligamentous complex and musculotendinous units (12,13). Long-term stability

cannot be restored without reconstruction of these elements.

In the study by Ring et al (3) 5 out of 11 patients experienced re-dislocation after operative management, 3 experienced significant complications and the overall result of the management was rated as unsatisfactory.

Heim et al (4) noticed early onset arthrosis and residual instability in 8 of 11 patients with terrible triad injury. Joseffson et al (5) also reported that all of their patients with terrible triad (four in their series), who underwent radial head resection experienced re-dislocation.

Biomechanical knowledge about stabilizing elements of the elbow and mechanism of the injury has modified surgical protocols. Several studies demonstrated that radial head excision has been followed by posterior instability and recurrent posterolaterally rotatory instability especially when other stabilizing elements are injured (13-16). Moreover, it has been revealed that the radial head has a main role in conduction of force from the hand to the humerus, and resection of the radial head in cadaveric simulation diminishes the valgus load resistance (15,16).

In 3 cases, after reconstruction of coronoid process, LCL and soft tissue of the distal part of the humerus (despite resecting the radial heads) and stability of the elbow joint were obtained. Fortunately, all of these patients regained excellent performance based on MEPS results. Other studies also found that the resection of the radial head in the

presence of an intact anterior bundle of medial collateral ligament (MCL) has trivial effect on the elbow kinematics (17).

A fundamental role for coronoid process and the anterior capsule especially in type I and II coronoid fractures is presumed. Fern et al (18) in their study on cadavers showed that reconstruction of radial head and lateral collateral ligament would not prepare adequate stability if more than 50% of the coronoid process is fragmented and thus reconstruction of the coronoid for varus stability is essential. They also recommended that the type I and some type II coronoid fractures could be managed with only reconstruction of the lateral column structures (18). Nonetheless, some other researchers found minor fragmentation even more troublesome in terrible triad injury and emphasized on repairing small particles (3). In the current study, all coronoid fractures were repaired successfully, mostly transosseously with the application of nonabsorbable sutures. This method has been suggested in literature (3,6,19).

Besides bony structures, ligaments also play an important role in stabilizing the elbow joint. On special consideration in this setting is LCL, which encompasses three parts. These parts are in close interaction with each other and radial head provides rotatory stability of the elbow and thus residual insufficiency in this ligament leads to recurrent posterolateral rotatory instability (20).

The researchers, who reconstructed both bony structures and LCL complex as well as capsular ruptures, reported significantly better outcomes. In a series by Pugh et al (7), of 36 patients, 34 achieved concentric stability. They also reconstructed medial collateral ligaments in the presence of residual instability. They applied hinged external fixator when conventional repair yielded no sufficient joint stability. Eight of patients in this setting required reoperation (7).

In the current study, the stability of the elbow joint was restored in 18 patients without reconstruction of the MCL. The lateral

incision solely provided an appropriate view to reconstruct all elements in standard protocol. Furthermore, the elbow joint stability was attained without hinged external fixator and thus probable ensuing complications were avoided.

Based on the MEPS results, 89.4% of our operations was satisfactory and in association with Pugh et al (7) study (82%). The rate of reoperation in our study compared with similar studies was significantly low (7,8).

Our finding was comparable and perhaps more promising than other studies' that approached through a global incision for an extended view and used hinged fixator for restoration of concentric stability (21,22).

Despite the indomethacin was prescribed prophylactically in all cases, heterotopic ossification happened in two patients. This complication seems to be unproblematic by itself (7,21).

Our study limitations included small sample size and that two different surgeons operated the patients, which may have affected the results. Prospective study with long term follow up is recommended.

### Conclusion

Management of terrible triad seems demanding. The challenge exists in reconstruction of elbow joint stabilizers in one side and minimizing the surgical manipulation, invasive procedures to prevent further complications, and long term immobilization on the other side.

In our experience, lateral window via an isolated lateral incision provides an adequate view to access the vital elements of stability and could be considered as the first choice in the absence of ulnar nerve injury.

### References

1. Josefsson PO, Johnell O, Wendeberg B. Ligamentous injuries in dislocations of the elbow joint. *Clin Orthop.* 1987; 222:221–225.
2. Broberg MA, Morrey BF. Results of treatment of fracture dislocations of the elbow. *Clin Orthop.* 1987; 216:109–119.
3. Ring D, Jupiter JB, Zilberfarb J. Posterior dislo-

cation of the elbow with fractures of the radial head and coronoid. *J Bone Joint Surg [Am]*. 2002; 84:547-551.

4. Heim U. Combined fractures of the radius and the ulna at the elbow level in the adult: analysis of 120 cases after more than 1 year. *Rev Chir Orthop Reparatrice Appar Mot*. 1998; 84:142-153.

5. Josefsson PO, Gentz CF, Johnell O, Wendeberg B. Dislocations of the elbow and intraarticular fractures. *Clin Orthop*. 1989; 246:126-130.

6. O'Driscoll SW, Jupiter JB, Graham JW, King GJ, Hotchkiss RN, Morrey BF. The unstable elbow. *J Bone Joint Surg [Am]*. 2000; 82:724-238.

7. Pugh DM, Wild LM, Schemitsch EH, King GJ, McKee MD. Standard surgical protocol to treat elbow dislocations with radial head and coronoid fractures. *J Bone Joint Surg [Am]*. 2004; 86:1122-1130.

8. Egol KA, Immerman I, Paksima N, Tejwani N, Koval KJ. Fracture dislocation of the elbow functional outcome following treatment with a standardized protocol. *Bull NYU Hosp Jt Dis*. 2007; 65(4): 263-270

9. Regan W, Morrey B. Fractures of the coronoid process of the ulna. *J Bone Joint Surg [Am]*. 1989; 71:1348-1354.

10. Johnston GW. A follow-up of one hundred cases of fracture of the head of the radius with a review of the literature. *Ulster Med J*. 1962;31:51-56.

11. Pugh D, McKee MD. The "terrible triad" of the elbow. *Tech Hand Up Extrem Surg*. 2002; 6 (1): 21-29.

12. Asef M, Ilyas AM, Jupiter JB. The pathoanatomy of elbow fracture dislocations: A road map to treatment. *J Musculoskelet Med*. 2008; 25(2): 53-62.

13. Seijas R, Ares-Rodriguez O, Orellana A, Al-bareda D, Collado D, Llusa M. Terrible triad of the elbow. *J Orthop Surg*. 2009;17(3):335-339.

14. Hall JA, McKee MD. Posterolateral rotatory instability of the elbow following radial head resection. *J Bone Joint Surg [Am]*. 2005; 87:1571-1579.

15. Halls AA, Travill A. Transmission of pressures across the elbow joint. *Anat Rec*. 1964; 150:243-247.

16. Hotchkiss RN, Weiland AJ. Valgus stability of the elbow. *J Orthop Res*. 1987; 5:372-377.

17. Morrey BF, Tanaka S, An KN. Valgus stability of the elbow. A definition of primary and secondary constraints. *Clin Orthop*. 1991; 265:187-195.

18. Fern SE, Owen JR, Ordyna NJ, Wayne JS, Boardman ND. Complex varus elbow instability: a terrible triad model. *J Shoulder Elbow Surg*. 2009;18: 269-274.

19. Seijas R, Joshi N, Hernández A, Catalán JM, Flores X. Terrible triad of the elbow; role of the coronoid process: a case report. *J Orthop Surg*. 2005; 13(3): 296-299.

20. O'Driscoll SW, Morrey BF, Korinek S, An KN. Elbow subluxation and dislocation; a spectrum of instability. *Clin Orthop Relat Res*. 1992; 280:186-197.

21. Zeiders GJ, Patel MK. Management of unstable elbows following complex fracture-dislocations—the "terrible triad" injury. *J Bone Joint Surg [Am]*. 2008; 90(4): 75-84.

22. Cheung EV, O'Driscoll SW, Morrey BF. Complications of hinged external fixators of the elbow. *J Shoulder Elbow Surg*. 2008; 17:447-453.