



Diabetes mellitus may be a risk factor for sciatic nerve injury during total hip arthroplasty

*Mansour Abolghasemian¹, Behrooz Givechian², Kaveh Gharanizadeh³
Abbas Behgoo⁴, Mohammad Ali Enayatolloahi⁵, Mohammad Taghi Ghazavi⁶

Department of Orthopedic Surgery, Shafa Orthopedic Hospital, Iran University of Medical Sciences, Tehran, Iran.

Received: 35 Mar 2013 Revised: 17 Apr 2013 Accepted: 22 Apr 2013

Abstract

Background: Sciatic nerve palsy during hip arthroplasty can negatively affect the outcome of total hip arthroplasty (THA). Although no causes could be found in majority of cases some risk factors including leg lengthening, direct injury, damage of vascular supply have been reported. We aimed to investigate if diabetes mellitus (DM) increases the incidence of sciatic nerve palsy during THA.

Methods: In a retrospective review on 1528 primary total hip arthroplasty (1219 patients) 16 cases of post-operative sciatic nerve palsy were identified. They were matched to a group of 96 patients of the same sex and gender but with no sciatic nerve injury. The prevalence of DM and the amount of leg lengthening were compared between the two groups.

Results: The ratio of male to female was the same in both groups (69% female, 31% male). The mean age at the time of surgery was 47.3 years (range 33-62) and 49.2 years (range 32-64) for the groups with and without nerve palsy, respectively. The amount of limb lengthening resulted from surgery was not significantly different between the groups (18.5mm in for the study group with nerve palsy versus 17.6mm for the control groups, $p = 0.79$) Seven patients in the study group (44%) and 20 patients in the control group (21%) were found to have diabetes. The difference had a trend to be significant ($p = 0.06$).

Conclusion: Although the number of diabetic cases in both groups showed no significant difference, but larger ratio of patient with sciatic nerve palsy had diabetes (44% versus 21%). Further studies with larger population are needed to evaluate the role of diabetic mellitus on the sciatic nerve palsy after hip arthroplasty.

Keywords: Sciatic nerve injury, Hip arthroplasty, Diabetes mellitus.

Introduction

Total hip arthroplasty (THA) is generally very successful in relieving pain and restoring function in patients suffering from hip issues. However, some complications, including nerve injury, may impair the outcome. Sciatic nerve injury (SNI) is the most common nerve injury following THA. Peroneal branch is more commonly affected (1).

SNI has a reported rate of 1% to 7.5% after hip arthroplasty (2-4). While the highest risk is associated with developmental dysplasia of the hip (DDH) or revision surgery, primary THA for simple hip osteoarthritis carries a much less risk. Most series have reported rates of 1% to 3.5% (2, 5, 6). Several mechanisms have been reported causing sciatic nerve palsy; including traction injury due to leg lengthening, direct trauma by the instru-

1. (Corresponding author) MD., Assistant Professor of Orthopedic Surgery, Shafa Orthopedic Hospital, Iran University of Medical Sciences, Tehran, Iran. mn.abolghasemi@yahoo.com

2. MD., Resident of Orthopedic Surgery, Shafa Orthopedic Hospital, Iran University of Medical Sciences, Tehran, Iran. behrooz1725@yahoo.com

3. MD., Assistant Professor of Orthopedic Surgery, Shafa Orthopedic Hospital, Iran University of Medical Sciences, Tehran, Iran. kavehgharani@gmail.com

4. MD., Assistant Professor of Orthopedic Surgery, Shafa Orthopedic Hospital, Iran University of Medical Sciences, Tehran, Iran. sabehgoo@yahoo.com

5. MD., Assistant Professor of Orthopedic Surgery, Shafa Orthopedic Hospital, Iran University of Medical Sciences, Tehran, Iran. maenayatollahi@gmail.com

6. MD., Assistant Professor of Orthopedic Surgery, Shafa Orthopedic Hospital, Iran University of Medical Sciences, Tehran, Iran. ghazavi@yahoo.com

ments, hematoma formation, thermal injury by cement and ischemia (5, 7). Tractional injury has shown to have the worst prognosis (2).

Despite all known risk factors associated with higher incidence of sciatic nerve palsy, the cause cannot be identified in a large number of patients (8). Diabetes mellitus (DM) is a condition that causes ischemia and neuropathy (9). The aim of our study was to investigate if DM could increase the risk of sciatic nerve palsy after hip arthroplasty.

Methods

The medical charts of all primary hip arthroplasties performed in Shafa Orthopedic Hospital during the last 28 years were reviewed. We searched for any neurologic complication after surgery. The charts were specifically assessed regarding the neurologic condition of the patients before the surgery. The case group included patients with partial or complete sciatic nerve palsy discovered immediately after the surgery. Sciatic nerve injury was defined as an objective defect in the motor function of peroneal and/or tibial nerves as judged by the surgeon. Patients with pre-operative SNI and those with incomplete lab data on glycemic status were excluded.

Each case of post-op nerve palsy was matched to 6 cases of primary THA without SNI regarding gender and age. This group constituted our control group. Both groups were then investigated for affection by DM at the time of surgery. DM was defined as fasting blood sugar greater than 126mg/dl (10), or administration of hypoglycemic agents by the physician.

The amount of leg lengthening caused by surgery was also recorded. The pre- and post-operative pelvic radiographs of the patients of both groups were compared to measure the amount of leg length change. The inter-teardrop line was used as the reference and the distances were calibrated based on the known diameter of the prosthetic femoral head (Fig. 1). Lengthening was signified by plus values and shortening was signified by minus values.

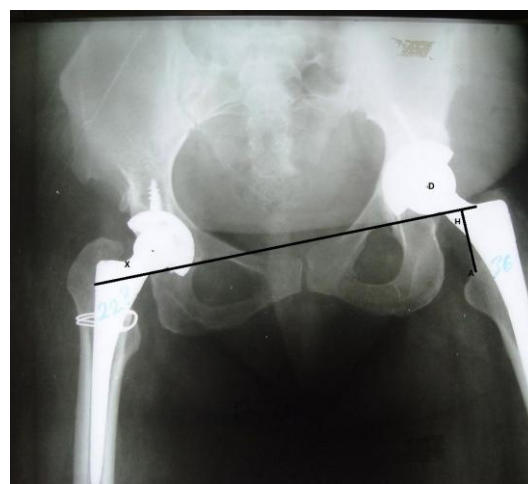


Fig 1. Anteroposterior pelvic radiograph of a patient after bilateral hip arthroplasty showing measurement of the leg length relative to the interteardrop line. Line 'x' represents the inter-teardrop line and line 'AH' is the perpendicular from the highest point of the lesser trochanter. Measurements are calibrated using the known diameter of the prosthetic femoral head (D) as reference. The distance 'AH' will be compared to the corresponding measurement on the preoperative radiograph to calculate the amount of length change.

Statistical analysis

The statistical difference of the patients' ages and the amount of lengthening were analyzed using t test. The Fisher's exact test was used to compare the rate of DM in the two groups.

Results

From 1985 to 2013, 1219 patients underwent primary THA (1528 hips). Twenty nerve palsies were documented (1.18% incidence) including 3 complete sciatic, 15 peroneal and 2 femoral nerve injuries. Four cases were excluded including 2 femoral nerve palsies, 1 sciatic nerve palsy because of a pre-operative history of peroneal nerve palsy following acetabular fracture, and 1 peroneal nerve palsy after simultaneous hip arthroplasty and IM nailing of tibia. Therefore, a total of 16 cases of SNI (2 complete, 14 partial) were included to the study group. There were 11 women and 5 men with an average age of 47.3 years (range 33-62).

A total of 96 patients (66 women, 30 men)

were included into the control group with an average age of 49.2 years (range 32-64) which was not significantly different from the age of the study group ($p = 0.36$).

There were 7 diabetics in the study group (46%) and 20 in the control group (21%). This difference was not significant but had a trend toward significance ($p = 0.06$). The odds ratio was calculated to be 2.95 (95% CI, 0.9801 - 8.9124).

The average increase in the limb length was 18.5mm (range -5 to +52) for the study group, and 17.6mm (range -2 to +56) for the control group ($p = 0.79$) which showed no significant difference.

Discussion

Although the incidence of SNI following hip arthroplasty is higher in revision arthroplasties, primary THA may be complicated by SNI in 0.7 to 3.5% (2). It occurs more often in high riding DDH cases, leg lengthening of more than 4 centimeters and in women (2, 7). There are still many cases of SNI with unexplained reason (11), thus, some unknown risk factors must be involved.

Neuropathy and vasculopathy is a well-known outcome of long standing DM (12). It is still not clear if it increases the risk of nerve damage during surgical procedures. The association of nerve injury following hip and knee arthroplasty or arthroscopy with DM has been investigated previously (13). In a study of 14000 patients, Yacub et al. (13) reported a two-fold increase in the risk of nerve injury after THA and a 10-fold increase after total knee arthroplasty (TKA) in diabetic patients. The difference was statistically significant for TKA. However, their number of nerve injuries was very small (only 10) and other risk factors were not controlled between the groups.

A few assumptions can be made on how DM may predispose the patients to SNI following THA. The metabolically diseased nerve may be more susceptible to any new injury, direct, thermal or tractional. Also, the vasculopathy caused by DM leads to ischemia of tissues, including nerves (14). Nerve

ischemia is potentiated by traction and hematoma formation, or inflammation caused by direct or thermal injury.

Our study had some limitations. Due to retrospective data collection, we might have missed some nerve palsies with subtle clinical manifestations. Previous studies using somatosensory evoked potential (SSEP) have shown much more prevalence of sub-clinical SNI (15). However, only clinically detectable nerve injuries could compromise the outcome of the THA. We considered DM as a "yes or no" disease, ignoring the fact that the severity and duration of the disease, and the quality of medical control could play important roles in the risk of nerve damage. Unfortunately, quantification of this variety of factors was not possible with the available number of cases.

In the present study, only patients with primary THA were investigated in order to exclude the confounding effect of revision surgery. Gender and age as possible confounders were also addressed by selecting a control group of matched cases. Although some studies have questioned the association between the amount of limb lengthening and SNI (2, 16), we addressed this issue by comparing the amount of lengthening in the two groups, where there was no significant difference in the amount of limb lengthening.

Conclusion

Diabetes mellitus may be a risk factor for sciatic nerve injury during total hip arthroplasty. Our study showed no significant increase in the rate of SNI after THR in diabetic patients, nevertheless it showed a considerable trend toward significance ($p = 0.06$). Prospective multi-center studies are needed to reach more conclusive results in this regard.

References

1. Schoellner C, Schoellner D. Nerve injuries in total hip arthroplasty--prophylactic strategies--quality assurance and risk management in orthopaedic and trauma surgery. *Z Orthop Ihre Grenzgeb.* 2003

;141(3):289-295.

2. Schmalzried TP, Amstutz HC, Dorey FJ. Nerve palsy associated with total hip replacement. Risk factors and prognosis. *J Bone Joint Surg [Am]*. 1991;73(7):1074-1080.

3. Amstutz HC, Ma SM, Jinnah RH, Mai L. Revision of aseptic loose total hip arthroplasties. *Clinical Orthopedics*. 1982;170:21-33.

4. Schmalzried TP, Noordin S, Amstutz HC. Update on nerve palsy associated with total hip replacement. *Clin Orthop Relat Res*. 1997; 344:188-206.

5. Nercessian OA, Macaulay W, Stinchfield FE. Peripheral neuropathies following total hip arthroplasty. *J Arthroplasty*. 1994;9(6):645-651.

6. DeHart MM, Riley LH Jr. Nerve injuries in total hip arthroplasty. *J Am Acad Orthop Surg*. 1999;7(2):101-111.

7. Edwards BN, Tullos HS, Noble PC. Contributory factors and etiology of sciatic nerve palsy in total hip arthroplasty. *Clin Orthop Relat Res*. 1987;218:136-141.

8. Pekkarinen J, Alho A, Puusa A, Paavilainen T. Recovery of sciatic nerve injuries in association with total hip arthroplasty in 27 patients. *J Arthroplasty*. 1999;14(3):305-311.

9. Thomas PK. Diabetic neuropathy: mechanisms

and future treatment options. *J Neurol Neurosurg Psychiatry*. 1999;67(3):277-279.

10. Diagnosis and classification of diabetes mellitus. *Diabetes Care*. 2009 ;32 Suppl 1:S62-7.

11. Hurd JL, Potter HG, Dua V, Ranawat CS. Sciatic nerve palsy after primary total hip arthroplasty: a new perspective. *J Arthroplasty*. 2006;21(6):796-802.

12. Raff MC, Asbury AK. Ischemic mononeuropathy and mononeuropathy multiplex in diabetes mellitus. *N Engl J Med*. 1968 4; 279(1):17-21.

13. Yacub JN, Rice JB, Dillingham TR. Nerve injury in patients after hip and knee arthroplasties and knee arthroscopy. *Am J Phys Med Rehabil*. 2009; 88(8):635-641; quiz 42-4, 91.

14. Raff MC, Sangalang V, Asbury AK. Ischemic mononeuropathy multiplex associated with diabetes mellitus. *Arch Neurol*. 1968;18(5):487-499.

15. Nercessian OA, Gonzalez EG, Stinchfield FE. The use of somatosensory evoked potential during revision or reoperation for total hip arthroplasty. *Clin Orthop Relat Res*. 1989 243:138-142.

16. Egli S, Hankemayer S, Muller ME. Nerve palsy after leg lengthening in total replacement arthroplasty for developmental dysplasia of the hip. *J Bone Joint Surg [Br]*. 1999 ;81(5):843-845.