

# Focal Fibrocartilaginous Dysplasia in Distal Radius

Farid Najd Mazhar<sup>1,\*</sup>; Hooman Shariatzadeh<sup>1</sup>; Ali Dianat<sup>1</sup>; Davod Jafari<sup>1</sup>

<sup>1</sup>Bone and Joint Reconstruction Research Center, Shafa Orthopedic Hospital, Iran University of Medical Sciences, Tehran, IR Iran

\*Corresponding author: Farid Najd Mazhar, Bone and Joint Reconstruction Research Center, Shafa Orthopedic Hospital, Iran University of Medical Sciences, Tehran, IR Iran. Tel: +98-9121463048, Fax: +98-2133542022, E-mail: fnajdmazhar@yahoo.com

Received: March 12, 2015; Revised: April 22, 2015; Accepted: April 30, 2015

**Background:** Focal fibrocartilaginous dysplasia (FFCD) is a benign lesion and has been reported as a cause of tibia vara in proximal tibia and distal of the femur. It is rare in upper extremity and few cases have been reported in the ulna and radius.

**Objectives:** The aim of the study was to review and report the clinical course, radiographic presentation and treatment results of three cases of FFCD in the distal radius.

**Patients and Methods:** We reviewed the medical records, imaging files, intraoperative anatomical findings and treatment complications of three cases of FFCD in distal radius. All patients underwent tethering fibrotic band resection with lengthening of extensor tendons in one case and distal radius corrective osteotomy in another one.

**Results:** All three patients were male with a mean age of 21.3 (11 - 36) months. The mean follow-up period was 28 months. Clinical and radiographic examinations in patients who underwent tethering band resection without osteotomy showed considerable remodeling. Nonunion, multiple surgeries and deformity were the complications in patient who received osteotomy as a part of treatment.

**Conclusions:** The natural history of distal radius FFCD is not clear. Until receiving enough evidences regarding the natural history of this rare lesion, we can recommend the least invasive treatment for the lesion, which is the resection of the fibrous band.

**Keywords:** Complication; Distal; Radius; Treatment; Focal Fibrocartilaginous Dysplasia

## 1. Background

Focal fibrocartilaginous dysplasia (FFCD) is an uncommon benign lesion described by Bell et al. for the first time in 1985 as a bone deforming pathology (1). It involves both lower and upper extremities, but most reported cases were located in the proximal tibia and distal femur (2). In the lower extremity, it has been reported as a cause of tibia vara. Being rare in the upper extremity, few cases of FFCD have been reported in this region (3, 4). Little is known about the natural history of this lesion (4). Its treatment depends on the location, duration and severity of symptoms. Although FFCD can resolve spontaneously in mild cases, surgical treatment may be necessary as the disease becomes more advanced and the deformity more severe (4).

## 2. Objectives

We described the clinical course and radiographic presentation, especially details of the intraoperative anatomical findings, in three cases of FFCD in the distal radius.

## 3. Patients and Methods

The committee of ethics at our institution approved the study. We obtained an informed written consent from

parents of our patients for print and electronic publication of the collected data. Physical examination, routine laboratory tests and plain radiography were performed for all patients. MRI and CT scan were taken for two of them. Surgical treatment was performed for all of them using dorsoradial approach, but the type of operation was different according to the preference of the attending surgeon. Resection of the tethering band was performed for all of our patients alongside of corrective osteotomy in one case and wrist extensors lengthening for other one. This difference in treatment was mainly due to little information about the natural history and treatment options for FFCD in the distal radius. The intraoperative findings were recorded in details. We reviewed the clinical records, imaging files, photographs and histological examination reports for these three cases of FFCD of the distal radius.

## 4. Results

All of our patients were male. They were healthy otherwise. The family history was negative for the similar condition. The deformity had atraumatic origin. The appearance of the upper limb was very similar to the radial club hand. The wrist deviated to the radial and volar side.

In all cases, the deformity started during the first year of life and worsened afterward. Wrist and upper extremity radiographs revealed that the radius was shorter than ulnar bone. In anteroposterior radiograph, there was a slope in distal articular surface of the radius from ulnar to radial side. A triangular radiolucent area was located at the lateral half of distal metaphyseal area of the radius surrounded by sclerotic rim. In lateral view, there was a focal volar angulation at the deforming area with V shape apex dorsal indentation. Imaging modalities of MRI and CT scan (performed for two of our patients) did not help in diagnosis and treatment. All routine tests including CBC, ESR and CRP had normal findings in our patients. We did dorsoradial approach for all three cases and we noticed that the extensor tendons in radial side were short and the extensor carpi radialis longus and brevis had subluxation to the volar side. The median nerve in volar side was very close to the concave side of the radius and we found it very susceptible to iatrogenic damage in surgical approach because of the altered anatomy. This was true for brachioradialis muscle tendon and radial artery and nerve. Distal radius was distorted three dimensionally by traction force of tethering band. A thin fascia had covered the pathologic tissue in all cases. An extra-osseous tethering band originated proximally from radial half of volar distal metaphysis of the radius and terminated to its epiphysis in distal. There was no insertion to the physis. It was taut rectangular fibrous band with approximate dimensions of  $15 \times 10 \times 3$  mm. The pathologic examination revealed that the specimens consisted of fibrous tissue with mild hypercellularity containing areas of hyaline cartilage and admixed with pieces of collagenous tissue. After resection of the band, a V shape sclerotic and dense indentation remained in volar side of the distal radius.

#### 4.1. Case 1

We visited a 17-month old boy in the hand clinic because of his left wrist deformity since several months ago (Figure 1).

The appearance of the upper limb was very similar to the radial club hand with its volar and radial deviation. We considered atraumatic origin for the deformity because the history of trauma was negative. The deformity started during the first four months of life and worsened afterward. Passive supination was 60 degrees and pronation was 80 degrees, flexion and extension were 50 and 40 degrees, respectively. All routine lab tests had normal results. As we described in previous section, radiography showed shorter radius than the ulnar bone and there was a slope in distal articular surface of the radius from ulnar to radial side. A triangular radiolucent area surrounded by sclerotic rim was located at the lateral distal metaphyseal area of the radius. In lateral view, there was a focal volar angulation at the deforming area with sharp apex dorsal angulation (Figure 2). MRI and CT scan did not provided more information

in diagnosis of the tethering band. After doing dorsoradial approach, we noticed that the extensor tendons in radial side were short and the median nerve was very close to the concave side of the radius. The tethering band had connected the metaphysis to the epiphysis and distorted the distal radius three dimensionally by its traction force.

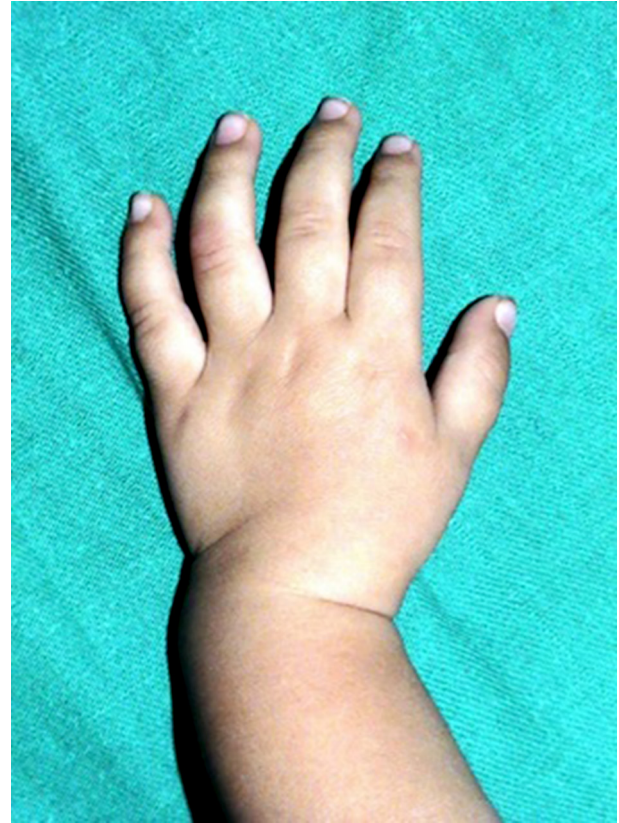

Figure 1. Clinical Appearance of Wrist, Case No. 1

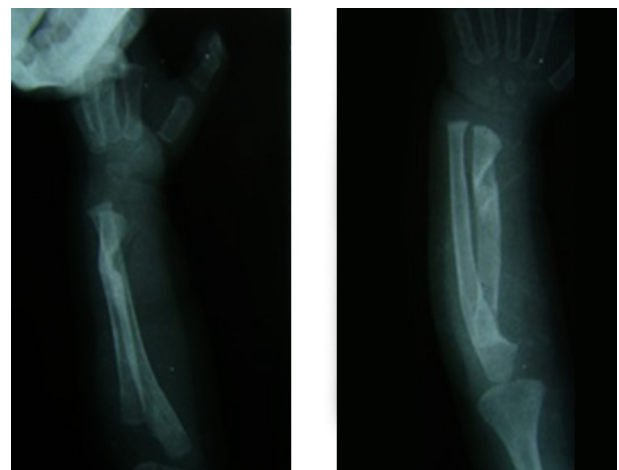


Figure 2. Radiographic Appearance of FFCD in Distal Radius, Case No. 1

We did lengthening for the short extensor carpi radialis longus and brevis and resected the dens fibrous tissue in the deformed area and sent it to the pathologic examination. Histology study of the resected tissue demonstrated fibrous tissue containing areas of hyaline cartilage. The diagnosis was FFCD. We applied long arm splint for six weeks. Clinical appearance and plain radiography after 24 months showed considerable correction of the deformity (Figures 3 and 4).

#### 4.2. Case 2

A 3-year-old boy presented to the hand clinic due to the right wrist deformity since two years ago. The wrist was deviated to the radial and volar side (Figure 5).

The deformity started during the first six months of life and worsened afterward. Passive supination was 70 degrees and pronation was 80 degrees, flexion and extension were 40 and 30 degrees, respectively. Again the radiography had the characteristic triangular radiolucent indentation, which was located at the lateral half of distal metaphyseal area of the radius (Figure 6).

During the approach in this case, the responsible surgeon decided to do corrective osteotomy in addition to tethering band resection. The origin of the extra-osseous tethering band was lateral side of volar distal metaphysis of the radius in proximal and it terminated in distal of its epiphysis (Figure 7).

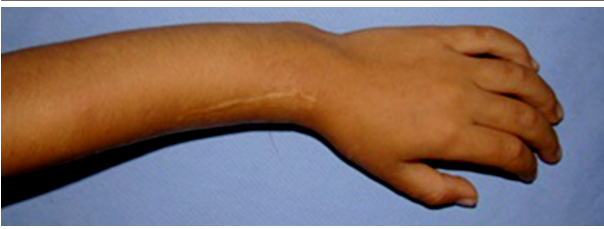

Figure 3. Clinical Appearance of Wrist After 24 Months, Case No. 1

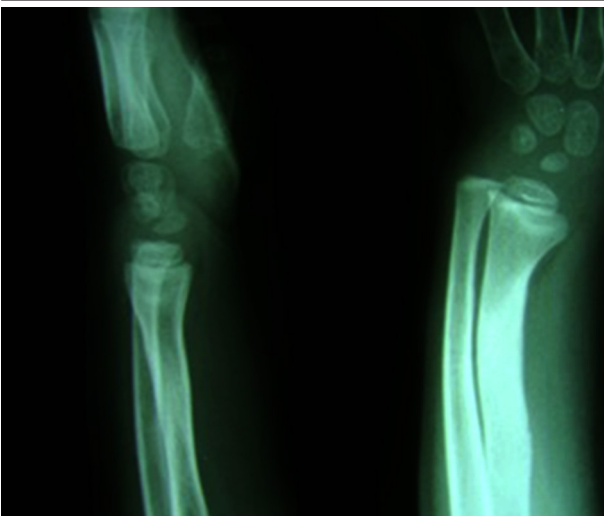


Figure 4. Radiography of the Wrist After 24 Months, Case No. 1

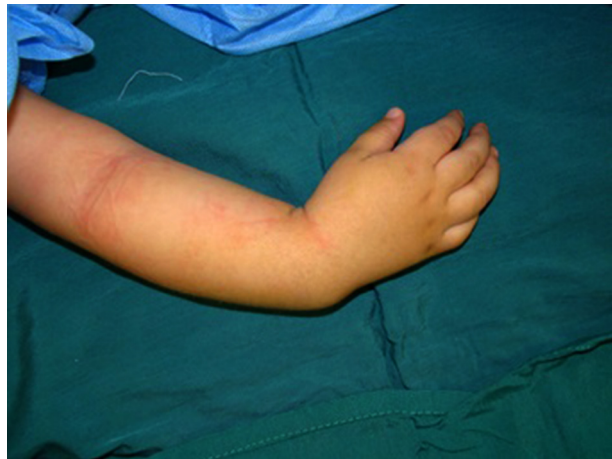

Figure 5. Clinical Appearance of Wrist in FFCD, It Is Similar to Radial Club Hand, Case No. 2

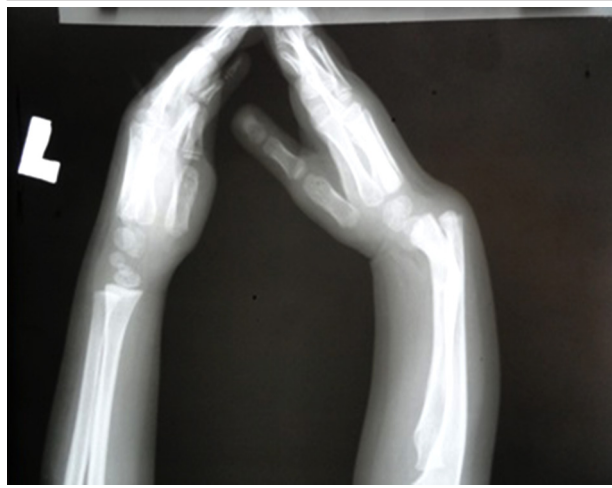

Figure 6. Radiography of Both Wrist, Case No. 2

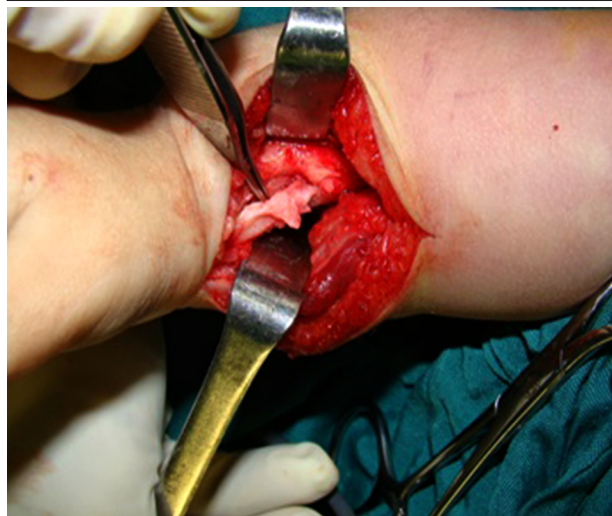


Figure 7. Appearance, Origin and Insertion of Pathologic Band, Case No. 2



We resected the tethering band. It was taut rectangular fibrous band with robbery consistency (Figure 8). We did osteotomy through the foot print of tethering band and fixed it by two pins, then we immobilized the upper limb in long arm cast for six weeks. Histology study of the resected tissue demonstrated FFCD.

After cast and pin removal, it was apparent that the osteotomy had failed to unite. Immobilization in long arm cast did not end to union. Open reduction, plating and tri-cortical iliac crest bone graft ended to union finally (Figure 9).

Two years after surgery, radius was deformed and there was an apex dorsal angulation at the distal end of the plate and there was a need for another osteotomy (Figure 10).

#### 4.3. Case 3

We admitted an 11-month-old boy to our hospital due to the right wrist deformity. The wrist deviated to the volar radial direction similar to the previous two cases (Figure 11).

The deformity started during the first four months of life and worsened afterward. Passive range of motion was approximately similar in both wrists. Past medical history was negative for trauma or similar disease. Radiography of the involved wrist showed the short radius with distorted distal metaphysis along with the triangular radiolucent indentation in the distal radius (Figure 12).

In this case, we did not perform any other imaging modalities like MRI or CT scan. Routine laboratory tests including CBC, ESR and CRP had normal findings. Like the previous cases, our preferred approach was dorsoradial. Similar to the previous two cases, the radius was distorted three dimensionally due to the traction force of the tethering band. The extensor tendons of the radial side were short and had radial subluxation. There was a thin fascia covering the pathologic tissue (Figure 13).

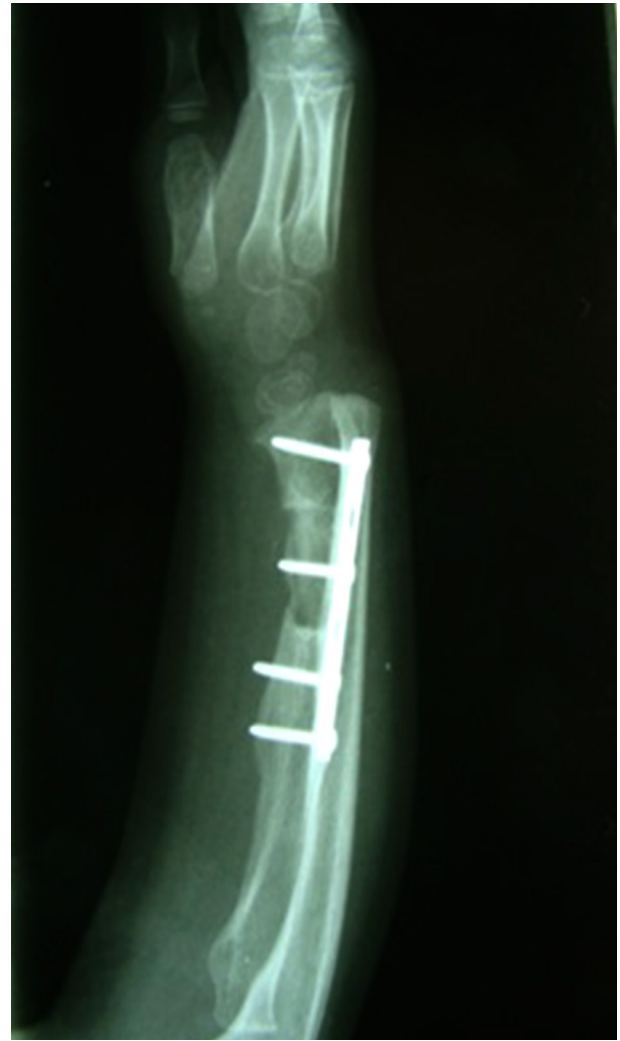

Figure 9. Union in Osteotomy Site After Three Cortical Bone Grafts and Internal Fixation With Plate, Case No. 2

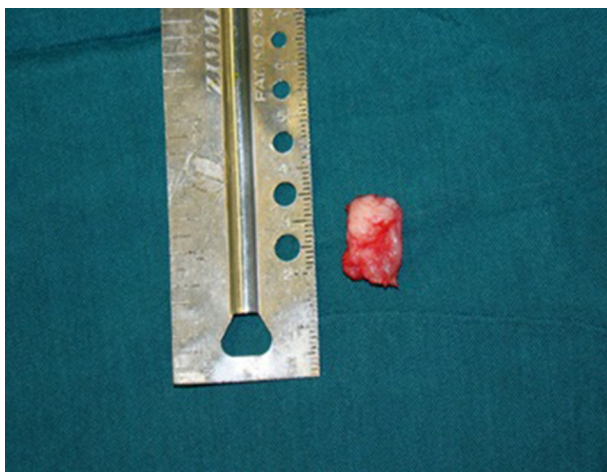


Figure 8. Tethering Band After Resection, Case No. 2

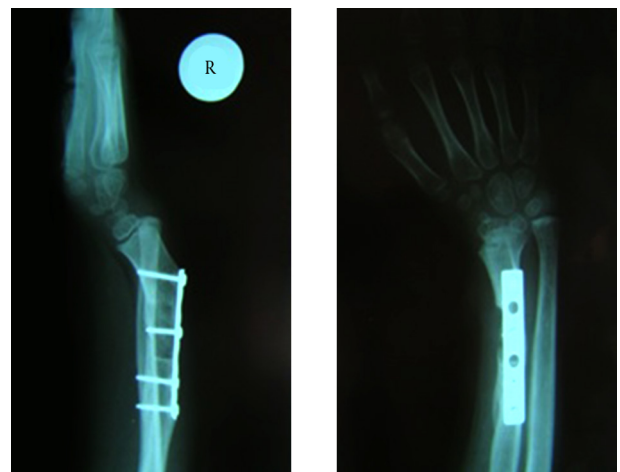


Figure 10. Deformity of Distal Radius After 24 Months, Case No. 2

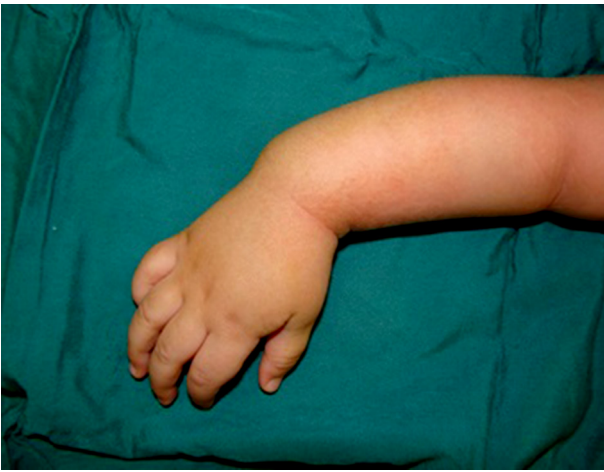

Figure 11. Deformity in Case No. 3

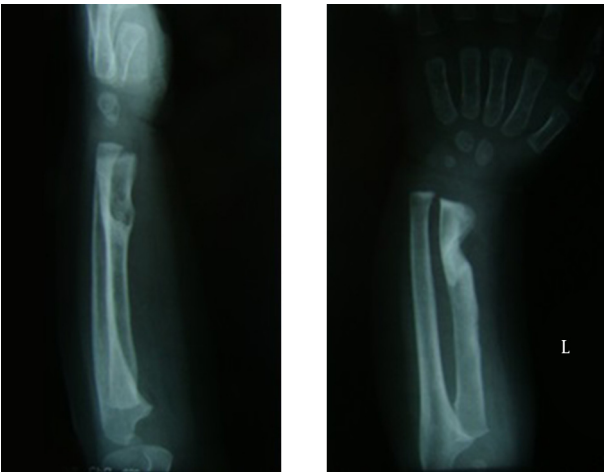


Figure 12. Radiography of the Wrist Showing the Typical Appearance, Case No. 3

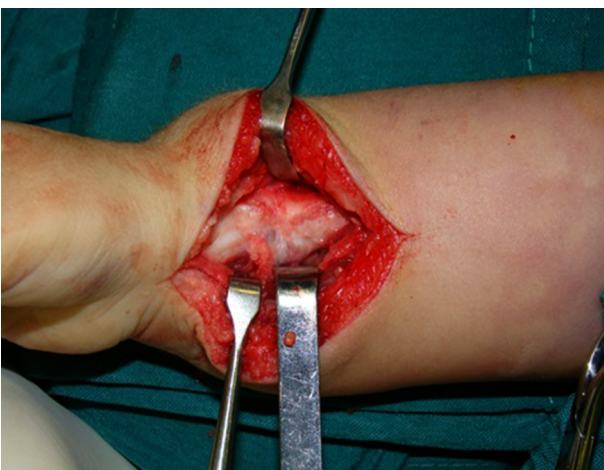

Figure 13. Thin Fascia Covering the Tethering Band, Case No. 3

We resected the tethering band and again a V shape sclerotic and dense indentation remained in place (Figure 14).

Histology study of the resected tissue demonstrated FFCD. We did not perform osteotomy or tendons lengthening and decided to observe the patient for spontaneous correction and remodeling of the deformity. After 12 months, clinical appearance and radiography of the wrist became near normal showing tremendous correction of the deformity (Figure 15).

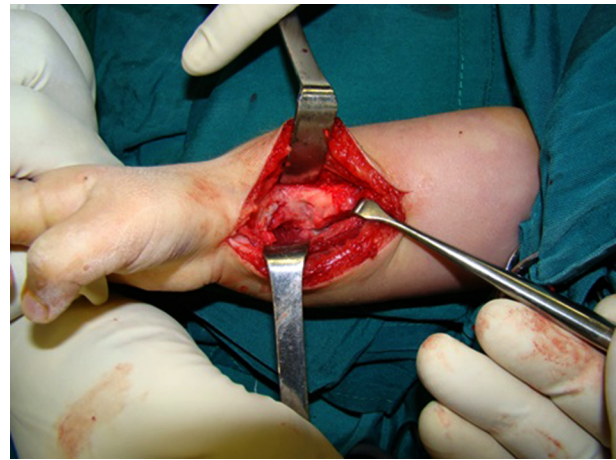

Figure 14. V Shape Sclerotic Indentation After Resection of Band, Case No. 3

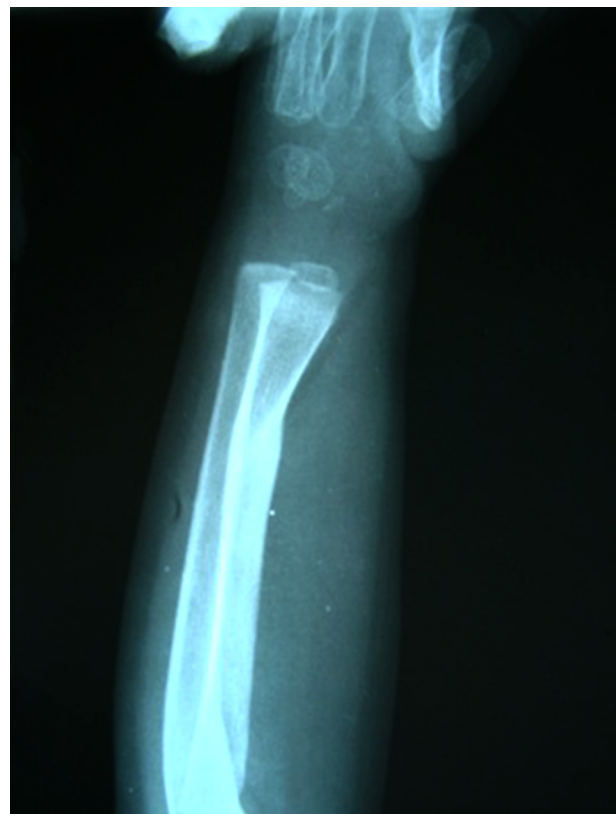

Figure 15. Remodeling After Tethering Band Resection, Case No. 3

## 5. Discussion

FFCD is a benign condition first described in 1985 as a cause of tibia vara (1) with an unknown cause.

Jouve et al. (1) proposed that the lesion is as a bony anchor preventing natural sliding of the periosteum during growth, so they called it "fibrous periosteal inclusion". The anchor or tethering band comprises areas of dense fibrous tissue, fibrocartilage and sclerotic bone (1).

The presence of abnormal and pathologic fibrous tissue has been reported in the radial and ulnar club hand, but the functional importance of this fibrous anlage has not been established in the development of these deformities (5, 6). Resection of this fibrous anlage improved the appearance in these deformities in some instances (5, 6).

The histology of focal fibrocartilaginous dysplasia in our patients was fibrous tissue with mild hypercellularity and areas of hyaline cartilage, which was similar to previously reported cases (7).

To the best of our knowledge, the reported cases of FFCD in the upper extremity were in diaphyseal area of long bones mostly in ulna, which can result in angulation and radial head dislocation (1, 8). In our cases with FFCD of distal radius, the clinical appearance of the involved wrists were very similar to radial club hand.

Distal radius FFCD has a very typical presentation on plain radiography, which is very helpful in diagnosis of the lesion preoperatively, so we believe that there is no need for other imaging modalities like MRI or CT scan.

The natural history of FFCD is well recognized in the lower extremity and there are guidelines and recommendations for its treatment around the knee (1). In mild deformities, spontaneous correction is more likely and in most cases there is no need for intervention and osteotomy (8-10). Choi et al. (11) reported that about 45% of the cases of tibial FFCD may have spontaneous improvement of the deformity without surgical treatment. They stated that some surgically treated cases of FFCD in the lower extremity might have resolution on their own despite observation without surgical correction (11).

The natural history of FFCD is different in the upper extremity (3). Eren et al. (12) reported significant shortening in two cases of the FFCD in the proximal humerus who had no surgical intervention during the course of disease. They stated that FFCD of the proximal humerus may not be a benign condition compared with that of the long bones of the lower extremity. They concluded that, when the lesion is located close to the physis of the proximal humerus, it can result in significant limb-length discrepancy in the affected limb (3, 12). However, spontaneous correction and remodeling in ulnar bone have been reported (3, 4, 13). It has been proposed to close observation of patients for six months to evaluate the behavior of the lesion in ulnar bone with special attention to the radiocapitellar joint for any sign of dislocation (13).

According to Jouve et al. (1), curettage and even osteotomy have been proposed for the treatment of FFCD

depending on the site, duration and response to the conservative treatments.

There was no consensus regarding the method of choice among the responsible surgeons for our cases due to lack of experience with this disease in distal of the radius. Each of our patients received different method of treatment, so our institution would have a unique chance to compare the results of different methods of treatment in long term follow-up.

One of us (FNM) had opportunity to take part in all three operations, so the team was able to coordinate and compare the intraoperative findings.

The common step in the treatment of our patients was resection of taut fibrous tethering band. One of our cases (case No. 2) who underwent osteotomy became complicated and indeed would probably need more intervention to overcome the angulation. The third case had only resection of fibrous band, which was the simplest operation. This case experienced remodeling of the deformity after several months. Until receiving enough evidences regarding the natural history of distal radius FFCD, we can recommend the least invasive treatment for the lesion, which is the resection of the fibrous band.

## Authors' Contributions

Study concept, design, drafting the manuscript, and critical revision of the manuscript: Farid Najd Mazhar, Hooman Shariatzadeh, Dawood Jafari, and Ali Dianat; Analysis and interpretation of data: Farid Najd Mazhar, Davod Jafari; and Study supervision: Farid Najd Mazhar.

## References

- Jouve JL, Kohler R, Mubarak SJ, Nelson SC, Dohin B, Bollini G. Focal fibrocartilaginous dysplasia ("fibrous periosteal inclusion"): an additional series of eleven cases and literature review. *J Pediatr Orthop*. 2007;27(1):75-84.
- Albinana J, Cuervo M, Certucha JA, Gonzalez-Mediero I, Abril JC. Five Additional Cases of Local Fibrocartilaginous Dysplasia. *J Pediatr Orthop*. 1997;6(1):52-5.
- Lincoln TL, Birch JG. Focal Fibrocartilaginous Dysplasia in the Upper Extremity. *J Pediatr Orthop*. 1997;17(4):528-32.
- Smith NC, Carter PR, Ezaki M. Focal Fibrocartilaginous Dysplasia in the Upper Limb. *J Pediatr Orthop*. 2004;24(6):700-5.
- Manske PR, McCarroll HR, Swanson K. Centralization of the radial club hand: An ulnar surgical approach. *J Hand Surg*. 1981;6(5):423-33.
- Buck-Gramcko D. Congenital malformations of the hand: indications, operative treatment and results. Erik Moberg Lecture 1975. *Scand J Plast Reconstr Surg*. 1975;9(3):190-8.
- Kim C, Choi IH, Cho TJ, Chung CY, Chi JG. The histological spectrum of subperiosteal fibrocartilaginous pseudotumor of long bone (focal fibrocartilaginous dysplasia). *Pathol Int*. 1999;49(11):1000-6.
- Bell SN, Campbell PE, Cole WG, Menelaus MB. Tibia vara caused by focal fibrocartilaginous dysplasia. Three case reports. *J Bone Joint Surg Br*. 1985;67(5):780-4.
- Zayer M. Tibia vara in focal fibrocartilaginous dysplasia. *Acta Orthopaedica*. 1992;63(3):353-5.
- Khanna G, Sundaram M, El-Khoury GY, Merkel K. Focal fibrocartilaginous dysplasia: curettage as an alternative to conservative management or more radical surgery. *Skeletal Radiol*. 2001;30(7):418-21.



11. Choi H, Kim C, Cho TJ, Chung C, Song K, Hwang J, et al. Focal fibrocartilaginous dysplasia of long bones: report of eight additional cases and literature review. *J Pediatr Orthop.* 2000;**20**(4):421-7.
12. Eren A, Cakar M, Erol B, Ozkurt A, Guven M. Focal fibrocartilaginous dysplasia in the humerus. *J Pediatr Orthop B.* 2006;**15**(6):449-52.
13. Gottschalk HP, Light TR, Smith P. Focal fibrocartilaginous dysplasia in the ulna: report on 3 cases. *J Hand Surg Am.* 2012;**37**(11):2300-3.