



## Evaluation of distal femoral rotational alignment according to transepicondylar axis and Whiteside's line: a study in Iranian population

Mahmoud Jabalameli<sup>1</sup>, Mohammad Rahbar<sup>2</sup>, Abolfazl Bagherifard<sup>3</sup>, Hosseinali Hadi<sup>4</sup>,  
\*Amin Moradi<sup>5</sup>, Mehran Radi<sup>6</sup>, Tahmineh Mokhtari<sup>7</sup>

Department of Knee Surgery, Shafa Orthopedic Hospital, Iran University of Medical Sciences, Tehran, Iran.

Received: 31 Mar 2013 Revised: 10 May 2013 Accepted: 12 Jun 2013

### Abstract

**Background:** Rotational positioning of femoral component is a critical aspect of total knee arthroplasty and evaluation of the landmarks for rotation of distal femur is a challenge. Most orthopedic surgeons prefer to use more available posterior femoral condyle axis, but other landmarks especially surgical transepicondylar axis may be more valid. Preoperative CT scan can help to evaluate these landmarks more accurately. The purpose of our study was to ascertain the relationships among the described axes guiding distal femur rotational alignment in CT scan of Iranian healthy population and the effects of age and gender on these relationships.

**Methods:** Ninety cases aged between 16 and 75 years presenting with acute tibial plateau or patella fracture were included in this study. The rotation of distal femur was evaluated using the single axial CT image through the femoral epicondyles. Four lines were drawn digitally in this view: anatomical & surgical transepicondylar axes, posterior condylar axis and Whiteside's anteroposterior line. Then we measured the angles among these lines and analyzed the data and evaluated the relationship between them.

**Results:** In 82 patients, mean angle between anatomical transepicondylar axis and posterior condylar axis and between surgical transepicondylar axis and posterior condylar axis were  $5.68^{\circ} \pm 1.89^{\circ}$  and  $1.9^{\circ} \pm 1.85^{\circ}$  respectively. Mean angle between Whiteside's anteroposterior line and posterior condylar axis was  $3.89^{\circ} \pm 1.64^{\circ}$ . There were significant differences between the two genders in these relationships. No significant correlation between patients' age and angles of distal femur was detected. There was a good correlation between anatomical and surgical axes situations, as anatomical transepicondylar axis was in  $3.78^{\circ}$  externally rotation related to surgical transepicondylar axis.

**Conclusion:** Preoperative CT scan can help to determine rotational landmarks of distal femur more accurately. If one of the reference axes could not be determined, we can use other reference axes because of good correlations between these landmarks.

**Keywords:** Distal femur, Rotational alignment, Transepicondylar axis, Whiteside's line.

1. MD., Associate Professor of Orthopedic Surgery, Shafa Orthopedic Hospital, Iran University of Medical Science, Tehran. Iran. jabalamelimd@yahoo.com
2. MD., Assistant Professor of Orthopedic Surgery, Shafa Orthopedic Hospital, Iran University of Medical Science, Tehran. Iran. kouros.rahbar@yahoo.com
3. MD., Assistant Professor of Orthopedic Surgery, Shafa Orthopedic Hospital, Iran University of Medical Science, Tehran. Iran. bagherifd@yahoo.com
4. MD., Assistant Professor of Orthopedic Surgery, Arak University of Medical Science, Arak. Iran.hosseinali\_hadi@yahoo.com
5. (**Corresponding author**) MD., Assistant Professor of Orthopedic Surgery, Fellow of knee surgery, Shafa Orthopedic Hospital, Iran University of Medical Science, Tehran. Iran. moradi85ortho@yahoo.com
6. MD., Orthopedic surgeon, Fellow of knee surgery, Shafa Orthopedic Hospital, Iran University of Medical Science, Tehran. Iran. meh\_radi@yahoo.com
7. PhD. Student of Anatomy, Tehran University of Medical Science, Tehran, Iran. tahmineh mokhtari@yahoo.com

### Introduction

The geometry of the proximal tibia and distal femur is intimately linked with the biomechanics of the tibiofemoral and patellofemoral joint (1). Rotational positioning of femoral and tibial components is appeared as a critical aspect of total knee arthroplasty (TKA) since the consequences of malrotation may produce patellofemoral problems, flexion instability, stiffness, and abnormal gait patterns (2, 3). Despite the current high success rate of TKA, patellofemoral complications remain one of common cause of re-

vision surgeries (3). Proper positioning of TKA components is vital for the functional outcome of the procedure. Although the desired positions and guiding landmarks for placement of the femoral and tibial components in the coronal and sagittal planes have been well defined, rotational positioning of the components might still be challenging (4). In the field of total knee arthroplasty, positioning of the implants in the axial plane is referred to as rotational alignment (1).

One of the most common mistakes in TKA is femoral component malrotation, especially in internal rotation. If the femoral component is inserted inappropriately, malrotation induces patellofemoral maltracking and flexion gap mismatch. Patellar maltracking eventually results in patella dislocation or severe limited range of motion and flexion gap mismatch causes knee instability. These complications affect the postoperative clinical outcome and patients' satisfaction and reduce the life span of prosthesis. Multiple researches have confirmed the relation between malrotation of femoral component and early failure of TKA (5, 6).

As mentioned above, it is important to know the exact rotational alignment of distal femur during surgery. Although there are several reference lines to assess the rotation of distal femur that help to make the best cut from posterior aspect of femoral condyles, but there is still disagreement about their significance and mutual angular relationship (1,7). The posterior cut of femur can be done, relative to landmarks on the distal femur or relative to its relation with the tibia (1). Distal femoral references include the posterior femoral condyle axis (PCA), the surgical and anatomical transepicondylar axes (A-TEA) and Whiteside's trochlear anteroposterior line (WAP). The most imperative and ultimate reference for the rotation of the distal femur is surgical transepicondylar axis (S-TEA), the line connecting the tip of the lateral epicondyle to the medial epicondylar sulcus as defined according to Berger et al (8) (Fig. 1). The S-TEA is a valid reference for both the femur and tibia probably because it approximates the flex-

ion-extension axis of the knee and the origin of femoral collateral ligament, but since sometimes it is difficult to identify the femoral epicondyles and medial sulcus during surgery (2), most orthopedic surgeons prefer to use more available posterior femoral condyle axis (PCA) and cut the posterior part of femoral condyle at 3 degrees of external rotation, relative to PCA. They do not notice that many factors such as gender, condylar hypoplasia and coronal alignment of the extremity are able to disturb the rotation of the distal femur and change the angle between PCA and transepicondylar axis from 5° internal rotation to 10° external rotation (3, 9).

On the other hand, evaluation and determination of bony landmarks of the distal femur during surgery in patients with severe knee osteoarthritis is difficult especially if the surgeon lacks adequate skill and can't dissect the soft tissue around the epicondyles without collateral ligaments injury. That is why, preoperative CT scanning approaches have been advised by some researchers (2, 10, 11). By preoperative CT scan, the surgeon can precisely evaluate the angles among transepicondylar axis and anteroposterior line with posterior condylar axis and the possibility of the malposition of the femur may decrease during surgery. Sometimes determination of the medial sulcus in

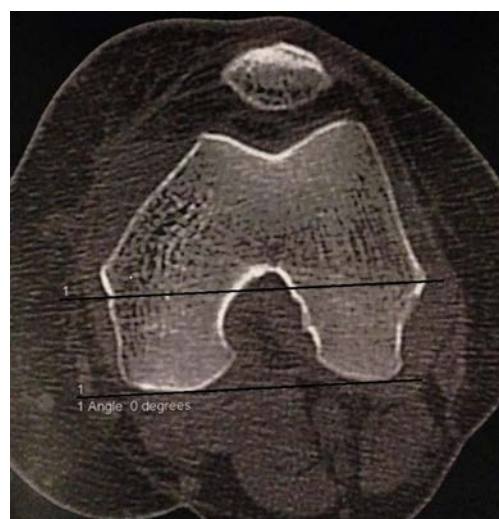

Fig. 1. The surgical transepicondylar axis is parallel to the posterior condylar axis in a 46 years old lady (Curtsey to Archive unit of Shafa Orthopedic Hospital)

CT scan is difficult. More severe the arthritis, more difficult the sulcus to be located (1). With patience and choosing the best CT slice for sulcus identification, usually 30mm from the joint line (11), the sulcus is detected in just 80% of the patients (2,5) and in 20% of patients it is impossible to find the medial sulcus and the surgeon has to use other landmarks. Therefore, assessment of other axes and determining the angles among A-TEA, S-TEA, Whiteside's line and PCA help us to use one axis as an alternative of another if needed.

The purpose of our study was to ascertain the relationships among the described axes guiding distal femur rotational alignment in CT scan and determine if there were any effects of age and gender on these relationships.

### Methods

After approving the study protocol by local ethics committee of the university, informed consent was obtained from the patients. Ninety cases between 16 and 75 years who admitted in two university hospitals, during October 2012 to September 2013, presenting with acute tibial plateau or patella fracture were included in this case series study and their knees were assessed by spiral CT scan. Patients with history of knee pain and limited range of motion were excluded. Other exclusion criteria were: history of severe trauma, history of surgery or inflammatory disease in the knee, malalignment in the extremity, abnormal gait before fracture and obvious tibiofemoral or patellofemoral osteophytes in CT scan.

We used a Siemens Somatom spirit dual CT scanner (Siemens Medical Solutions USA, Malvern, PA) for all scans in both centers. The patient was placed in the supine position on the scanning table with the affected knee in extension. A leg holder was used during imaging to reduce leg movement. A scout view was obtained. CT scans were used to evaluate rotation alignment according to the Berger's CT protocol (8). Multi slice CT scans of the knees with a 1.5-mm slice thickness were obtained from the

femoral distal metaphysis perpendicular to mechanical axes of the femur. All of the scans were analyzed by two knee surgeons separately. The rotation of distal femur was evaluated using the single axial CT image through the femoral epicondyles. This cut is 28 -32 mm above joint line that the medial sulcus is usually seen in it. Sometimes in the medial sulcus there is some small holes related to nutrient vessels. Four lines were drawn digitally in this view on the monitor: 1) The anatomical transepicondylar axis (A-TEA), connects the lateral and medial epi-

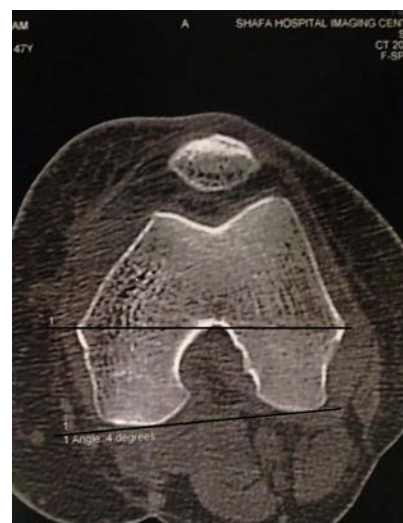

Fig. 2. The anatomical transepicondylar axis is in 4 degrees externally rotation related to the posterior condylar axis in the same case (Curtsey to Archive unit of Shafa Orthopedic Hospital)

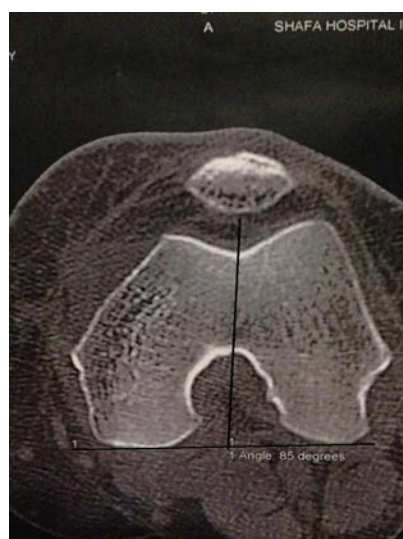


Fig. 3. The Whiteside's line is in 5 degrees externally rotation related to the posterior condylar axis in the same case (Curtsey to Archive unit of Shafa Orthopedic Hospital).

condylar prominence (Fig. 2). 2) The surgical transepicondylar axis(S-TEA), connects the lateral epicondylar prominence and the medial sulcus, posterior the medial epicondyle, (Fig. 1). 3) Posterior condylar axis (PCA) drawn tangent to posterior aspect of two epicondyles of femur. 4) Whiteside's trochlear anteroposterior line (WAP) connects the deepest point of the trochlear groove to the top of the femoral notch (Fig. 3). Then we measured the angles among these lines digitally on the monitor. The posterior condylar angle is formed by the posterior condylar line and the surgical transepicondylar axis. The condylar twist angle is formed by the posterior condylar line and the anatomical transepicondylar axis. This angle is used when the sulcus is absent on the medial side (2). Also we measured the angle between the Whiteside's line and the line perpendicular to PCA and named WAP/PCA angle.

We analyzed the data and evaluated the relationship among these references line with each other and with age and sex factors.

**Results**

Eight patients were excluded from the study. Five cases had a history of chronic knee pain and 3 had a history of surgery on the affected knee. Thus data of 82 cases was analyzed. Mean age of the patients was 38.8±1.93 years (ranging from 16-75). Forty

six patients (56.1%) were male and 36 (43.9%) female.

Mean angle between A-TEA and PCA named Condylar twist angle was 5.68°±1.89° (Table 1). Mean condylar twist angle in male patients was 6.23°±1.95° and in female was 4.97°±1.55° with significant difference between two genders (Table 2, p=0.003).

In 7 male patients (15.2%) and in 9 female patients (25%) we could not find the medial sulcus exactly. In the remaining cases, mean angle between S-TEA and posterior condylar axis (posterior condylar angle) was 1.9°±1.85°. Mean posterior condylar angle in male patients was 2.6°±1.67°and in female was 1°±1.55° and there was a significant difference between the two genders (Table 3, p=0.001).

No significant correlation between patients' age and angles of distal femur was detected. There was a significant correlation between posterior condylar angle and condylar twist angle (r=0.866, p=0.0001). The difference between mean posterior condylar angle and condylar twist angle was 3.78° meaning that A-TEA is in 3.78° externally rotation related to S-TEA in all cases (3.63° in males and 3.97° in females). On the other hand, we could find a significant correlation between posterior condylar angle and WAP/PCA A. (r=0.831, p=0.0001) showing that the axis perpendicular to the WAP is in

Table 1. The size of angles between rotational axes of distal femur in axial CT-scan without gender differentiation.

	A-TEA/PCA angle	S-TEA/PCA angle	A-TEA/S-TEA angle	WAP/PCA angle
Mean	5.68	1.90	3.78	3.89
Std. Deviation	1.89	1.85	0.96	1.64
Minimum	3.00	-1.00	2.00	0.00
Maximum	10.00	5.00	7.00	8.00

A-TEA: Anatomical-Transepicondylar Axis  
 S-TEA: Surgical-Transepicondylar Axis  
 PCA: Posterior Condylar Axis  
 WAP: Whiteside's Anteroposterior Axis

Table 2. Condylar twist angle differentiated by gender.

Sex	Number	Mean	Std. Deviation	p
Male	46	6.23	1.95	0.003
Female	36	4.97	1.55	

Table 3. Posterior condylar angle differentiated by gender.

Sex	Number	Mean	Std. Deviation	p
Male	39	2.60	1.67	0.001
Female	27	1.00	1.69	

Table 4. The angle between Whiteside's anteroposterior axis and line perpendicular to posterior condylar axis differentiated by gender.

Sex	Number	Mean	Std. Deviation	p
Male	46	4.47	1.53	0.000
Female	36	3.13	1.476	1

approximately 2° externally rotation relative to S-TEA in all cases (1.87° in males and 2.13° in females).

### Discussion

Numerous authors have mentioned the significance of proper rotational alignment of the femoral component in total knee arthroplasty (1, 5,9). Positions of the patellar groove and flexion gap stability are determined by the femoral component rotation (12). Rotational malalignment still accounts for an unacceptable number of failures in TKA (1, 5). Sometimes intraoperative determination of the bony landmarks of distal femur and identification the secondary reference axis is difficult for surgeons (13, 14). In a cadaveric study, Victor et al (9) evaluated bony landmarks of distal femur in CT scan. They found that the horizontal plane projections of the posterior condylar line and the surgical and anatomical transepi-condylar axis can be determined accurately on a CT scan with low intra- and inter-observer variability (9).

Berger et al were the first in using CT scans for evaluation of the rotational alignment of the components. In 1993 he defined surgical transepicondylar axis of the distal femur and posterior condylar angle as a reproducible secondary anatomic axis useful for determining the rotational orientation of the femoral component of TKA. They showed that rotational alignment of the femoral component could be accurately estimated using the posterior condylar angle, referenced from the S-TEA. In their measurement, a mean angle between S- TEA and PCA was 3.5 degrees  $\pm$  1.2° for males and 0.3 degree  $\pm$ 1.2° for females. In comparison

with A- TEA, the angles were 4.7° and 5.2° respectively (8). Yoshioka et al (15) observed 32 cadaveric femoral bones and reported a small gender-based difference. They found a condylar twist angle of 5° in males and 6° in females (15). In another CT scan- based study, Nagamine et al (16) evaluated the reliability of A-TEA and WAP line versus PCA in normal knee and the knees with osteoarthritis. They found A-TEA was 6° $\pm$ 2.4° externally rotated relative to PCA. This angle was 5.8°  $\pm$ 2.7° and 6.2°  $\pm$  1.9° in normal knee and involved knee, respectively (16).

In our study, the mean angle between S-TEA and PCA (posterior condylar angle) in healthy Iranian group was 1.9° $\pm$ 1.85° (mean 2.6 $\pm$ 1.67 for male and 1 $\pm$ 1.55 for female patients). These results are close to the study of Berger et al.

On the other hand, in 2008 Aglietti and coworkers studied preoperative knee CT scans of 100 patients with primary osteoarthritis undergoing TKA. They found a linear relationship (p= 0.0001) between the PCA and mechanical axis of the extremity. Also, two genders had similar PCAs (mean, 2.8°  $\pm$  1.7° for women and 2.1°  $\pm$  1.6° for men). They suggested preoperative CT scan as an advantageous, simple, and relatively low-cost tool to identify relevant anatomy and to adjust rotational positioning, but not as a routine plan (2).

Aglietti's study is grounded on the patients with severe osteoarthritis. He distinguished one of limitation of the study while performing on arthritic knees and this could have an influence on outcomes, mainly related to cartilage erosion, especially in the posterior condyles (2). We selected the patients with



acute tibial or patellar fracture without any history of knee problems to evaluate distal femoral landmarks in Iranian healthy cases and omit the bias of Aglietti's study due to cartilage erosion.

As Aglietti experienced, with patience and choosing the best CT slice for sulcus identification, usually 30 mm from the joint line, the sulcus is detected in 80% of the patients. In case the sulcus was absent on the medial side, the condylar twist angle was used instead of posterior condylar angle (2). Yoshino et al (17) studied the relationship between surgical and anatomical TEA in CT scan of 48 patients with osteoarthritis. The medial sulcus could only be determined in 30% of the knees. The sulcus was more difficult to be located as the arthritis was more severe (17).

Although CT scan shows the bony anatomy of distal femur, but its evaluation of the cartilage of distal femur is limited. If it was performed on arthritic knees, this could have an influence on the results attributable particularly to cartilage erosion. Therefore, we decided to evaluate the relationship between the landmarks of distal femur in patients with normal distal femur to reduce the effects of osteoarthritis on the anatomy of this part of the body. On the other hand, because of evaluation of normal knees in our study, the results in finding the medial sulcus were more precise than Yoshino's research. In 7 male (15.2%) and in 9 female patients (25%) we could not find the medial sulcus exactly. For evaluation of distal femoral rotation in these cases, we need the size of angle between surgical and anatomical transepicondylar axis. Based on our study, this angle in healthy Iranian males and females is  $3.63^\circ$  and  $3.97^\circ$  respectively.

The trochlear AP axis was described by Arima and Whiteside as a reliable rotational landmark in 1995. The mean angle with posterior condylar axis was  $3.8^\circ$  of external rotation, but with a high range from  $0.5^\circ$  to  $7^\circ$ . They reported less patellar complication if the trochlear AP axis was used than when the PCA was used as a reference (18). In Nagamine's study, A-TEA was  $1.4^\circ \pm 3.3^\circ$

externally rotated relative to the line perpendicular to the WAP axis (16).

In the current study, mean angle between the line perpendicular to Whiteside's AP axis and PCA in healthy Iranian group was  $3.89^\circ \pm 1.64^\circ$  (mean  $4.47^\circ \pm 1.53^\circ$  for male and  $1^\circ \pm 1.55^\circ$  for female). The results were similar to other researches' (1,16,18). The line perpendicular to the WAP axis was  $2^\circ$  externally rotated relative to S-TEA and  $1.7^\circ$  internally rotated relative to A-TEA.

In 2009, Victor (9) presented a systematic review of previously published articles about rotational alignment of distal femur and different techniques in obtaining correct rotational alignment of the femoral component. Based on the published principles, the posterior condylar line was on average  $3^\circ$  internally rotated relative to the S-TEA,  $5^\circ$  relative to the A-TEA and  $4^\circ$  relative to the perpendicular to the Whiteside's line. He suggested using preoperative CT scans, due to the large ranges and standard deviations of all references axes during surgery, specially the important variability in the surgical location of the TEA (1). In a CT- based study using cadavers, Victor et al evaluated variability of distal femur axes. Inter- and intra-observer variability in the three-dimensional CT reconstructions revealed slight angular errors ranging from 0.16 to 1.15 degrees for all axes except for the trochlear AP axis which had an interobserver error of 2 degrees (19). In another cadaver study they revealed slight inter and interobserver variability in the marketing of transepicondylar axis on CT scans (9).

In our study S-TEA, A-TEA and the line perpendicular to the Whiteside's line were on average  $1.9^\circ$ ,  $5.68^\circ$  and  $3.78^\circ$  externally rotated relative to posterior condylar axis respectively. These results are close to Victor's finding, but unlike that, we evaluated the effect of gender in the rotational reference axes and found significant differences between the two genders. Mean posterior condylar angle, mean condylar twist angle and mean WAP/PCA angle are significantly higher in males than females.

We confirm some limitations of this study. First, the sample size is a little small. For more accurate finding, it is suggested to perform investigations on larger populations. Second, the study was performed on normal knees, but TKA is a surgery for arthritic knees with cartilage erosion. Of course, the S- TEA and A- TEA are better identified in normal knees without osteophytes and cartilage erosion. Thus the angle between S-TEA and A- TEA can be better determined in normal knees.

### Conclusion

This study showed that in Iranian patients, insertion the femoral component of TKA just in 3° external rotation relative to posterior condylar line may cause a mistake in rotational alignment especially in female gender. Preoperative CT scan can help to determine rotational landmarks of distal femur more accurately. If one of the reference axes could not be determined in preoperative evaluation by CT scan or during surgery, we can use another reference axes because of a high correlation between these landmarks.

### References

1. Victor J. Rotational alignment of the distal femur: A literature review. *Orthop Traumatol Surg Res.* 2009; 95(5):365-372.
2. Aglietti P, Sensi L, Cuomo P, Ciardullo A. Rotational position of femoral and tibial components in TKA using the femoral transepicondylar axis. *Clin Orthop Relat Res.* 2008; 466(11):2751-275.
3. Rossi R, Bruzzone M, Bonasia DE, Marmotti A, Castoldi F. Evaluation of tibial rotational alignment in total knee arthroplasty: a cadaver study. *Knee Surg Sports Traumatol Arthrosc.* 2010; 18(7):889-893.
4. Zhang XL, Zhang W, Shao JJ. Rotational alignment in total knee arthroplasty: nonimage-based navigation system versus conventional technique. *Chin Med J (Engl).* 2012; 125(2):236-243.
5. Sun T, Lv H, Hong N. Rotational landmarks and total knee arthroplasty in osteoarthritic knees. *Zhongguo Xiu Fu.* 2007; 21(3):226-230.
6. Uehara K, Kadoya Y, Kobayashi A, Ohashi H, Yamano Y. Bone anatomy and rotational alignment in total knee arthroplasty. *Clin Orthop Relat Res.* 2002; 402:196-201.
7. Berhouet J, Beaufils P, Boisrenoult P, Frasca D, Pujol N. Rotational positioning of the tibial tray in total knee arthroplasty: a CT evaluation. *Orthop Traumatol Surg Res.* 2011; 97(7):699-704.
8. Berger RA, Rubash HE, Seel MJ, Thompson WH, Crossett LS. Determining the rotational alignment of the femoral component in total knee arthroplasty using the epicondylar axis. *Clin Orthop Relat Res.* 1993; 286:40-47.
9. Victor J, Van Doninck D, Labey L, Innocenti B, Parizel PM. How precise can bony landmarks be determined on a CT scan of the knee? *Knee.* 2009; 16(5):358-365.
10. Vaidya SV, Gadhiya RM, Bagaria V, Ranawat AS, Ranawat CS. Computed tomographic evaluation of femoral component rotation in total knee arthroplasty. *Indian J Orthop.* 2013;47(1):40-44.
11. Stiehl JB, Abbott BD. Morphology of the transepicondylar axis and its application in primary and revision total knee arthroplasty. *J Arthroplasty.* 1995;10(6):785-789.
12. Stiehl JB, Cherveney PM. Femoral rotational alignment using the tibial shaft axis in total knee arthroplasty. *Clin Orthop Relat Res.* 1996; 331:47-55.
13. Galaud B, Beaufils P, Michaut M, Abadie P, Fallet L. Distal femoral torsion: comparison of CT scan and intraoperative navigation instruments during total knee arthroplasty .A report of 70 cases. *Rev Chir Orthop Reparatrice Appar.* 2008; 94: 573-579.
14. Jenny JY, Boeri C. Low reproducibility of then intra-operative measurement of the transepicondylar axis during total knee replacement. *Acta Orthop Scand.* 2004; 75: 74-77.
15. Yoshioka Y, Siu D, Cooke TD. The anatomy and functional axes of the femur. *J Bone Joint Surg.* 1987; 69: 873-880.
16. Nagamine R, Miura H, Inoue Y, Urabe K, Matsuda S. Reliability of the anteroposterior axis and the posterior condylar axis for determining rotational alignment of the femoral component in total knee arthroplasty. *J Orthop Sci.* 1998; 3(4):194-198.
17. Yosnhino N, Takai S, Ohtsuki Y , Hirasawa Y. Computed tomography measurement of surgical and clinical transepicondylar axis of the distal femur in osteoarthritic knees. *J Arthroplasty.* 2001;16: 493-494.
18. Arima J, Whiteside LA ,McCarthy DS , White S. Femoral rotational alignment, based on the anteroposterior axis, in total knee arthroplasty in a valgus knee. *J Bone joint Surg.* 1995; 77:1331-1334.
19. Victor J, Van Doninck D, Labey L, Van Glabbeek F, Parizel P. A common reference frame for describing rotation of the distal femur: a CT-based kinematic study using cadavers. *J Bone Joint Surg [Br].* 2009; 91(5):683-689.