

Osteoid Osteoma of the Trapezium in a Forty-Five-Year-Old Man

Olivier Radmanesh^{1,*}

¹Department of Orthopedic Surgery, Centre Hospitalier de Moutiers, Créteil, France

*Corresponding author: Olivier Radmanesh, Department of Orthopedic Surgery, Centre Hospitalier de Moutiers, Créteil, France. Tel: +33-662726412, Fax +33-662726412, E-mail: olivier.radmanesh@orange.fr

Received: July 7, 2014; Revised: August 12, 2014; Accepted: September 20, 2014

Introduction: Osteoid Osteoma (OO) is uncommon in the carpal bones and extremely rare in the trapezium. We report the third case of OO of the trapezium.

Case Presentation: Patient was a 45-year-old man with chronic left wrist pain for 19 months. Pain was intense at night and responsive to nonsteroidal anti-inflammatory drugs. There was a local tenderness on the trapezium. The wrist X-ray images revealed normal findings, but bone scan, computed tomographic scan, and magnetic resonance imaging indicated OO as the possible diagnosis. The patient was treated by curettage and bone graft of the trapezium. Histopathologic examination confirmed the diagnosis of OO.

Discussion: OO of the trapezium should be included in differential diagnosis list in patients with chronic wrist pain.

Keywords: Osteoid Osteoma; Trapezium; Carpal Bone

1. Introduction

Osteoid osteoma (OO) is a benign and painful osteoblastic tumor that involves patients in their third and fourth decades of life (1). It occurs more frequently in long bones of the lower extremities (2). OO rarely involves carpal bones, but when it does, the scaphoid bone is most frequently involved (1-3). Its occurrence is extremely rare in trapezium and only few cases of OO in trapezium were reported previously (4).

2. Case Presentation

The patient was a 45-year-old, right-handed, air condition technician who presented to the hand clinic with a chief complaint of left wrist pain for 19 months. He had no history of trauma. His medical history was also insignificant regarding any inflammatory disease. The pain was more intense and severe at night. The patient received medication and underwent immobilization of the wrist by short arm cast for possible diagnosis of the wrist sprain; however, these treatments were not effective. The patient used to reduce the pain by nonsteroidal anti-inflammatory drugs. At first presentation, findings of physical examination were normal except the findings in his left wrist. Skin and range of motion of the wrist were normal. There was a severe local tenderness at the base of the thumb on the trapezium.

Routine laboratory tests including complete blood cell count, erythrocyte sedimentation rate, C reactive protein was in normal range. Wrist X-rays findings were normal (Figure 1). A whole body bone scan showed increased uptake at the trapezium area (Figure 2). Computed tomographic scan demonstrated dense nidus at the trapezium

(Figure 3). Magnetic resonance imaging revealed bone marrow edema of the trapezium (Figure 4). The patients' medical history and findings of physical examination as well as imaging studies were suggestive of OO of the trapezium.

Under general anesthesia through a small dorsal approach, we made a window at dorsal aspect of the trapezium, performed curettage, and impacted the void area with cancellous bone graft, which was harvested from the ipsilateral distal radius. A highly vascular reddish specimen was sent for histopathologic examination, which confirmed the diagnosis of OO (Figure 5). The patient was pain free during the 13 months after surgery. We obtained written consent of our patient to publish the report.

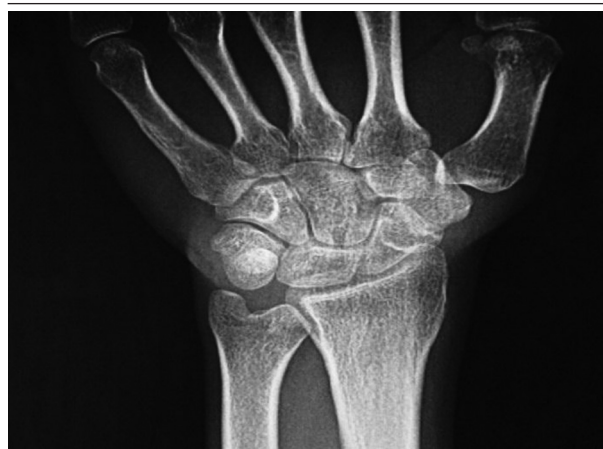

Figure 1. Anteroposterior X Ray of the Left Wrist

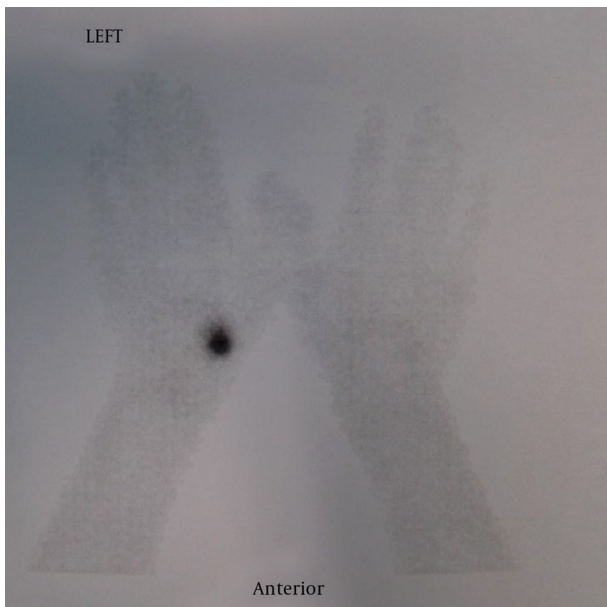


Figure 2. Bone Scan Shows Increased Uptake at Left Trapezium Area.

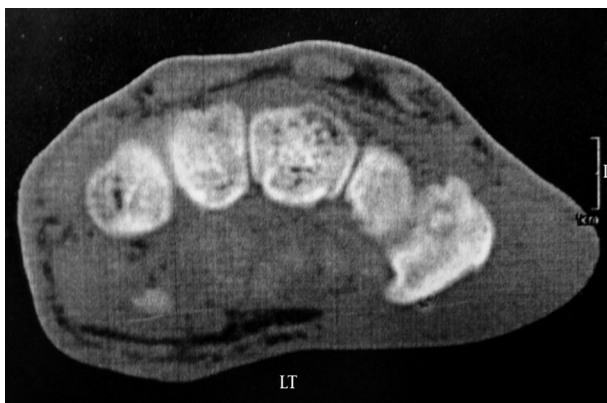

Figure 3. Computed Tomographic Scan, Axial View of the Left Wrist Showing a Nidus in the Trapezium.

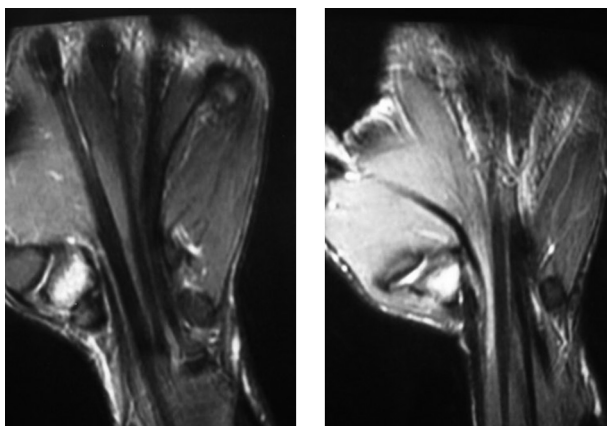


Figure 4. T2-Weighted Magnetic Resonance Imaging Showing Bone Edema in Trapezium.

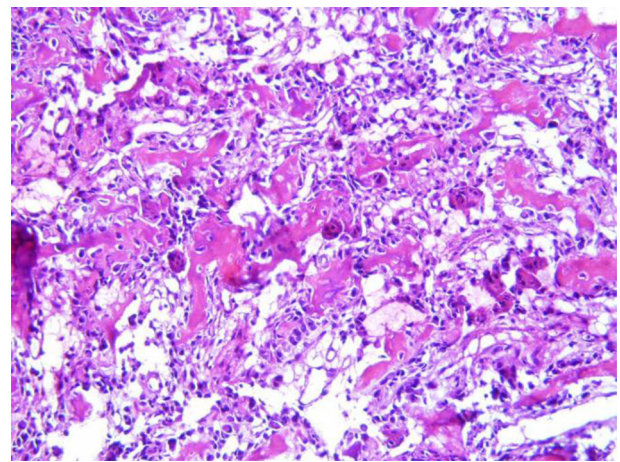


Figure 5. Hypervascular Osteoblastic Tissue With Osteoid Formation in Histopathologic Examination of the Osteoid Osteoma of the Trapezium (Hematoxylin and Eosin stain, magnification $\times 30$)

3. Discussion

Generally, OO is a rare benign bone forming tumor, first described by Jaffe in 1935 (5). It usually involves long bones of the lower extremities and affects men twice as many as women (3, 4). It usually occurs in young adults (3). Pain is the most common chief complaint followed by swelling and local tenderness (2, 3). Our patient was a male in his fifth decade of life who presented with severe wrist pain and local tenderness on the involved bone. The OO was reported in upper extremity in case series. Phalanxes are the most common involved location (2, 3, 5). The OO rarely involves carpal bones, but when it does, scaphoid bone is the most frequently involved bone. It has been reported in trapezoid in few cases. Jafari et al. reported an OO of trapezoid bone in a 42-year-old man in whom the lesion was missed for months (6). They treated the patient by simple curettage. According to their experience, OO should be considered as a possible diagnosis in a young patient who was admitted due to wrist pain (6). OO has been reported in trapezium of two patients previously (4). The first one was a 16-year-old boy and the second one was a 25-year-old man, both of them with sclerotic lesion in the trapezium (4). In our patient, the findings of the wrist radiographs were normal, which was in accordance with many previously reported cases of carpal bones OO with normal X-ray findings (6). This indicates that the diagnosis of the OO in this bone will not be straight forward.

Diagnosis of the OO in the upper extremity can be challenging. Themistocleous et al. described this challenge of diagnosis by reporting 48 patients with clinical and imaging characters of OO in the upper extremity (7). They concluded that a high index of suspicion as well as appropriate clinical and imaging modalities are essential in diagnosis of the OO located in the upper extremity (7). Similar to other carpal bone tumors, OO can be misdiagnosed as neuroma, arthritis, de Quervain's tenosynovitis,

avascular bone necrosis, infection, and many other painful conditions (6). The diagnosis of the OO in the carpal bones usually delays and results in malpractice (6, 7). In the same manner, it took 19 months to reach the accurate diagnosis in our patient.

Even though OO is extremely rare in trapezium, this case report indicated that it should be kept in mind as a possible differential diagnosis in chronic wrist pain regardless of the patient's age.

References

1. Laffosse JM, Tricoire JL, Cantagrel A, Wagner A, Puget J. Osteoid osteoma of the carpal bones. Two case reports. *Joint Bone Spine*. 2006;**73**(5):560-3.
2. Jafari D, Shariatzade H, Mazhar FN, Abbasgholizadeh B, Dashteborzogh A. Osteoid osteoma of the hand and wrist: a report of 25 cases. *Med J Islam Repub Iran*. 2013;**27**(2):62.
3. Carroll RE. Osteoid osteoma in the hand. *J Bone Joint Surg Am*. 1953;**35-A**(4):888-93.
4. Bostan B, Sen C, Gunes T, Erdem M, Koseoglu RD. Osteoid osteoma of the trapezium: case report. *J Hand Surg Am*. 2010;**35**(4):636-8.
5. Jaffe HL. Osteoid-Osteoma. *Arch Surg*. 1935;**31**(5):709.
6. Jafari D, Najd Mazhar F. Osteoid osteoma of the trapezoid bone. *Arch Iran Med*. 2012;**15**(12):777-9.
7. Themistocleous GS, Chloros GD, Benetos IS, Efsthopoulos DG, Gerostathopoulos NE, Soucacos PN. Osteoid osteoma of the upper extremity. A diagnostic challenge. *Chir Main*. 2006;**25**(2):69-76.