

# Results of Total Knee Arthroplasty in Patients with Pigmented Villonodular Synovitis-Reporting Three Cases

Mahmoud Jabalameli,<sup>1</sup> Hosseinali Hadi,<sup>2</sup> Vahid Behshad,<sup>1</sup> Tohid Safaei,<sup>1</sup> Ali Shahsavari Pour,<sup>1</sup> and

Salman Ghaffari<sup>1\*</sup>

<sup>1</sup>Bone and Joint Reconstruction Research Center, Shafa Orthopedic Hospital, Iran University of Medical Sciences, Tehran, IR Iran

<sup>2</sup>Arak University of Medical Science, Arak, Iran

\*Corresponding author: Salman Ghaffari, Bone and Joint Reconstruction Research Center, Shafa Orthopedic Hospital, Iran University of Medical Sciences, Tehran, IR Iran. Tel: +98-9122882894, Fax: +98-2133542022, E-mail: orthosalman@yahoo.com

Received 2016 December 04; Revised 2017 January 04; Accepted 2017 January 10.

## Abstract

**Introduction:** The knee is the most commonly affected joint in the pigmented villonodular synovitis (PVNS). If misdiagnosed or mismanaged, PVNS, especially the diffused form can destroy joints and can result in terminal degenerative joint disease.

**Case Presentation:** We report 3 cases of diffuse form of PVNS with grade 3 osteoarthritis that is treated by total synovectomy and total knee arthroplasty (TKA). The mean duration of the follow-up was 46.5 (9, 11, 120) months. In 2 cases, staged posterior then anterior synovectomy and TKA were done with excellent results. In 1 case, simultaneous synovectomy and TKA was performed with hematoma formation postoperatively and quadriceps tendon rupture 10 weeks later with fair final result.

**Conclusions:** TKA in PVNS is a challenging procedure. We recommend open posterior synovectomy then anterior synovectomy and TKA in 2 separate operations. Quadriceps mechanism must be protected during synovectomy.

**Keywords:** Pigmented Villonodular Synovitis, Total Knee Arthroplasty, Synovectomy

## 1. Introduction

Pigmented villonodular synovitis (PVNS) is a proliferative disorder that involves the synovial joints, tendon sheaths, and bursae. The knee is the most commonly affected joint (1).

PVNS is presented in 2 localized or diffused forms according to the extent of synovial involvement. If misdiagnosed or mismanaged, PVNS especially the diffuse form, can destroy the joint resulting in terminal degenerative joint disease (2).

Ultrasonography can detect the intra-articular mass and define its structure, but cannot specifically diagnose the PVNS (3). MRI can specifically diagnose the PVNS and identify the extent of intra-articular mass, differentiating localized from diffuse form (3).

PVNS may recur after arthroscopic or open complete synovectomy and even after total knee arthroplasty with concomitant total synovectomy. MRI can be used in these suspected cases even in the cases with prosthesis to detect recurrent masses (4).

In this study, we report 3 cases of diffuse knee PVNS with osteoarthritis that was treated by total knee replacement. All cases gave written consent to publish this article and the study was approved by the IRB of our institution.

## 2. Case Presentation

### 2.1. Case 1

A 61-year-old woman was referred to our clinic because of right knee pain and swelling. She had a history of painful swelling of the knee for about 8 years and was treated by open debridement for 7 years and aspiration and corticosteroid injection 6 years before admission in another center. At presentation, the right knee had obvious swelling with large all-around palpable mass with 0 - 100 ranges of motion (ROM). She had no history of trauma, rheumatoid or hematologic disorder and diabetes mellitus. In AP/lateral X-rays grade 3 osteoarthritis, according to Kellgren and Lawrence, radiographic grading system (5) and huge soft tissue mass shadow in suprapatellar pouch and posterior popliteal area was seen (Figures 1a and 1b). An MRI showed the extent of the mass and was in favor of PVNS (Figure 1c). Because of weak tibialis posterior (TP), pulse angiography was performed, which confirmed TP occlusion and mass blood perfusion from genicular branches (Figure 1d). Arthroscopic biopsy confirmed the diagnosis of PVNS. Surgery was done in 2 stages. In the first stage, 3 months after the biopsy, in prone position and lazy S popliteal incision the posterior mass excised. One month later, in supine position, with standard anterior midline incision, anterior mass excised and posterior

stabilized total knee arthroplasty (TKA) with LPS prosthesis (Zimmer Biomet, Warsaw, Indiana, USA) was performed. At the 10 year follow-up she is painless without recurrence of disease and the prosthesis is stable (Figures 1e and 1f). According to the knee injury and osteoarthritis outcome score (KOOS) (6) the functional result is excellent.

### 2.2. Case 2

A 63-year-old man who had a diffuse form of PVNS and history of 2 time open right knee arthrotomy and synovectomy with 3 incisions in posterior, medial, and anterior surface of the knee in 2002 and 2003 in another center. The ultrasound showed 2 40 × 26 and 45 × 30 millimeters masses in popliteal space of knee. MRI confirmed the masses (Figure 2a). On admission he had grade 3 osteoarthritis, according to Kellgren and Lawrence radiographic grading system (Figure 2b). ROM was 60 degrees with 20 degrees flexion contracture. Due to the severe disabling pain, total knee replacement with LCKK prosthesis (Zimmer Biomet, Warsaw, Indiana, USA) was performed. At the time of TKA 2 masses and synovium were excised. One year after TKA he has no pain or swelling. ROM is 110 degrees without flexion contracture. Prosthesis is well fixed (Figure 2c). According to knee injury and osteoarthritis outcome score (KOOS) the functional result is excellent.

### 2.3. Case 3

An 80-year-old man with history of a car to pedestrian accident 8 years before referring to our clinic without history of fracture or soft tissue injury of his left knee. His main complaint was his left knee pain and swelling. ROM was 90 degrees with 10 degrees flexion contracture. In the X-ray, grade 3 osteoarthritis, according to Kellgren and Lawrence radiographic grading system, and diffuse soft tissue mass was seen (Figures 3a and 3b). The MRI revealed characteristic findings of diffuse PVNS. Arthroscopic biopsy was performed and confirmed the diagnosis. Two months later, with anterior standard medial parapatellar approach, total synovectomy and rotating hinged TKA (Zimmer Biomet, Warsaw, Indiana, USA) was performed. One-week after the operation, the patient returned to the operating room, the hematoma was evacuated and hemovac drain inserted then discharged without complication 1 week later. Ten weeks after TKA, the patient suffered simple falling down and quadriceps femoris tendon ruptured (Figure 3c). Direct repair of quadriceps femoris tendon and augmentation with no 5 non-absorbable suture performed. At the last visit, 9 months after index operation, the patient had 30-degree extension lag with 0 - 110 passive ROM. Prosthesis is stable without recurrence of disease (Figures 3d and 3e). According to knee

injury and osteoarthritis outcome score (KOOS) Functional result is fair.

## 3. Discussion

Diffuse pigmented villonodular synovitis of the knee may be present with pain, swelling, and recurrent effusion. If neglected or misdiagnosed, the joint destruction and osteoarthritis is the final result. Distinguishing between primary osteoarthritis and PVNS induced osteoarthritis it can be difficult in the chronic phase of diffuse knee PVNS (1, 2).

We used the Kellgren and Lawrence radiographic grading system to evaluate the severity of knee degenerative changes (5). All 3 cases had grade 3 osteoarthritis according to this system.

All 3 cases had pain, swelling, effusion, and palpable masses. In all 3 cases, PVNS diagnoses were confirmed with MRI and biopsy prior to total knee arthroplasty.

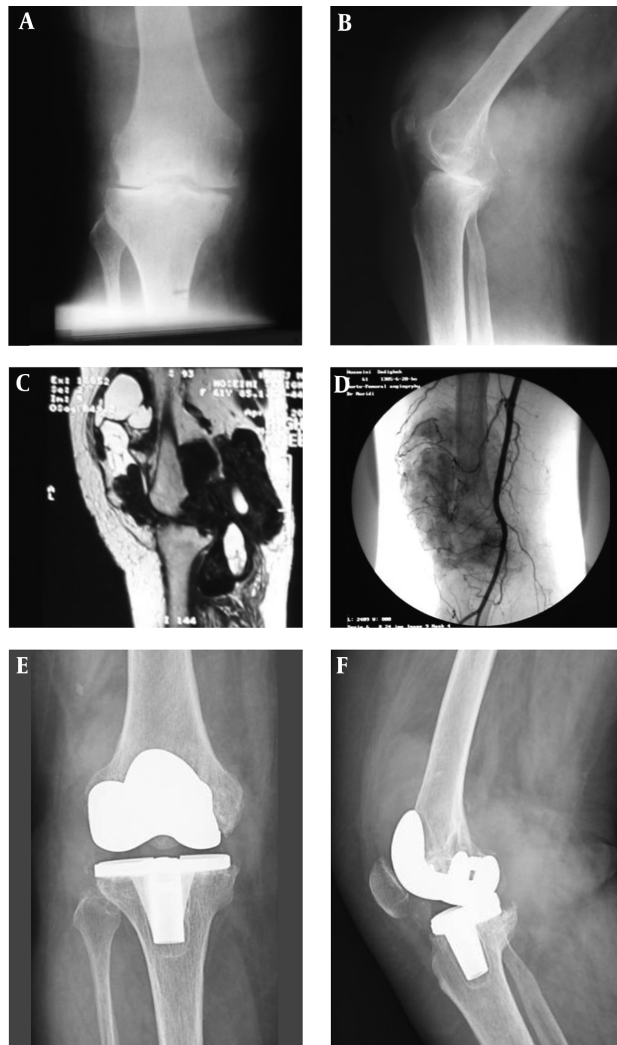
To evaluate the final outcome of the patients we used the knee injury and osteoarthritis outcome score (KOOS) (6).

Hamlin et al. (7) published the results of total knee replacement performed for the treatment of osteoarthritis in 18 cases with pigmented villonodular synovitis, the largest series that ever reported. Fourteen patients with diffuse form and 4 with localized form. At the same time of TKA they performed total or partial synovectomy in diffuse and localized forms, respectively. After the mean follow-up of about 10 years, 14 of the 18 cases had good results. Four poor results were in active diffuse form. Aseptic loosening was seen in 3 cases and PVNS recurrence was seen in 1 case. One case was due to the complications treated with amputation. There are many reports of PVNS diagnosis after total or unicompartmental knee arthroplasty. It may reoccur or might have a new development of PVNS in the setting of knee arthroplasty. PVNS should be in mind when dealing with any case of painful total knee prosthesis (8, 9).

With these outcomes in mind we performed total synovectomy simultaneously or before TKA. We didn't see a recurrence in our patients even in case 1 with a 10 year follow-up.

Akinci et al. (10) reviewed the result of 5 TKA in 4 patients, all women. All patients were under osteoarthritis treatment, PVNS diagnosed during TKA procedure, emphasizing the importance of considering PVNS in differential diagnosis of gonarthrosis. All 5 knees had diffuse form and total synovectomy was performed during the TKA procedure. After the mean follow-up of 68 months there was no recurrence of PVNS and the result was perfect in 3 knees and good in 2 knees.

In our patients, PVNS was diagnosed before TKA and we planned the surgery accordingly. In cases 1 and 2, with



**Figure 1.** A and B, grade 3 knee osteoarthritis; C, MRI shows diffuse PVNS; D, angiography shows vascular pattern of PVNS masses; E and F, 10 years after total knee arthroplasty

huge masses in anterior and posterior compartments, posterior synovectomy was performed first and in the second stage anterior synovectomy and TKA was performed.

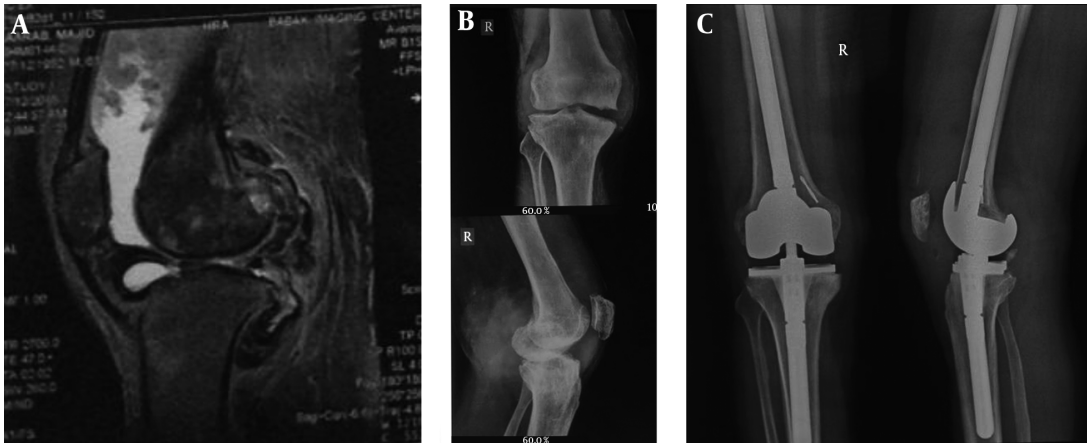
Case 3, an 80-year-old patient, suffered quadriceps tendon rupture after a simple fall. This rupture may be due to traumatic injury in a weak and degenerated tendon. It is the consequence of postoperative hematoma and surgical evacuation or simultaneous aggressive total synovectomy and TKA.

Surgeons must keep in mind that TKA in PVNS is a challenging procedure. During the total synovectomy, extensor mechanism must be protected. We recommend staged total synovectomy and TKA in massive diffuse form of PVNS. Short and long-term results of TKA in 2 of the 3 patients are excellent. No recurrence is seen in our patients

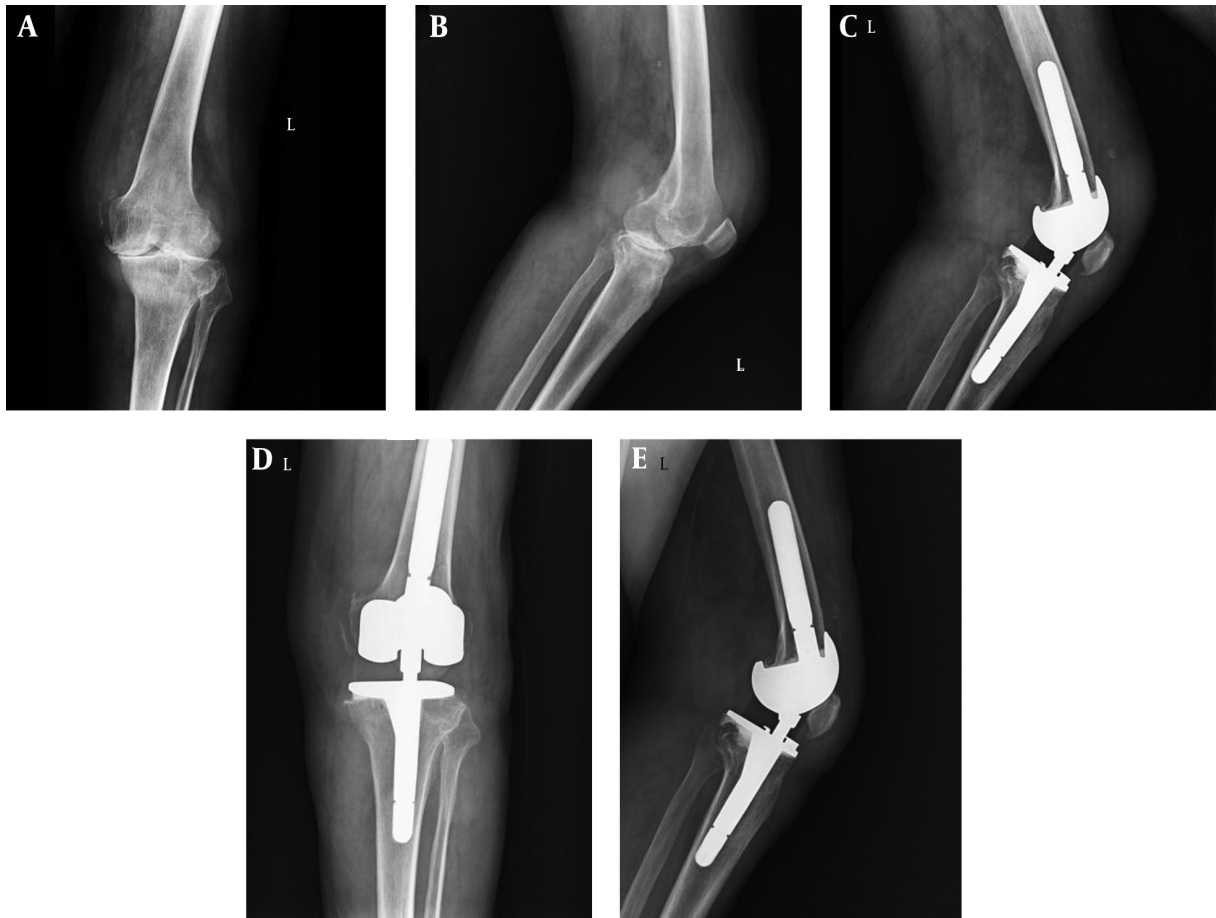indicating the importance of total synovectomy in the diffuse form of PVNS. When clinical and radiographic indications are enough, total knee arthroplasty with total synovectomy performed in stages is recommended in diffuse form of PVNS.

#### Footnote

**Authors' Contribution:** Study design: Mahmoud Jabalameli; data acquisition, manuscript draft, critical revision: Mahmoud Jabalameli, Hosseinali Hadi, Vahid Behshad, Tohid Safaei, Ali Shahsavari Pour and Salman Ghaffari.



**Figure 2.** A, MRI shows diffuse PVNS; B, radiography shows grade 3 osteoarthritis; C, final follow up radiography with well-fixed prosthesis



**Figure 3.** A and B, radiographs show grade 3 osteoarthritis; C, 10 weeks postoperative radiograph after quadriceps tendon rupture; D and E, 9 months after total knee arthroplasty

## References

1. Auregan JC, Klouche S, Bohu Y, Lefevre N, Herman S, Hardy P. Treatment of pigmented villonodular synovitis of the knee. *Arthroscopy*. 2014;**30**(10):1327-41. doi: [10.1016/j.arthro.2014.04.101](https://doi.org/10.1016/j.arthro.2014.04.101). [PubMed: [24999007](https://pubmed.ncbi.nlm.nih.gov/24999007/)].
2. Qingtian L, Hong C, Mengyuan L, Yuanchen M, Junxing L, Qiujian Z. Multifocal Pigmented villonodular synovitis in adult: a case report and review of the literature. *Arch Med*. 2015;**7**(2):6.
3. Bassetti E, Candrea R, Santucci E. Pigmented villonodular synovitis of the knee: A case report. *J Ultrasound*. 2011;**14**(3):167-9. doi: [10.1016/j.jus.2011.02.001](https://doi.org/10.1016/j.jus.2011.02.001). [PubMed: [23396820](https://pubmed.ncbi.nlm.nih.gov/23396820/)].
4. Friedman T, Chen T, Chang A. MRI diagnosis of recurrent pigmented villonodular synovitis following total joint arthroplasty. *HSS J*. 2013;**9**(1):100-5. doi: [10.1007/s11420-012-9283-y](https://doi.org/10.1007/s11420-012-9283-y). [PubMed: [24426852](https://pubmed.ncbi.nlm.nih.gov/24426852/)].
5. Kellgren JH, Lawrence JS. Radiological assessment of osteo-arthritis. *Ann Rheum Dis*. 1957;**16**(4):494-502. [PubMed: [13498604](https://pubmed.ncbi.nlm.nih.gov/13498604/)].
6. Knee injury and Osteoarthritis Outcome Score (KOOS) . KOOS Denmark: Knee injury and Osteoarthritis Outcome Score (KOOS); Available from: [www.koos.nu](http://www.koos.nu).
7. Hamlin BR, Duffy GP, Trousdale RT, Morrey BF. Total knee arthroplasty in patients who have pigmented villonodular synovitis. *J Bone Joint Surg Am*. 1998;**80**(1):76-82. doi: [10.2106/00004623-199801000-00013](https://doi.org/10.2106/00004623-199801000-00013). [PubMed: [9469312](https://pubmed.ncbi.nlm.nih.gov/9469312/)].
8. Ma XM, Xia CY, Fu PL, Liu HM, Yu HY, He J. Unusual cases of pigmented villonodular synovitis after arthroplasty. *Int J Clin Exp Med*. 2014;**7**(4):1150-4. [PubMed: [24955198](https://pubmed.ncbi.nlm.nih.gov/24955198/)].
9. Onodera T, Tanji H, Majima T, Kamishia T, Minami A. An unusual case of pigmented villonodular synovitis after unicompartmental knee arthroplasty. *Int J Case Reports And Images*. 2012;**3**(9):9-12. doi: [10.5348/ijcri-2012-09-173-CR-3](https://doi.org/10.5348/ijcri-2012-09-173-CR-3).
10. Akinci O, Akalin Y, Kayali C. Results of total knee arthroplasty in patients with gonarthrosis resulting from the delayed diagnosis of PVNS: a case series. *Eur J Orthop Surg Traumatol*. 2012;**22**:51-6. doi: [10.1007/s00590-011-0784-z](https://doi.org/10.1007/s00590-011-0784-z).