

# Avulsion Fracture of Extensor Carpi Radialis Brevis Insertion: A Case Report and Review of Literature

Hooman Shariatzadeh,<sup>1</sup> and Bahman Hosseini<sup>1,\*</sup>

<sup>1</sup>Bone and Joint Reconstruction Research Center, Shafa Orthopedic Hospital, Iran University of Medical Sciences, Tehran, IR Iran

\*Corresponding author: Bahman Hosseini, Bone and Joint Reconstruction Research Center, Shafa Orthopedic Hospital, Iran University of Medical Sciences, Tehran, IR Iran. Tel: +98-213354010, Fax: +98-2133542020, E-mail: bahman098@gmail.com

Received 2016 December 04; Revised 2016 December 23; Accepted 2016 December 28.

## Abstract

**Introduction:** Avulsion of extensor carpi radialis brevis (ECRB) insertion from dorsal base of the third metacarpal with or without bony chips is rarely reported.

**Case Presentation:** The current study reported the case of a young male that after falling down the stairs, referred to emergency room with dorsal wrist pain and weakness in wrist extension, and the lateral X-ray showed a bone fragment of dorsal capitate, but the computed tomography (CT) scan proved that the fragment was detached from the third metacarpal base. Then, with the diagnosis of ECRB avulsion fracture of its metacarpal base, the patient was operated and the fragment and accompanying tendon were fixed with 3 k-wires to its anatomic location and after 6 weeks of casting the pins were removed and at 6 months post-operation the range of motion and strength were the same as those of contralateral side.

**Conclusions:** ECRB avulsion is a rare condition, and its diagnosis can be difficult, and it should be in differential diagnosis of wrist trauma with tenderness on the base of the third metacarpal bone.

**Keywords:** Extensor Carpi Radialis Brevis, Avulsion Fracture, Third Metacarpal, Tendon

## 1. Introduction

Avulsion fracture of the base of the third metacarpal with retraction of extensor carpi radialis brevis (ECRB) tendon is a rare event that only 9 of these cases were previously reported (1). Dorsal wrist swelling and an avulsion of a bony fragment dorsally accompanied by pain characterize it with a previous trauma history (1).

Avulsion fracture of extensor carpi radialis longus (ECRL) is a similar injury reported in the literature with reference to classic ECRB avulsion, either concomitant or isolated (2).

## 2. Case Presentation

The current study was approved by the ethics board of the institution and the patient signed written consent to publish the case report. A 24-year-old male graphic student came to emergency room of Shafa Hospital with right wrist pain after falling while going down the stairs, with a 5 cm × 5 cm ecchymosis mild swelling on dorsum of wrist and intact overlying skin and minor limitation in passive range of motion, but weak dorsiflexion and intact neurovascular status. There was no history of concomitant rheumatologic or osteoporotic diseases, but had a history of testosterone and creatine abuse 5 years prior to the accident, for body building, only for a short time. The wrist

was neither deviated nor deformed and the digits were all normal. Plain radiographs showed nearly normal wrist anterior-posterior view (Figure 1), and a 3 mm × 10 mm bony fragment on dorsum of capitate in lateral view (Figure 2), which its origin could not be found with certainty, the computed tomography (CT) scan showed the void area at the base of the metacarpal and suggested that the fragment can be the base of the third metacarpal bone (Figure 3). The patient was prepared for surgical exploration and with a longitudinal incision on the dorsal aspect of the third metacarpus and more proximally, the fragment exposed, showed that the ECRB tendon was still attached to the fragment and some soft tissue adhesions prevented the fragment to be migrated more proximally and the articular surface was split in half (Figure 4). Then the fragment accompanying its tendon were reinserted anatomically and fixed with 3 K-wires; then a short arm cast was applied to immobilize the wrist in 30 degree dorsiflexion (Figure 5). After 6 weeks of casting, the fracture was united nicely and the pins were removed (Figure 6). With no physical therapy the wrist gained full active range of motion and strength in 6 months post-operatively.

## 3. Discussion

In spite of fractures of proximal first metacarpus, that is very well described (2), very little is written about the

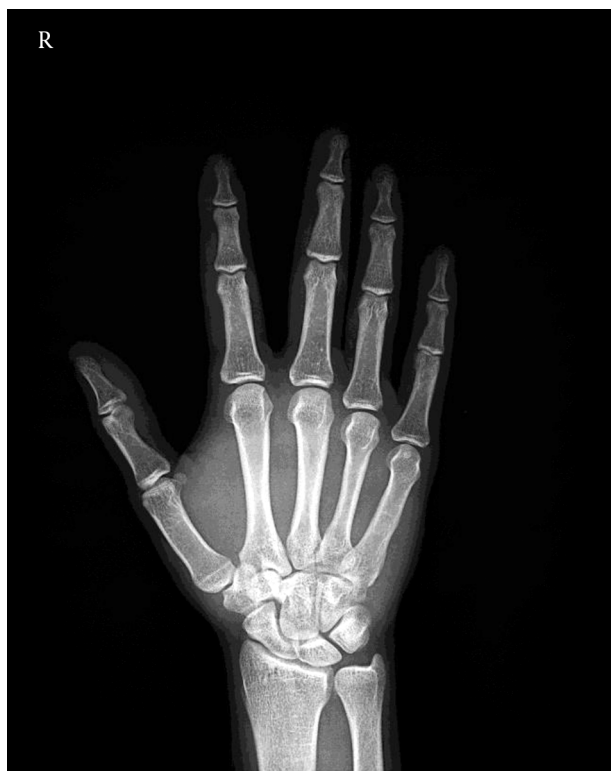

Figure 1. Anterior-Posterior Radiograph of Wrist

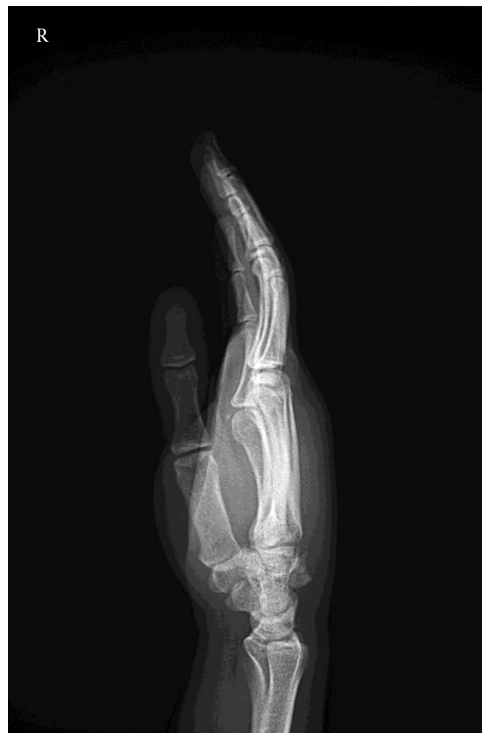

Figure 2. Lateral Radiograph of the Wrist Shows the Avulsion

third one with a mechanism of flexion moment of wrist with contraction of ECRB for avulsion (1,3). Diagnosis of an isolated ECRB rupture is difficult (2,3). The base of the third metacarpal is surrounded by neighboring joints and very strong transverse interosseous and capsular ligaments (3-7), and also concave joint dorsally and ECRB attaching next to a short styloid (5); therefore, avulsion is more prevalent than dislocation. Also, ECRB is more effective for wrist extension than ECRL because of moment arm and not being affected by elbow position (4). Besides abrupt acceleration and deceleration of the tendons for rupture, fluoroquinolone antibiotics are also a cause of tendon rupture especially in Achilles tendon (8); the tendinitis and use of steroids and creatine are also considered (8). Although congruity of the joint is not very important, since there is little movement in the joint (2), open reduction of the fragment is recommended due to the intra articular nature of the fragment (2). Reattaching the fragment may also prevent extensor tendon abrasion and bossing (3). Many types of reattaching the tendon and the fragment are described; cerclage wiring and K-wires (4), anchor sutures and screw (3), tension band wiring (7), anchor suture (1), and tension band (9). ECRB can also be detached from the fragment and

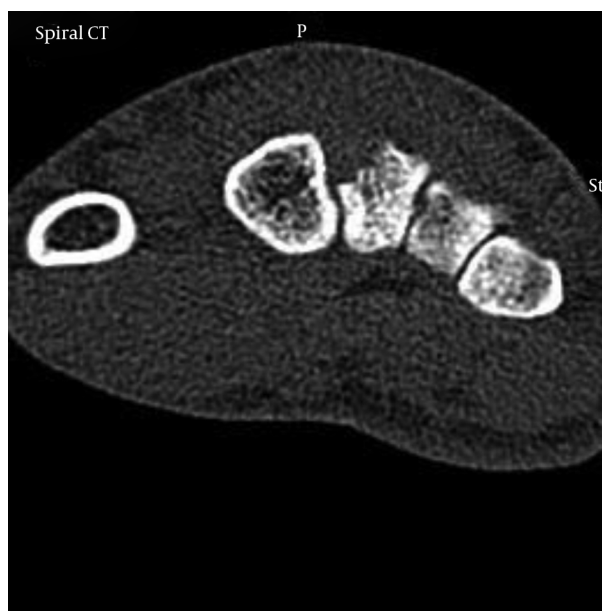
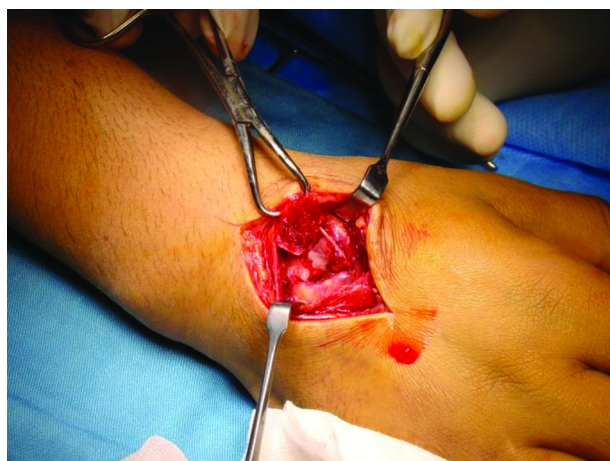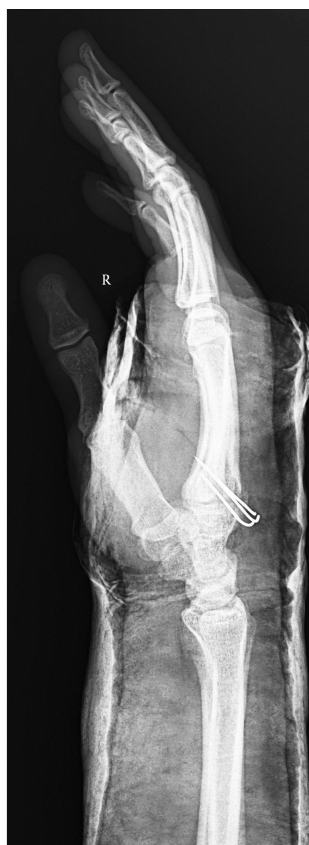


Figure 3. CT Scan Shows Void Area at the Base of the 3rd Metacarpal Bone

further anchor suturing is needed (3). But there was a report not being able to bring ECRB back to its normal inser-

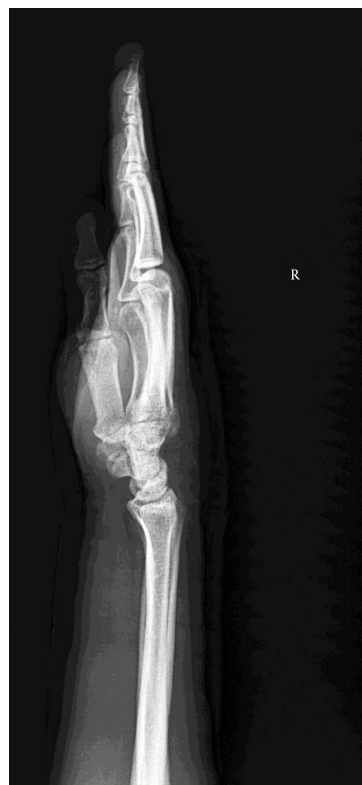

**Figure 4.** Intraoperative Finding Shows Avulsion of the Base of 3rd Metacarpal Bone



**Figure 5.** Postoperative Radiograph After Open Reduction and Fixation With 3 K-Wires

tion site after 12 days and attaching it side to side to ECRL led to loss of grip strength and active motion (3). Even con-



**Figure 6.** After Pin Removal, the Avulsion Healed

servative treatment of the patient with removal of the fragment is reported (6). The current study was on a traumatic isolated lesion of the wrist ECRB, the muscle and the tendon inserted on the third metacarpus. Literature review revealed 9 case reports in addition to the current patient (1). In the present case ECRB was completely attached to the fragment, but there were reports showing partial tendon detachment from the fragment (2). Advocating a surgical treatment is controversial, but since ECRB is the main wrist extensor while ECRL is radial deviating extensor and elbow flexor (1), to achieve wrist extension and avoid unrepaired avulsion and carpometacarpal boss (2) prompt repair should be initiated.

It seems that this injury is more common than previously stated, and with proper surgical treatment it heals uneventfully with no complication, and more predictable outcome can be expected.

#### Footnotes

**Authors' Contribution:** Hooman Shariatzadeh and Bahman Hosseini: diagnosis and treatment, drafting and revision of the manuscript.

**Financial Disclosure:** None.

## References

1. Turker T, Capdarest-Arest N. Open isolated extensor carpi radialis brevis avulsion injury: a case report. *Hand (N Y)*. 2013;**8**(3):354-7. doi: [10.1007/s11552-013-9510-0](https://doi.org/10.1007/s11552-013-9510-0). [PubMed: [24426949](https://pubmed.ncbi.nlm.nih.gov/24426949/)].
2. DeLEE JC. Avulsion fracture of the base of the second metacarpal by the extensor carpi radialis longus. A case report. *J Bone Joint Surgery*. **3**(61):445-6.
3. Boles SD, Durbin RA. Simultaneous ipsilateral avulsion of the extensor carpi radialis longus and brevis tendon insertions: case report and review of the literature. *J Hand Surg Am*. 1999;**24**(4):845-9. [PubMed: [10447178](https://pubmed.ncbi.nlm.nih.gov/10447178/)].
4. Rotman MB, Pruitt DL. Avulsion fracture of the extensor carpi radialis brevis insertion. *J Hand Surg Am*. 1993;**18**(3):511-3. doi: [10.1016/0363-5023\(93\)90101-8](https://doi.org/10.1016/0363-5023(93)90101-8). [PubMed: [8515025](https://pubmed.ncbi.nlm.nih.gov/8515025/)].
5. Tsiridis E, Kohls-Gatzoulis J, Schizas C. Avulsion fracture of the extensor carpi radialis brevis insertion. *J Hand Surg Br*. 2001;**26**(6):596-8. doi: [10.1054/jhsb.2001.0662](https://doi.org/10.1054/jhsb.2001.0662). [PubMed: [11884121](https://pubmed.ncbi.nlm.nih.gov/11884121/)].
6. Vandeputte G, De Smet L. Avulsion of both extensor carpi radialis tendons: a case report. *J Hand Surg Am*. 1999;**24**(6):1286-8. doi: [10.1053/jhsu.1999.1286](https://doi.org/10.1053/jhsu.1999.1286). [PubMed: [10584955](https://pubmed.ncbi.nlm.nih.gov/10584955/)].
7. Cobbs KF, Owens WS, Berg EE. Extensor carpi radialis brevis avulsion fracture of the long finger metacarpal: a case report. *J Hand Surg Am*. 1996;**21**(4):684-6. doi: [10.1016/S0363-5023\(96\)80027-X](https://doi.org/10.1016/S0363-5023(96)80027-X). [PubMed: [8842967](https://pubmed.ncbi.nlm.nih.gov/8842967/)].
8. Mundell T, Miladore N, Ruiter T. Extensor carpi radialis longus and brevis rupture in a boxer. *Eplasty*. 2014;**14**:ic40. [PubMed: [25525487](https://pubmed.ncbi.nlm.nih.gov/25525487/)].
9. Voigt C. [Osseous rupture of the attachment of the tendon of the extensor carpi radialis brevis muscle]. *Handchir Mikrochir Plast Chir*. 1989;**21**(6):331-3. [PubMed: [2606376](https://pubmed.ncbi.nlm.nih.gov/2606376/)].