

# Determinants of Pre-Operative Shoulder Imbalance in Patients with Adolescent Idiopathic Scoliosis

Hassan Ghandhari,<sup>1</sup> Saeed Sabbaghan,<sup>1</sup> Farshad Nikouei,<sup>1\*</sup> Farhad Rahbarian,<sup>1</sup> Hamed Tayebi,<sup>1</sup> and

Ebrahim Ameri<sup>1</sup>

<sup>1</sup>Bone and Joint Reconstruction Research Center, Shafa Orthopedic Hospital, Iran University of Medical Sciences, Tehran, Iran

\*Corresponding author: Farshad Nekoui, Bone and Joint Reconstruction Research Center, Shafa Orthopedic Hospital, Iran University of Medical Sciences, Tehran, Iran. Tel: +98-2133542000-8, Fax: +98-2133542020, E-mail: nekoui.far@gmail.com

Received 2016 November 06; Revised 2016 December 21; Accepted 2016 December 30.

## Abstract

**Background:** Disfiguring complications of adolescent idiopathic scoliosis (AIS) could significantly affect the patients' satisfaction. In this regard, shoulder imbalance has recently received much attention in spite of its poorly understood challenge.

**Objectives:** While the majority of previous studies have attempted to explore preoperative determinants of postoperative shoulder imbalance, in this study we aimed to investigate the factors correlated with the preoperative shoulder imbalance.

**Methods:** A total of 72 AIS patients with no previous history of corrective surgery took part in this study. The study sample comprised 63 females and 9 males with the mean age of  $15.72 \pm 3.08$  years, ranging from 11 to 26 years. Shoulder imbalance parameters including T1 tilt, first rib angle (FRA), and clavicle angle (CA) were assessed and their correlation with radiographic characteristics of the curves and patients' demographic data including age and sex was evaluated.

**Results:** T1 tilt was more severe in males (mean  $-8.2^\circ$ ) than females (mean  $-2.8^\circ$ ) ( $P = 0.04$ ). Moreover, a significant correlation was found between age and FRA ( $P = 0.04$ ). A significant correlation was also observed between main thoracic (MT) curve size and all the three parameters of shoulder imbalance ( $P < 0.001$ ). The reverse correlation of T5 - T12 kyphosis angle with FRA was also significant ( $P = 0.04$ ).

**Conclusions:** According to our results, in AIS, pre-operative radiographic shoulder imbalance could be affected by some curve parameters including MT and kyphosis size and demographic characteristics of patients including age and gender.

**Keywords:** Adolescent Idiopathic Scoliosis, Shoulder Imbalance, Pre-Operative Determinants

## 1. Background

Adolescent idiopathic scoliosis (AIS) is defined as a lateral curvature of the spine greater than 10 degrees accompanied by vertebral rotation with unknown etiology. It affects 2 to 4 percent of children aged 10 to 16 years. However, in only 10% of AIS cases the curve progresses to the point that treatment is warranted. In these patients, cosmetic considerations also significantly affect their satisfaction both before and after surgery (1, 2).

It is well acknowledged that the spinal deformity in scoliosis is only part of the complex body disfigurement which includes sagittal, coronal, and axial plane distortion of the chest wall, trunk, pelvis, shoulder, and neck (3). Among them, shoulder imbalance in AIS has recently received much attention in spite of its poorly understood challenge (2, 4). Determining the components of AIS which preoperatively affect the shoulder balance could help the better management of shoulder imbalance through preoperative and postoperative assessment of such parameters (3).

Several studies have investigated preoperative determinants of postoperative shoulder imbalance. Menon et al. evaluated the preoperative shoulder imbalance in AIS and reported that theoretically surgical balancing of the shoulder should not depend only on the stiffness and magnitude of proximal thoracic (PT) curve (2). Kuklo et al. also reported that the clavicle angle rather than T1 tilt, upright proximal thoracic, or side-bending proximal thoracic Cobb can provide the best preoperative prediction of postoperative shoulder imbalance (4). Hong et al. evaluated the factors affecting shoulder balance after corrective surgery in scoliosis and reported the significant correlations of correction rate of middle and distal curvature with postoperative shoulder balance. They also reported that preoperative shoulder level could be a determinant of postoperative shoulder balance (5).

## 2. Objectives

In spite of many previous studies that have attempted to show determinants of postoperative shoulder imbalance

ance, we aimed to evaluate the factors influencing preoperative shoulder imbalance regardless of postoperative results.

Despite the enormous advances in cross-sectional imaging over the past decades, radiography still remains as the mainstay of scoliosis evaluation (6). Consequently, we used radiographic parameters of the shoulder imbalance to explore their potential correlations with scoliosis curvatures. We also evaluated some demographic characteristics of the patients which could potentially affect the shoulder imbalance in AIS patients.

### 3. Methods

A total of 72 AIS patients who had been selected for corrective surgery took part in the present cross-sectional study. Over a 2-year period starting from 2013, the patients were evaluated for shoulder imbalance. The study was conducted on 63 females and 9 males with the mean age of  $15.72 \pm 3.08$  years, ranging from 11 to 26 years. The radiodemographic characteristics of patients have been demonstrated in Table 1 in detail.

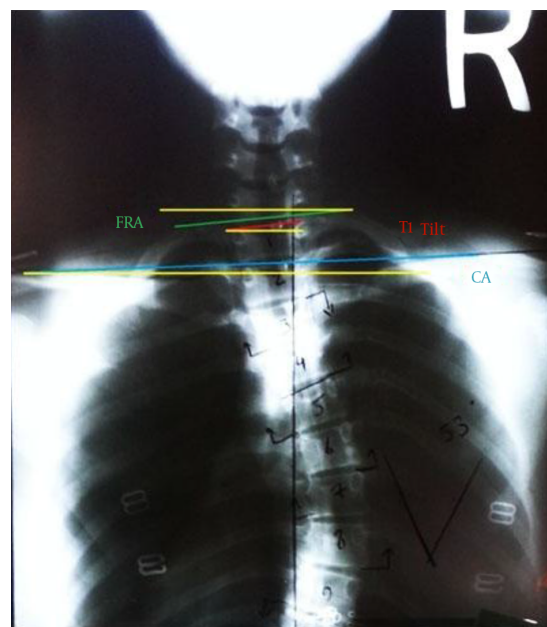
Our exclusion criteria included previous corrective surgery, left thoracic curve, and scoliosis of known origin including congenital disorders, cerebral palsy, etc. Whole spine standing postero-anterior (PA), lateral and supine side-bending radiographs were obtained and used for radiographic evaluations.

Three parameters of shoulder imbalance including T1 tilt, first rib angle (FRA), and clavicle angle (CA) were assessed. In this regard, T1 tilt was defined as tilting of cephalic endplate of T1, FRA as inclination of line through superior border of both first ribs, and CA as inclination of line between uppermost superior borders of both clavicles (7) (Figure 1).

A positive T1 tilt was correlated with the left proximal vertebral body up and right lower vertebral body down and a positive clavicle angle and first rib angle, like T1 tilt, were correlated with the left clavicle and first rib up and right side down (7).

Radiographic evaluation of the curves included the evaluation of proximal thoracic (PT) curve, main thoracic (MT) curve, and thoracolumbar/lumbar (TL/L) curve. Cobb angles were measured to quantify the magnitude of the curves (8). In addition, standard demographic data including sex and age were recorded for each patient. The curves were classified according to Lenke classification. Briefly, Lenke classification is composed of 3 components including curve type (Type 1 - 6), lumbar spine modifier (A, B, or C), and sagittal thoracic modifier (-, N,+)(9).

This study was approved by the ethics committee of our university and written consent was obtained from all



**Figure 1.** Schematic Drawing of Radiographic Parameters of Shoulder Imbalance Including Clavicle Angle (CA), T1 Tilt, and First Rib Angle (FRA)

the patients taking part in the study or their parents.

Unpaired T-test and ANOVA were used to analyze the significance of continuous variables such as radiographic parameters. Pearson correlation coefficients were used to assess the linear correlation between radiographic parameters. IBM SPSS Statistics 23 was used for all statistic analysis and  $P < 0.05$  was considered statistically significant.

### 4. Results

Mean values of PT, MT, and TL/L curve were  $20.50 \pm 10.82^\circ$ ,  $52.33 \pm 19.42^\circ$ , and  $38.00 \pm 15.04^\circ$ , respectively. The Mean kyphosis angle was  $39.70 \pm 16.52^\circ$ . Moreover, the mean values of T1 tilt, FRA, and CA were  $-3.54 \pm 7.55^\circ$ ,  $-3.52 \pm 7.22^\circ$ , and  $-2.12 \pm 3.88^\circ$ , respectively (Table 2).

Overall, 34 (47.2%) patients with lumbar modifier A, 13 with lumbar modifier B (18.1%), and 25 with lumbar modifier C (34.7%) were observed. Also, 3 patients with negative, 35 patients with normal, and 34 patients with positive sagittal thoracic modifier were identified in this study.

The MT curve was more severe in males (mean  $67.7^\circ$ ) than females (mean  $50.1$ ) ( $P = 0.03$ ), while no significant difference was observed in PT and TL/L curves based on gender. A significant correlation was also found between MT curve size and all the three parameters of shoulder imbalance ( $P < 0.001$ ). The strength of the correlation was  $-0.55$ ,  $-0.56$ , and  $-0.46$  for T1 tilt, CA and FRA, respectively. However,

**Table 1.** Patients' Radiographic and Demographic Characteristics

Parameter	Groups	No. %	Mean T1 Tilt <sup>o</sup>	Mean CA <sup>o</sup>	Mean FRA <sup>o</sup>
Gender	Male	9 (12.5)	-8.22	-3.77	-7.44
	Female	63 (87.5)	-2.87	-1.88	-2.96
Lenke type	1	32 (44.4)	-4.21	-2.15	-4.34
	2	17 (23.6)	-1.35	-2.29	-1.52
	3	7 (9.7)	-7.71	-6.00	-7.14
	4	4 (5.6)	-7.25	-2.75	-7.75
	5	8 (11.1)	+0.62	+0.75	+0.62
	6	4 (5.6)	-4.75	+0.50	-3.25
Lumbar modifier	A	34 (47.2)	-3.44	-2.29	-3.55
	B	13 (18.1)	-6.23	-2.92	-6.15
	C	25 (34.7)	-2.28	-1.48	-2.12
Sagittal thoracic modifier	Negative	3 (4.2)	-1.33	0.66	-1.33
	Normal	35 (48.6)	-4.91	-2.74	-5.20
	Positive	34 (47.2)	-2.32	-1.73	-2.00

<sup>o</sup>CA, clavicle angle; FRA; first rib angle.

**Table 2.** The Mean  $\pm$  SD of Radiographic Data of Shoulder Imbalance and Curve Parameters

Radiographic Measurements, <sup>o</sup>	Mean $\pm$ SD	Range
Cobb-PT	20.50 $\pm$ 10.82	0 - 44
Cobb-MT	52.33 $\pm$ 19.42	5 - 110
Cobb-TL/L	38.00 $\pm$ 15.04	4 - 78
Cobb-Kyphosis	39.70 $\pm$ 16.52	5 - 80
T1 tilt	-3.54 $\pm$ 7.55	-30 to 12
FRA	-3.52 $\pm$ 7.22	-30 to 10
CA	-2.12 $\pm$ 3.88	-10 to 8

<sup>o</sup>CA, Clavicle Angle; FRA, First Rib Angle; L, Lumbar; MT, Main Thoracic; PT, Proximal Thoracic; TL, Thoracolumbar.

the correlation of PT and TL/L curves with shoulder imbalance was not significant.

T1 tilt was more severe in males (mean -8.2<sup>o</sup>) than females (mean -2.8<sup>o</sup>) (P = 0.04). Nevertheless, gender did not significantly affect CA and FRA. In addition, a significant correlation between age and FRA (r = -0.23, P = 0.04) was noticed. In this regard, more severe FRA were seen in older patients. Even though, the correlation of age with other shoulder imbalance data including CA and T1 tilt was not significant.

The reverse correlation of T5 - T12 kyphosis angle with FRA was also significant (r = 0.23, P = 0.04). Moreover, pa-

tients with Lenke type 3 and 4 had more severe T1 tilt and FRA, although this difference was not statistically significant. Lumbar modifier and sagittal thoracic modifier did not show any significant correlation with shoulder imbalance parameters.

The results of the mean differences and correlation analysis have been demonstrated in [Tables 2 and 3](#).

## 5. Discussion

In spite of our rudimentary understanding of shoulder imbalance in AIS patients, the attachment of pelvic girdle to the spine through sacroiliac joint could understandably link the spine deformities to the corresponding tilts in pelvis. In addition, the pectoral girdle is indirectly connected to the spine through a series of articulated levers made of bone and joints. Scapula is also attached to the chest wall through the corresponding muscles. While the association of spinal deformity with shoulder imbalance is expected, the quality and quantity of this correlation remain to be resolved. In this regard, two aspects of this correlation attract more attention including how spinal deformity produces shoulder imbalance and how manipulation of the spine is translated into the realignment of the shoulder.

Kuklo et al. evaluated the correlation of postoperative shoulder balance with preoperative radiographic measurements in order to aid preoperative planning of the

**Table 3.** Statistical Analysis of Patients' Radiographic and Demographic Characteristics<sup>a</sup>

Value	PT (R and P Value)	MT (r and P Value)	Tl/L (r and P Value)	Kyphosis (r and P Value)	Age (r and P Value)	Sex (P Value)	Lumbar Modifier (P Value)	Lenke Curve Type
T1 tilt	-0.02	-0.55	-0.16	0.20	-0.22	Y <sup>b</sup>	Ω <sup>c</sup>	Ω <sup>c</sup>
	0.82	0.00 <sup>d</sup>	0.16	0.09	0.054	0.04 <sup>d</sup>	0.31	0.31
FRA	-0.06	-0.56	-0.13	0.23	-0.23	Y <sup>b</sup>	Ω	Ω <sup>c</sup>
	0.59	0.00 <sup>d</sup>	0.26	0.04 <sup>d</sup>	0.04 <sup>d</sup>	0.08	0.26	0.18
CA	-0.19	-0.46	-0.11	0.17	-0.15	Y <sup>b</sup>	Ω <sup>c</sup>	Ω <sup>c</sup>
	0.10	0.00 <sup>d</sup>	0.34	0.14	0.19	0.17	0.52	0.15

<sup>a</sup>No sign: Pearson test<sup>b</sup>Y: t test<sup>c</sup>Ω: ANOVA test<sup>d</sup>P < 0.05 is considered statistically significant

surgery. They reported that CA, rather than T1 tilt, up-right proximal thoracic, or side-bending proximal thoracic Cobb, provides the best preoperative radiographic prediction of postoperative shoulder imbalance (4). Winter reported that positive overcorrection of the lower thoracic curve beyond the spontaneous correctability of upper thoracic curve may lead to undesirable shoulder asymmetry (10). Hong et al. also analyzed the factors that could affect shoulder balance after surgical correction in scoliosis and concluded that patients with smaller preoperative shoulder imbalance show higher chance of aggravation after surgery, and preoperative shoulder level difference could be used as a determinant of postoperative shoulder balance (5). Furthermore, Namikava et al. assessed shoulder imbalance following posterior spinal fusion for thoracic AIS and reported that sufficient correction of PT curve, which is matched with the correction of MT curve, is necessary to prevent postoperative shoulder imbalance (11).

While the majority of previous studies have investigated the factors affecting postoperative shoulder imbalance, a limited number of investigations including our study have been assigned to explore the potential factors which could affect shoulder imbalance before surgical correction of the spine.

Menon et al. evaluated the patterns of preoperative shoulder imbalance in AIS patients. They reported that preoperative shoulder level could be concordant or discordant with T1 tilt and the shoulder might be MT dependent or PT dependent. Therefore, they concluded that surgical balancing of the shoulder and upper instrumented vertebra placement should not only depend on the magnitude and stiffness of PT curve (2). However, the application of T1 tilt as a determinant of shoulder level has been demonstrated to less correlate with clinical picture than CA and

coracoids height difference (CHD) (4, 12-14).

According to our results, shoulder level was found to be correlated with both demographic and curve characteristics of AIS patients. In terms of demographic characteristics, we found a significant correlation between male gender and T1 tilt. In addition, FRA was also found to significantly be correlated with the age of the patients so that older patients showed more severe FRA. To the best of our knowledge, the correlation of demographic data of AIS patients with shoulder imbalance has not been previously evaluated and these data could help surgeons more accurately evaluate shoulder imbalance both pre- and post-operatively. However, some other demographic data including BMI and height of the patients could affect the shoulder level in AIS patients which need to be evaluated in future investigations.

On the other hand, a significant correlation between shoulder imbalance parameters and curvature type was also found in our study. In this regard, MT curve was found to be significantly correlated with three shoulder imbalance parameters. Moreover, Kyphosis angle was significantly reverse correlated with FRA.

Our study also encountered some preliminary limitations. For example, the unequal number of males and females, and the small number of subjects in some types of scoliosis (e.g. Lenke type 5) could be referred.

The present understanding of shoulder imbalance in AIS patients could help the physician and patients pre-evaluate the cosmetic complications of the disease and eventually prevent shoulder imbalance postoperatively. Prediction of high shoulder imbalance possibility in an AIS patient could lead to a more accurate strategy during surgery.

Considering the more significant correlation between MT curve and shoulder imbalance parameters, it could be

suggested that more attention be paid to the MT curve management in the AIS shoulder imbalance prediction and correction.

Inquiring a link between pre- and post-operative determinants of shoulder imbalance could be even more advantageous and is considered as our next mission, as several previous studies have shown the correlation of preoperative radiographic parameters with postoperative shoulder imbalance.

According to our results, T1 tilt was found to be significantly more severe in male AIS patients. In addition, more severe FRA was seen in older patients. Moreover, MT curve severity was significantly correlated with T1 tilt, FRA, and CA. Kyphosis angle significantly was correlated with FRA, as well. However, Lenke curve type and lumbar modifier had no significant effect on shoulder balance parameters.

## Footnotes

**Authors' Contribution:** Hassan Ghandhari, Design of study and drafting and revision of the manuscript; Saeed Sabbaghan, Acquisition of data and drafting and revision of the manuscript; Farshad Nikouei, Drafting, revision of the manuscript and interpretation of data; Farhad Rahbarian, Data analysis and drafting of the manuscript; Hamed Tayebi, Data acquisition and drafting and revision of the manuscript; Ebrahim Ameri, Design of study and drafting and revision of the manuscript.

**Conflict of interest:** None declared.

## References

1. Asher MA, Burton DC. Adolescent idiopathic scoliosis: natural history and long term treatment effects. *Scoliosis Spinal Disord.* 2006;**1**(1) doi: [10.1186/1748-7161-1-2](https://doi.org/10.1186/1748-7161-1-2).
2. Menon KV, Tahasildar N, Pillay HM, Anbuselvam M, Jayachandran RK. Patterns of shoulder imbalance in adolescent idiopathic scoliosis: a retrospective observational study. *J Spinal Disord Tech.* 2014;**27**(7):401-8. doi: [10.1097/BSD.0000000000000166](https://doi.org/10.1097/BSD.0000000000000166). [PubMed: [25144206](https://pubmed.ncbi.nlm.nih.gov/25144206/)].
3. Qiu XS, Ma WW, Li WG, Wang B, Yu Y, Zhu ZZ, et al. Discrepancy between radiographic shoulder balance and cosmetic shoulder balance in adolescent idiopathic scoliosis patients with double thoracic curve. *Eur Spine J.* 2009;**18**(1):45-51. doi: [10.1007/s00586-008-0833-4](https://doi.org/10.1007/s00586-008-0833-4). [PubMed: [19043746](https://pubmed.ncbi.nlm.nih.gov/19043746/)].
4. Kuklo TR, Lenke LG, Graham EJ, Won DS, Sweet FA, Blanke KM, et al. Correlation of radiographic, clinical, and patient assessment of shoulder balance following fusion versus nonfusion of the proximal thoracic curve in adolescent idiopathic scoliosis. *Spine (Phila Pa 1976).* 2002;**27**(18):2013-20. [PubMed: [12634561](https://pubmed.ncbi.nlm.nih.gov/12634561/)].
5. Hong JY, Suh SW, Modi HN, Yang JH, Park SY. Analysis of factors that affect shoulder balance after correction surgery in scoliosis: a global analysis of all the curvature types. *Eur Spine J.* 2013;**22**(6):1273-85. doi: [10.1007/s00586-013-2697-5](https://doi.org/10.1007/s00586-013-2697-5). [PubMed: [23455950](https://pubmed.ncbi.nlm.nih.gov/23455950/)].
6. Malfair D, Flemming AK, Dvorak MF, Munk PL, Vertinsky AT, Heran MK, et al. Radiographic evaluation of scoliosis: review. *AJR Am J Roentgenol.* 2010;**194**(3 Suppl):S8-22. doi: [10.2214/AJR.07.7145](https://doi.org/10.2214/AJR.07.7145). [PubMed: [20173177](https://pubmed.ncbi.nlm.nih.gov/20173177/)].
7. Bagó J, Carrera L, March B, Villanueva C. Four Radiological Measures to Estimate Shoulder Balance in Scoliosis. *Journal of Pediatric Orthopaedics B.* 1996;**5**(1):31-4. doi: [10.1097/01202412-199605010-00006](https://doi.org/10.1097/01202412-199605010-00006).
8. Kundu R, Chakrabarti A, Lenka PK. Cobb angle measurement of scoliosis with reduced variability. *arXiv preprint arXiv:1211.5355.* 2012.
9. Lenke LG, Edwards C2, Bridwell KH. The Lenke classification of adolescent idiopathic scoliosis: how it organizes curve patterns as a template to perform selective fusions of the spine. *Spine (Phila Pa 1976).* 2003;**28**(20):199-207. doi: [10.1097/01.BRS.0000092216.16155.33](https://doi.org/10.1097/01.BRS.0000092216.16155.33). [PubMed: [14560193](https://pubmed.ncbi.nlm.nih.gov/14560193/)].
10. Winter RB. The idiopathic double thoracic curve pattern. Its recognition and surgical management. *Spine (Phila Pa 1976).* 1989;**14**(12):1287-92. [PubMed: [2694387](https://pubmed.ncbi.nlm.nih.gov/2694387/)].
11. Namikawa T, Matsumura A, Kato M, Hayashi K, Nakamura H. Radiological assessment of shoulder balance following posterior spinal fusion for thoracic adolescent idiopathic scoliosis. *Scoliosis.* 2015;**10**(Suppl 2):18. doi: [10.1186/1748-7161-10-S2-S18](https://doi.org/10.1186/1748-7161-10-S2-S18). [PubMed: [25815056](https://pubmed.ncbi.nlm.nih.gov/25815056/)].
12. Lee CK, Denis F, Winter RB, Lonstein JE. Analysis of the upper thoracic curve in surgically treated idiopathic scoliosis. A new concept of the double thoracic curve pattern. *Spine (Phila Pa 1976).* 1993;**18**(12):1599-608. [PubMed: [8235838](https://pubmed.ncbi.nlm.nih.gov/8235838/)].
13. Iwahara T, Imai M, Atsuta Y. Quantification of cosmesis for patients affected by adolescent idiopathic scoliosis. *Eur Spine J.* 1998;**7**(1):12-5. doi: [10.1007/s005860050020](https://doi.org/10.1007/s005860050020). [PubMed: [9548352](https://pubmed.ncbi.nlm.nih.gov/9548352/)].
14. Ono T, Bastrom TP, Newton PO. Defining 2 components of shoulder imbalance: clavicle tilt and trapezial prominence. *Spine (Phila Pa 1976).* 2012;**37**(24):1511-6. doi: [10.1097/BRS.0b013e31826e2bbb](https://doi.org/10.1097/BRS.0b013e31826e2bbb). [PubMed: [22895482](https://pubmed.ncbi.nlm.nih.gov/22895482/)].