






# Research Article:

## Sagittal Alignment Following the Kyphoplasty of Acute Versus Chronic Osteoporotic Vertebral Compression Fracture



Farshad Nikouei , Hasan Ghandhari , Mohammadamin Haghbin , Omid Momen , Amir Aghaie Aghdam 

1. Bone and Joint Reconstruction Research Center; Shafa Orthopedic Hospital, Iran University of Medical Sciences, Tehran, Iran.



**Citation** Nikouei F, Ghandhari H, Haghbin MA, Momen O, Aghaie Aghdam A. Sagittal Alignment Following the Kyphoplasty of Acute Versus Chronic Osteoporotic Vertebral Compression Fracture. Journal of Research in Orthopedic Science. 2019; 6(3):1-6. <http://dx.doi.org/10.32598/JROSJ.6.3.1>

 <http://dx.doi.org/10.32598/JROSJ.6.3.1>



### Article info:

**Received:** 02 Mar 2019

**Revised:** 26 Apr 2019

**Accepted:** 12 Jul 2019

**Available Online:** 01 Aug 2019

### Keywords:

Kyphoplasty,  
Osteoporosis, Vertebral  
compression fracture,  
Sagittal alignment

## ABSTRACT

**Background:** As a minimally invasive operation, kyphoplasty has become popular in the treatment of Osteoporotic Vertebral Compression Fracture (OVCF).

**Objectives:** This study aimed to evaluate how the timing of kyphoplasty affects the parameters of sagittal alignment in OVCF.

**Methods:** In this prospective study, the patients with OVCF, who underwent kyphoplasty at our center, were recruited. Pre- and post-operative vertebral height, local and total kyphosis, coronal axis, sagittal vertebral axis, pelvic tilt, lumbar lordosis, sacral slope, and spino-cranial angle were evaluated and compared between acute OVCF (kyphoplasty performed within 1 month after injury) and chronic OVCF (kyphoplasty performed after 1 month from injury) patients.

**Results:** Kyphoplasty was done for 18 acute and 28 chronic OVCF patients. All of the evaluated parameters, except spino-cranial angle, were significantly improved after the kyphoplasty. A significant difference was observed between the mean lumbar lordosis improvement of the two groups ( $P=0.026$ ). In particular, the Mean $\pm$ SD lumbar lordosis improved  $6.1\pm 6.6^\circ$  in the acute patients and  $0.92\pm 7.86^\circ$  in the chronic group. No other significant difference was observed between the improvement of the spinopelvic parameters in the two groups.

**Conclusion:** The timing of kyphoplasty impacts the improvement of spinopelvic parameters, as well as the reduction of pain and restoration of vertebral height.

## 1. Introduction

**O**steoporotic Vertebral Compression Fracture (OVCF) is the most common complication of osteoporosis and significantly impacts

the quality of life of the affected population [1, 2]. Acute back pain is the primary manifestation of OVCF. The treatment of OVCF is mainly focused on the reduction of pain and management of the osteoporosis [3].

### \* Corresponding Author:

Omid Momen, PhD.

**Address:** Bone and Joint Reconstruction Research Center; Shafa Orthopedic Hospital, Iran University of Medical Sciences, Tehran, Iran.

**Phone:** +98 (21) 33542000

**E-mail:** dromid.momen@yahoo.com

Optimal sagittal alignment is essential for spinal biomechanical efficiency, as it reduces the energy expenditure by preserving a stable posture with improved load absorption. For this reason, the restoration of sagittal balance is one of the determining factors in the success of the therapeutic intervention of the spine [4-6].

Local and global kyphosis in OVCF can change the sagittal spinal alignment, causing sagittal imbalance [7]. This condition exacerbates the pain and disability, which the patient is experiencing [4]. Thus, the restoration of sagittal balance is an essential part of OVCF treatment.

Kyphoplasty (percutaneous vertebral augmentation), as minimally invasive surgery, has become popular in the treatment of OVCF, as it dramatically relieves the fracture-associated pain and also restores the height of the vertebrae through the injection of the cement into the fractured vertebrae [8]. Kyphoplasty has also been found to improve the sagittal imbalance in the treatment of painful OVCF [9, 10]. However, researchers less investigated the impact of kyphoplasty on the correction of sagittal imbalance in OVCF patients.

Multidisciplinary conservative management is considered an essential primary means of treatment and mainly comprised bed rest, osteoporosis medication, brace immobilization, and physical rehabilitation [11]. However, there is no standard timing for appropriate conservative management and programs of 4-10 weeks have been suggested [12]. On the other hand, timing has been shown to matter in performing kyphoplasty, and the clinical and

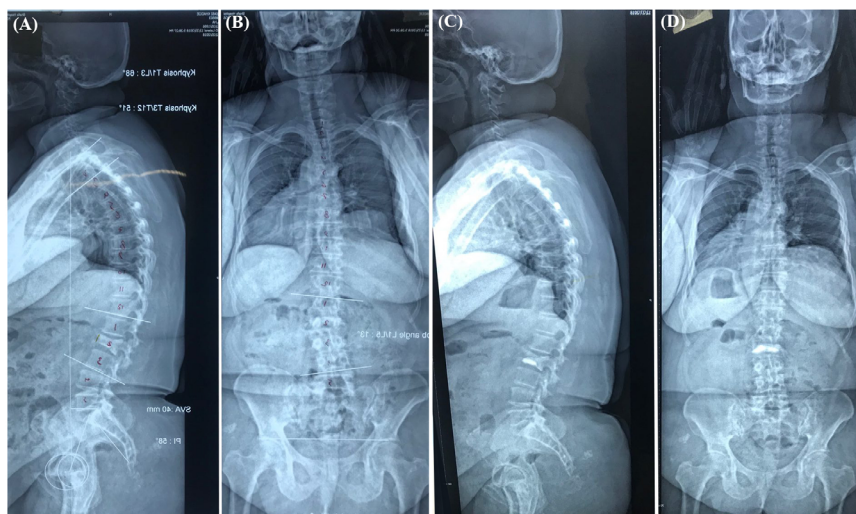
radiological outcomes have been mostly better in acute fractures than in chronic fractures [13]. However, to the best of our knowledge, no study has ever evaluated the effect of timing of kyphoplasty on the spinopelvic parameters of the spine.

In the present study, we aimed at evaluating the impact of kyphoplasty on the sagittal alignment of OVCF patients, as well as finding how its timing affects the parameters of sagittal alignment.

## 2. Methods

The review board of our institute approved the study, the patients before their participation gave their written consent. In the current prospective study, OVCF patients were recruited. They were referred to our center between January 2016 and June 2018 and underwent kyphoplasty. The patients with the history of spinal surgery and those with spinal deformities other than present condition were excluded from the study.

One senior surgeon performed all operations under the local anesthesia and cardiopulmonary monitoring. Kyphoplasty was performed on the prone position and through a transpedicular route on each side. After the inflation and deflation of the kyphoplasty balloon, poly(Methyl Methacrylate) (PMMA) mixture was injected into the affected vertebral body from both sides. The injection was monitored with a C-arm fluoroscopy unit.



**Figure 1.** Preoperative lateral

A: Anteroposterior; B: Standing full-length alignment radiographs showing the osteoporotic vertebral compression fracture of L1 vertebra; Post-kyphoplasty lateral; C: Anteroposterior; D: Standing full-length alignment radiographs of the corresponding patients

**Table 1.** Comparison of the preoperative and postoperative spinopelvic parameters of the OVCF patients (n=46)

Variable	Mean±SD/ No. (%)		P
	Preoperative	Postoperative	
Total kyphosis (°)	50.5±11.5	48.7±9.5	<0.001
Local kyphosis (°)	23.6±13.1	12.2±11.2	<0.001
SVA (mm)	25±15.1	13.8±11.7	<0.001
PT (°)	27.7±7.9	24.2±6.4	<0.001
LL (°)	44.5±14.7	47.5±15.1	0.013
SS (°)	30±8.5	33±7	<0.001
SCA (°)	54.3±10.8	55.1±8.7	0.37
Coronal axis (mm)	7.5±6.5	4.1±7.5	0.002
Vertebral height (%)	38.3±15.1	69.7±13.8	<0.001

Journal of Research in  
*Orthopedic Science*

OVCF: Osteoporotic Vertebral Compression Fracture; SVA: Sagittal Vertebral Axis; PT: Pelvic Tilt; LL: Lumbar Lordosis; SS: Sacral Slope; SCA: Spino-cranial Angle

P<0.05 is considered significant

Before and after the operation, anteroposterior and lateral standing full-length alignment radiographs were obtained for all patients (Figure 1); they were used for the evaluation of the parameters of sagittal balance, including vertebral height, local and total kyphosis, coro-

nal axis, Sagittal Vertebral Axis (SVA), Pelvic Tilt (PT), Lumbar Lordosis (LL), Sacral Slope (SS), and Spino-cranial Angle (SCA). The evaluated parameters were, then, compared between the two groups of the patients; group A: acute OVCF (patients for whom the kyphoplas-

**Table 2.** Comparison of the postoperative improvement of spinopelvic parameters of the OVCF patients (n=28)

Variable	Mean±SD/ No. (%)		P
	Group A	Group B	
Total kyphosis change (°)	10.4±7.6	10.8±6.5	0.83
Local kyphosis change (°)	10±9.6	10.7±9	0.79
SVA change (mm)	10.8±14.1	11.3±7.2	0.85
PT change (°)	3.5±4.8	3.5±4.9	0.98
LL change (°)	6.1±6.6	0.92±7.8	0.026
SS change (°)	1.9±5.1	3.5±4.9	0.29
SCA change (°)	0.83±7.4	0.85±5.9	0.9
Vertebral height change (%)	34.7±11.5	29.4±10.6	0.11
Coronal axis change (mm)	3.38±10.4	3.39±3.8	0.9

Journal of Research in  
*Orthopedic Science*

Group A: operation performed at <1 month after the injury; Group B: operation performed at >1 month after the injury

P<0.05 is considered significant

ty was performed  $\leq 1$  month after the injury) and group B: chronic OVCF (patients for whom the kyphoplasty was performed  $> 1$  month after the injury) patients.

### Statistical analysis

All statistical analyses were performed in SPSS V. 16. The results of descriptive statistics were presented as Mean $\pm$ SD or number and percentage. The paired t-test was used to compare (pre and post)operative parameters in each patient. The Independent t test was used for the comparison of spinal parameters between the two groups. The Pearson correlation coefficient or Spearman's rank correlation coefficient test was used for the evaluation of potential correlations. P-value of less than 0.05 was considered significant.

### 3. Results

A total of 46 OVCF patients, including 34(73.9%) females and 12(26.1%) males, were evaluated in this study. The Mean $\pm$ SD age of the patients was 69.3 $\pm$ 11.1 (range: 38-87 years). The Mean $\pm$ SD time from injury to operation was 80.4 $\pm$ 81 days (range: 3-360 days). All spinopelvic parameters of the patients except SCA were significantly improved after the kyphoplasty (Table 1).

Kyphoplasty was performed at the acute phase of the injury for 18 patients (group A) and at the chronic phase of the disease for 28 patients (group B). The Mean $\pm$ SD time from injury to operation was 22 $\pm$ 10 days in group A and 118 $\pm$ 84 days in group B. L1, L2, and T12 vertebrae were the most common sites of fracture in both groups. Multiple vertebral fractures were found in five cases of group A and four cases of group B.

The mean scores of improvement in total and local kyphosis were not significantly different between the two groups (P=0.83 and P=0.79, respectively). No significant difference was observed between the mean scores of improvement in SVA, PT, SS, SCA, vertebral height, and the coronal axis of the two groups, as well (P=0.85, P=0.98, P=0.29, P=0.9, P=0.11, and P=0.9, respectively). Meanwhile, a significant difference was observed between the mean value of LL improvement between the two groups (P=0.026). While the Mean $\pm$ SD value of LL improved to 6.1 $\pm$ 6.6 $^\circ$  in group A and 0.92 $\pm$ 7.86 $^\circ$  in group B. Table 2 presents the spinopelvic parameters of the two groups.

A significant positive correlation was found between vertebral height restoration and SVA correction (r=0.315, P=0.033), as well as total kyphosis improve-

ment (r=0.300, P=0.043). SVA was significantly correlated with total kyphosis correction (r=0.410, P=0.005), local kyphosis correction (r=0.370, P=0.011), and coronal axis realignment (r=0.581, P<0.001). Coronal axis change was positively consistent with total and local kyphosis improvement (r=0.387, P=0.008, and r=0.380, P=0.009, respectively). No other significant correlation was found between the evaluated parameters.

### 4. Discussion

Kyphoplasty dramatically relieves the fracture-associated pain and improves local kyphosis in OVCF patients [8, 14]. Recently, it has been shown that kyphoplasty not only plays a role in reducing pain but also improves the sagittal imbalance in the treatment of painful OVCF [9, 10]. However, as kyphoplasty is an almost new technique, many aspects of its implication are not well-known, and further optimizations are needed to make the most of this valuable procedure. Among them, the timing of kyphoplasty is a matter of debate.

In this study, we aimed at finding how kyphoplasty affects the sagittal alignment of OVCF patients. Moreover, we aimed at investigating how the timing of kyphoplasty affected the spinopelvic parameters of sagittal alignment. In this respect, we divided the patients into two groups of acute and chronic patients based on the time of kyphoplasty before the injury or One month after the injury. According to our results, all spinopelvic parameters except SVA improved following the kyphoplasty. LL improvement was significantly more in acute OVCF. No other significant difference was observed between the spinopelvic parameters of the two groups after the kyphoplasty.

Many investigations have shown the impact of kyphoplasty on the pain relief of OVCF patients [8, 14-17]. However, the effect of kyphoplasty on the sagittal imbalance of OVCF patients has been less studied. Kanayama et al. evaluated the effect of balloon kyphoplasty on the global spinal alignment in 46 OVCF patients. Based on their results, although kyphoplasty contributed to immediate pain relief, it did not improve the global sagittal spinal alignment. Accordingly, they concluded that kyphoplasty should be solely indicated for painful OVCF or non-union and not to restore sagittal alignment [10].

Yokoyama et al. analyzed the alterations in total spinal alignment after kyphoplasty in 21 OVCF patients. After kyphoplasty, a significant reduction in SVA and a considerable increase in LL and SSA were observed in their patients, showing a shift towards anterior sagittal balance. Based on these observations, they concluded

that kyphoplasty had a significant role in improving the sagittal imbalance in addition to pain relief in OVCF patients [9]. Similar to Yokoyama et al. study, the majority of spinopelvic parameters improved, following the kyphoplasty of OVCF patients in the current research.

Crandall et al. compared the impact of kyphoplasty on reducing pain and restoring vertebral body height in acute (less than 10 weeks from the injury) versus chronic (more than four months from the injury) OVCF patients. While Oswestry Disability Index (ODI) showed improvements in almost all patients, vertebral body height improved more in the acute group. Moreover, vertebral height loss occurred in (8%) of the acute fractures and (20%) of the chronic fractures after the kyphoplasty. Accordingly, they concluded that acute OVCF would benefit more from the kyphoplasty [18].

Erkan et al. also compared the clinical and radiologic outcomes, as well as the complication rates of symptomatic acute (<10 weeks from the injury) and chronic (>16 weeks after the injury) OVCF patients treated with kyphoplasty. Based on their results, the Oswestry Disability Index, visual analog scale, patients' satisfaction scale, and medication usage significantly showed improvements in both groups. However, these improvements were greater in the acute group. Furthermore, vertebral height, local kyphosis angle, and dynamic fracture mobility significantly improved in both groups, and again more in the acute group. However, global sagittal alignment was not significantly different between the study groups. Based on these results, they concluded that the timing of kyphoplasty was essential, as the clinical and radiological outcomes were mostly better in acute OVCF than in chronic OVCF [13].

To the best of our knowledge, no study has evaluated the effect of kyphoplasty timing on the spinopelvic parameters of sagittal alignment. The results of this study revealed that the timing of kyphoplasty affected the improvement of spinopelvic parameters, as well as the reduction of pain and restoration of vertebral height. In this regard, the LL improvement was significantly greater in the acute OVCF compared with the chronic OVCF.

The present study had some limitations. First of all, the small size of the sample, particularly in the acute group, might have affected the power of statistical analyses and could be regarded as the main limitation of this study. Moreover, the timing of kyphoplasty was heterogeneous so that it ranged from 3-30 days in the acute group and 60-360 days in the chronic group. Thus, future controlled studies are required to fully elucidate the importance of

kyphoplasty timing on the spinopelvic parameters of the spine in OVCF patients.

## Ethical Considerations

### Compliance with ethical guidelines

This study was approved by the Ethics Committee of Bone and Joint Reconstruction Research Center, Iran University of Medical Sciences, Tehran.

### Funding

This research did not receive any specific grant from funding agencies in the public, commercial, or not-for-profit sectors.

### Authors' contributions

Design and concept of the study: Farshad Nikouei, Hasan Ghandhari; Drafting the manuscript: Mohammadamin Haghbin; Data collection: Omid Momen; Statistical analysis and interpretation of the results: Amir Aghaie Aghdam.

### Conflict of interest

The authors declared no conflict of interest.

## References

- [1] Iizuka S, Masafumi M, Shioda M, Takemitsu M, Kaneko S, Yagi M, et al. Osteoporotic vertebral compression fracture. *IRYO- Jpn J Natl Med Ser.* 2012; 66(12):709-17.
- [2] Ghandhari H, Ameri E, Aghamohammadi J, Zabihyeganeh M. Predictors of kyphosis progression after the conservative treatment of osteoporotic vertebral compression fracture. *Shafa Orthop J.* 2018 (In Press). [DOI:10.5812/soj.70736]
- [3] Bednar T, Heyde CE, Bednar G, Nguyen D, Volpi E, Przkora R. Kyphoplasty for vertebral augmentation in the elderly with osteoporotic vertebral compression fractures: Scenarios and review of recent studies. *Clin Ther.* 2013; 35(11):1721-7. [DOI:10.1016/j.clinthera.2013.09.016] [PMID] [PMCID]
- [4] Makhni MC, Shillingford JN, Laratta JL, Hyun SJ, Kim YJ. Restoration of sagittal balance in spinal deformity surgery. *J Korean Neurosurg Soc.* 2018; 61(2):167-79. [DOI:10.3340/jkns.2017.0404.013] [PMID] [PMCID]
- [5] Samadian M, Hosseinzadeh Bakhtevari M, Jahangiri Babadi A, Nabizadeh N, Rezaei O. Congenital posterior spinal agenesis leads to L2-L3 instability: A case report and review of the literature. *Arch Iran Med.* 2015; 18(12):861-4. [DOI:0151812/AIM.0013] [PMID]
- [6] Ameri E, Ghandhari H, Hesarikia H, Rasouli HR, Vahid-tari H, Nabizadeh N. Comparison of Harrington rod and



- cotrel-dubousset devices in surgical correction of adolescent idiopathic scoliosis. *Trauma Mon.* 2013; 18(3):134-8. [DOI:10.5812/traumamon.14663] [PMID] [PMCID]
- [7] Zhang YL, Shi LT, Tang PF, Sun ZJ, Wang YH. Correlation analysis of osteoporotic vertebral compression fractures and spinal sagittal imbalance. *Der Orthopäde.* 2017; 46(3):249-55. [DOI:10.1007/s00132-016-3359-1] [PMID]
- [8] Garfin SR, Yuan HA, Reiley MA. New technologies in spine: Kyphoplasty and vertebroplasty for the treatment of painful osteoporotic compression fractures. *Spine.* 2001; 26(14):1511-5. [DOI:10.1097/00007632-200107150-00002] [PMID]
- [9] Yokoyama K, Kawanishi M, Yamada M, Tanaka H, Ito Y, Kawabata S, et al. Postoperative change in sagittal balance after Kyphoplasty for the treatment of osteoporotic vertebral compression fracture. *Eur Spine J.* 2015; 24(4):744-9. [DOI:10.1007/s00586-014-3678-z] [PMID]
- [10] Kanayama M, Oha F, Iwata A, Hashimoto T. Does balloon kyphoplasty improve the global spinal alignment in osteoporotic vertebral fracture? *Int Orthop.* 2015; 39(6):1137-43. [DOI:10.1007/s00264-015-2737-3] [PMID]
- [11] Shah S, Goregaonkar AB. Conservative management of osteoporotic vertebral fractures: A prospective study of thirty patients. *Cureus.* 2016; 8(3):e542. [DOI:10.7759/cureus.542]
- [12] Wong CC, McGirt MJ. Vertebral compression fractures: A review of current management and multimodal therapy. *J Multidiscip Healthc.* 2013; 6:205-14. [DOI:10.2147/JMDH.S31659] [PMID] [PMCID]
- [13] Erkan S, Ozalp TR, Yercan HS, Okcu G. Does timing matter in performing kyphoplasty? Acute versus chronic compression fractures. *Acta Orthop Belg.* 2009; 75(3):396-404. [PMID]
- [14] Lieberman I, Dudeny S, Reinhardt MK, Bell G. Initial outcome and efficacy of "kyphoplasty" in the treatment of painful osteoporotic vertebral compression fractures. *Spine.* 2001; 26(14):1631-7. [DOI:10.1097/00007632-200107150-00026] [PMID]
- [15] Ledlie JT, Renfro M. Balloon kyphoplasty: One-year outcomes in vertebral body height restoration, chronic pain, and activity levels. *J Neurosurg.* 2003; 98(1):36-42. [DOI:10.3171/spi.2003.98.1.0036] [PMID]
- [16] Gill JB, Kuper M, Chin PC, Zhang Y, Schutt Jr R. Comparing pain reduction following kyphoplasty and vertebroplasty for osteoporotic vertebral compression fractures. *Pain Physician.* 2007; 10(4):583-90. [PMID]
- [17] Grafe IA, Da Fonseca K, Hillmeier J, Meeder PJ, Libicher M, Nöldge G, et al. Reduction of pain and fracture incidence after kyphoplasty: 1-Year outcomes of a prospective controlled trial of patients with primary osteoporosis. *Osteoporos Int.* 2005; 16(12):2005-12. [DOI:10.1007/s00198-005-1982-5] [PMID]
- [18] Crandall D, Slaughter D, Hankins P, Moore C, Jerman J. Acute versus chronic vertebral compression fractures treated with kyphoplasty: Early results. *Spine J.* 2004; 4(4):418-24. [DOI:10.1016/j.spinee.2004.01.003] [PMID]