

A Hydatid Cyst of the Lumbar Spine: A Rare Cause of Paraplegia

Suhail Ur Rehman,¹ Noora Saeed,^{1,*} Saima Khan,¹ and Shaista M Vasenwala¹

¹Department of Pathology, JNMC, AMU, Aligarh, U.P, India

*Corresponding author: Noora Saeed, Department of pathology, JNMC, AMU, Aligarh, U.P, India. Tel: +91- 9997240844, E-mail: dr.noorasaeed@gmail.com

Received 2017 January 12; Revised 2017 February 28; Accepted 2017 March 03.

Abstract

Introduction: Hydatid cyst is a zoonotic disease, affecting humans and other mammals worldwide. It is caused by tapeworms of the genus *Echinococcus*, which is most frequently encountered in the liver and lungs. Although involvement of the central nervous system and spine is rare, it can lead to severe neurological deficits due to direct compression.

Case Presentation: We report a case of intradural extramedullary hydatid cyst in the lumbar region with a sudden onset, causing progressive paraplegia and areflexia over the past 20 days. After surgical removal, the cyst was sent for histopathological examination. The results showed inner laminated membranes and an outer fibrous layer, surrounded by foreign-body giant cells. The primary objective during surgery was to avoid perforation of the cyst, thereby reducing the risk of systemic dissemination and local seeding of the parasite. During the postoperative period, there was a steady improvement in the neurological deficit, and the patient was discharged with anthelmintics to prevent any distant dissemination.

Conclusions: An accurate and precise diagnosis is necessary when dealing with cystic pathologies.

Keywords: Hydatid Cyst, Spine, Histopathology

1. Introduction

Hydatid disease or hydatidosis is a term of Greek roots, referring to watery cysts. It is caused by the parasite, *Echinococcus granulosus* (dog tapeworm). There are 2 main types of *Echinococcus* infections, caused by *E. granulosus* and *E. multilocularis*. The most common form in humans is caused by *E. granulosus*. Infestation with larval stages of dog tapeworms can result in encystation in various organs. The commonly involved organs include the liver (75%) and lungs (15%), while the remaining 10% occurs in other body organs (1).

Primary spinal hydatid cyst is rarely encountered, accounting for less than 1% of all cases of hydatid disease, which most commonly involves the dorsal spinal column. Cervical, lumbar, and sacral involvement is rarely reported (2). In this regard, Kammere et al. revealed that hydatid cysts of the central nervous system comprise 3% of all cases of hydatid cysts, and more than 50% of these cases are localized in the spinal system (3). The clinical features manifest due to the compression of the roots and cord.

Histopathological examination of hydatid cysts is confirmatory and shows laminated membranes, which are eosinophilic (Hematoxylin and Eosin staining) and are characterized by the presence of inflammatory cells in the cyst wall. The seepage of fluid causes inflammatory reactions or granulomatous inflammation with histiocytes and giant cells, supporting the diagnosis of hydatidosis (4). Surgery remains the mainstay of treatment with the

primary principles, including cyst excision without disrupting the cyst integrity as to avoid rupture and formation of multiple cysts.

2. Case Presentation

A 20-year-old boy with unremarkable medical history presented to Jawaharlal Nehru Medical College, Aligarh, India, experiencing back pain and sudden onset of paraplegia in both lower limbs over the past 20 days. During the neurological examination, the patient had marked hypotonia with pain while applying pressure on the L3-L4 spinal segment. There was numbness and weakness in the lower limbs with complete loss of tone, power, and sensations. The power grade in both lower limbs was 1/5; tendon reflexes were absent. The patient's biochemical and hematological profiles were within the normal range. However, serological test (Casoni test), which can suggest hydatid cysts, was not performed.

The lumbosacral T2W sagittal magnetic resonance imaging (MRI) showed oval-shaped cystic lesions with regular contours in the dorsal extradural space at L1 and L3-4 vertebral levels, causing conus medullaris compression at L1 level (Figure 1). Laminectomy was performed with favorable outcomes, and the cyst was sent for histopathological evaluation. The gross examination showed multiple whitish thin-walled cystic membranes, measuring 3 × 2 × 1.5 cm.

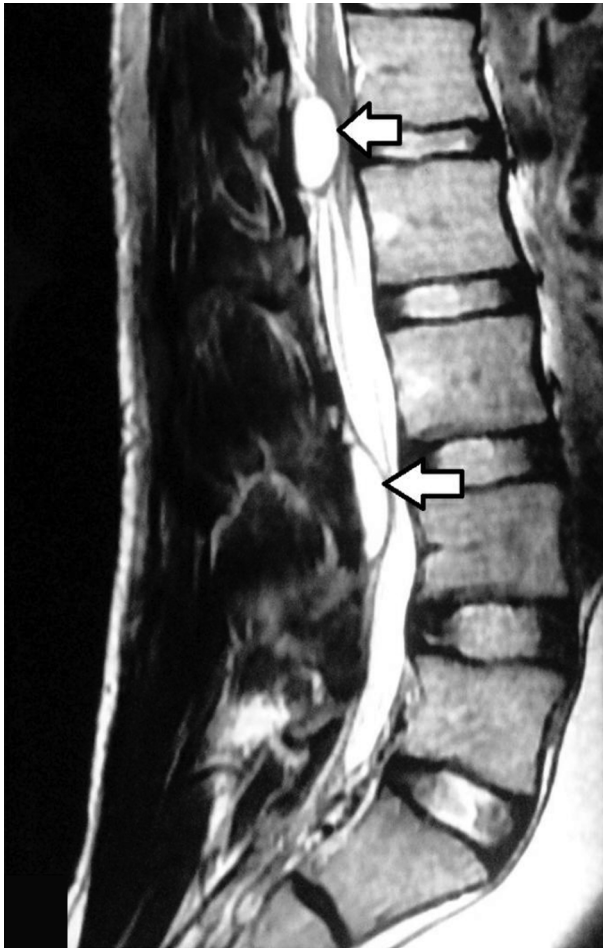


Figure 1. Lumbosacral T2W Sagittal MRI Showing 2 Oval-Shaped Cystic Lesions (Arrows) with Regular Contours in the Dorsal Extradural Space at L1 and L3-4 Vertebral Levels, Causing Conus Medullaris Compression at L1 level

Microscopically, multiple small cysts with an outer fibrous layer and inner laminated eosinophilic material were detected. The cysts were lined by foreign-body giant cells, showing chronic inflammatory cell infiltrate, hemorrhage, and necrosis with foci of calcification (Figure 2A and B). The lesion had excessively compressed the dural sac and caudal roots and expanded to the L3 and L4 neural foramina. The case was explored with L2-L3-L4 laminectomy, and the hydatid cyst was completely removed.

Following enucleation of the hydatid cyst without rupturing the cyst wall, the patient experienced dramatic improvement with regain of lost reflexes, power, and tone in the lower extremities. The patient was discharged with albendazole (400 mg twice a day for 1 year) to prevent any dissemination. He was advised strict periodic postoperative follow-ups with regular MRI scans. During the 1-year

follow-up, repeated clinical, radiological, and serological examinations did not show any evidence of systemic hydatidosis.

The present study was approved by the ethics board of our institution, and a written consent was obtained from the patient to report the study.

3. Discussion

Hydatid disease is the most widespread human cestode infection in the world. In this serious parasitic infection, humans are incidental hosts and acquire the disease as a result of fecal-oral contamination either directly by ingesting the parasite eggs through contact with dogs or indirectly through consuming contaminated water or food (5).

Hydatid cyst involving the spine is a rare finding. Braithwaite and Lees (6) categorized spinal hydatid disease according to the occurrence site: type 1, primary intramedullary hydatid disease; type 2, intradural extradural hydatid cyst; type 3, extradural intraspinal hydatid cyst; type 4, hydatid disease of the vertebrae; and type 5, paravertebral hydatid disease. Overall, the first 3 types are uncommon. Also, intradural hydatid disease presents at younger age, compared to extradural lesions and more frequently presents as a single cyst. The present case was a multiple intradural extradural type, which presented at younger age. Similar cases of intradural extradural spinal hydatidosis have been also discussed by M. Ahmad et al., Lotfinia I et al., and Senol N. et al. (7-9).

There are various diseases and pathological conditions, which closely mimic spinal echinococcosis, thereby posing difficulty in diagnosis. The most important differential diagnosis in Indian population is tuberculosis of the spine, commonly known as Pott disease. However, the cystic nature of the lesion in hydatid disease, without sclerosis in the host bones, is typical. On the other hand, destructive and necrotic nature of the lesion, associated with damage to the disc surface, is common in Pott disease. Histopathological examination can differentiate these conditions.

The chance of misdiagnosis is higher in areas where both hydatidosis and tuberculosis are endemic (10, 11). Other conditions, such as arachnoid cyst, pyogenic infection, mycosis, and spinal abscess, require proper evaluation, as they can closely mimic spinal hydatid cyst. Arachnoid cysts occur as single or multiple cysts and are frequently extradural. However, they can be easily ruled out, given the decreased inflammatory response on histopathological examination. In the present case, abundant inflammatory responses and giant-cell reactions were reported, thereby ruling out the diagnosis of

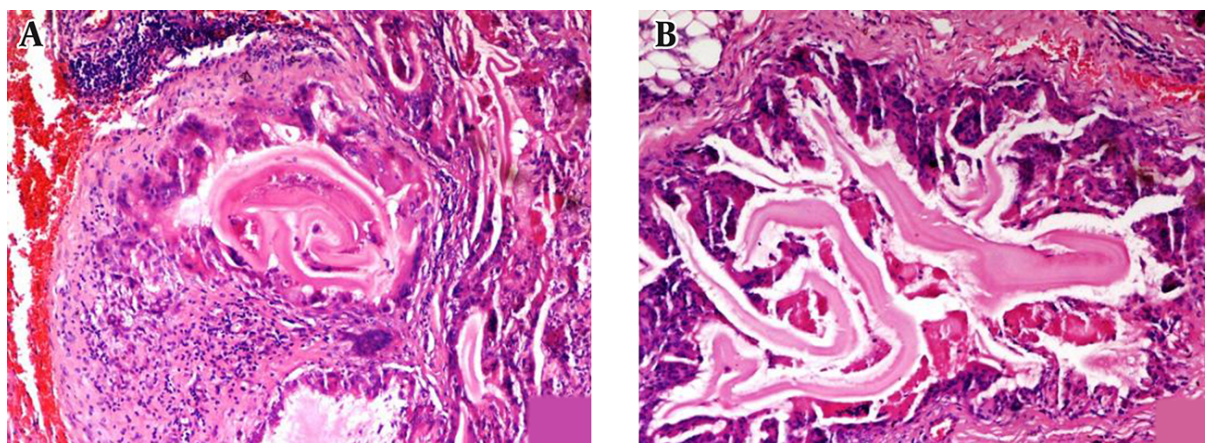


Figure 2. Histological Section in Both Low and High Power Shows Cysts with an Outer Fibrous Layer and Inner Laminated Eosinophilic Material. Cysts Are Lined by Foreign-Body Giant Cells Mixed with Chronic Inflammatory Infiltrate (H and E Staining)

arachnoid cyst. Also, spinal abscess and mycotic infection can be confirmed through culture and sensitivity tests (12).

An accurate preoperative diagnosis of spinal hydatid cyst is very difficult, as there are no pathognomonic signs or conclusive tests (13, 14). There is a wide variety of clinical symptoms favoring hydatidosis, including urticaria, pruritus, edema, asthma, dyspnea, vomiting, diarrhea, colicky abdominal pain, and even anaphylactic shock, which occur as a consequence of cystic fluid spillage (15, 16).

Serological tests are often negative, with sensitivity as low as 25% - 56% (11). A negative serology should not exclude the diagnosis of hydatid disease in case of suggestive imaging results. MRI is the best imaging modality for determining the location of the cystic lesion and the exact spinal levels involved. Therefore, a clinicoradiological correlation is needed to make a presumptive preoperative diagnosis of spinal hydatid cyst. However, histopathological examination of the excised cyst can finally confirm the diagnosis.

Depressive laminectomy with total radical excision of the cyst, aiming to decompress the epidural region without preoperative rupture of the cyst, remains the best curative procedure and treatment of choice for reversing the process of cord compression (17). However, rupture of the cyst inevitably leads to the formation of multiple cysts with recurrences no treatment procedure would overcome. Therefore, meticulous care should be taken while performing surgery in such cases to avoid spillage of the cyst content.

Anthelmintics are prescribed postoperatively to prevent any dissemination or systemic involvement (11). Albendazole doses, recommended by the world health organization (WHO) for visceral hydatid disease, range from 10

to 15 mg/kg/day. To achieve scolical blood levels, treatment with albendazole should be initiated 4 hours (or > 4 hours) before surgery, considering the high to inevitable risk of cyst rupture (18). Follow-up is advised for any recurrence or systemic involvement of hydatid disease. Although MRI is not specific to hydatid disease, it should be the modality of choice in the follow-up of spinal hydatid cyst to ensure early detection of recurrences.

In conclusion, spinal hydatosis is a rare phenomenon, which should be always considered in the differential diagnosis, especially in areas where echinococcosis is endemic. Detailed preoperative evaluation with MRI and CT scan is necessary in localizing the lesion and planning the surgical approach. Postoperative pharmacological administration of anthelmintics, commonly albendazole, is advised due to easy absorption and better efficiency according to WHO recommendations.

Accurate and conclusive diagnosis of hydatid disease is of great importance, as it facilitates suitable surgical planning and proper intraoperative measures to prevent spillage, which can be only assumed when there is already a preoperative suspicion. Decompression of a compromised spinal cord with stabilization may lead to the reversal of symptoms, associated with reduced morbidity and disability. Therefore, hydatid cyst should be always considered before planning a surgical approach while dealing with cystic pathologies of the spine.

Footnote

Authors' Contribution: All the authors contributed to this case report. Noora Saeed, Suhail Ur Rehman, and Saima Khan performed the clinical workup and relevant

laboratory investigations. The final diagnosis was established by Shaista M Vasenwala.

References

1. Awasthy N, Chand K. Primary hydatid disease of the spine: an unusual case. *Br J Neurosurg.* 2005;**19**(5):425-7. doi: [10.1080/02688690500390359](https://doi.org/10.1080/02688690500390359). [PubMed: [16455566](https://pubmed.ncbi.nlm.nih.gov/16455566/)].
2. Song X, Liu D, Wen H. Diagnostic pitfalls of spinal echinococcosis. *J Spinal Disord Tech.* 2007;**20**(2):180-5. doi: [10.1097/01.bsd.0000211288.37013.42](https://doi.org/10.1097/01.bsd.0000211288.37013.42). [PubMed: [17414991](https://pubmed.ncbi.nlm.nih.gov/17414991/)].
3. Kammerer WS. Echinococcosis affecting the central nervous system. *Semin Neurol.* 1993;**13**(2):144-7. doi: [10.1055/s-2008-1041118](https://doi.org/10.1055/s-2008-1041118). [PubMed: [8356347](https://pubmed.ncbi.nlm.nih.gov/8356347/)].
4. Gutierrez Y. Diagnostic pathology of parasitic infections with clinical correlation. 2nd ed. ; 2000. pp. 676-7. The cestode.
5. Charles RW, Govender S, Naidoo KS. Echinococcal infection of the spine with neural involvement. *Spine (Phila Pa 1976).* 1988;**13**(1):47-9. doi: [10.1097/00007632-198801000-00011](https://doi.org/10.1097/00007632-198801000-00011). [PubMed: [3381138](https://pubmed.ncbi.nlm.nih.gov/3381138/)].
6. Braithwaite PA, Lees RF. Vertebral hydatid disease: radiological assessment. *Radiology.* 1981;**140**(3):763-6. doi: [10.1148/radiology.140.3.7280247](https://doi.org/10.1148/radiology.140.3.7280247). [PubMed: [7280247](https://pubmed.ncbi.nlm.nih.gov/7280247/)].
7. Ahmad M, Ahmad I, Ali SA. A rare case of intradural spinal hydatid cyst in a paediatric patient. *JBR-BTR.* 2012;**95**(2):87-8. [PubMed: [22764663](https://pubmed.ncbi.nlm.nih.gov/22764663/)].
8. Lotfinia I, Sayyahmelli S, Mahdkhah A, Shoja MM. Intradural extramedullary primary hydatid cyst of the spine: a case report and review of literature. *Eur Spine J.* 2013;**22 Suppl 3**:S329-36. doi: [10.1007/s00586-012-2373-1](https://doi.org/10.1007/s00586-012-2373-1). [PubMed: [22706667](https://pubmed.ncbi.nlm.nih.gov/22706667/)].
9. Senol N, Kerman M, Ozturk A, Ucmakli E. A Rare Parasitic Infection: Primary Intradural Extramedullary Hydatid Cyst. *Turk Neurosurg.* 2016;**26**(3):460-2. doi: [10.5137/1019-5149.JTN.12209-14.1](https://doi.org/10.5137/1019-5149.JTN.12209-14.1). [PubMed: [27161478](https://pubmed.ncbi.nlm.nih.gov/27161478/)].
10. Ozdemir HM, Ogun TC, Tasbas B. A lasting solution is hard to achieve in primary hydatid disease of the spine: long-term results and an overview. *Spine (Phila Pa 1976).* 2004;**29**(8):932-7. doi: [10.1097/00007632-200404150-00022](https://doi.org/10.1097/00007632-200404150-00022). [PubMed: [15082999](https://pubmed.ncbi.nlm.nih.gov/15082999/)].
11. Pamir MN, Ozduman K, Elmaci I. Spinal hydatid disease. *Spinal Cord.* 2002;**40**(4):153-60. doi: [10.1038/sj.sc.3101214](https://doi.org/10.1038/sj.sc.3101214). [PubMed: [11965552](https://pubmed.ncbi.nlm.nih.gov/11965552/)].
12. Kalkan E, Torun F, Erdi F, Baysefer A. Primary lumbar vertebral hydatid cyst. *J Clin Neurosci.* 2008;**15**(4):472-3. doi: [10.1016/j.jocn.2007.01.011](https://doi.org/10.1016/j.jocn.2007.01.011). [PubMed: [18258436](https://pubmed.ncbi.nlm.nih.gov/18258436/)].
13. Berk C, Ciftci E, Erdogan A. MRI in primary intraspinal extradural hydatid disease: case report. *Neuroradiology.* 1998;**40**(6):390-2. doi: [10.1007/s002340050608](https://doi.org/10.1007/s002340050608). [PubMed: [9689631](https://pubmed.ncbi.nlm.nih.gov/9689631/)].
14. Pamir MN, Akalan N, Ozgen T, Erbenli A. Spinal hydatid cysts. *Surg Neurol.* 1984;**21**(1):53-7. doi: [10.1016/0090-3019\(84\)90401-4](https://doi.org/10.1016/0090-3019(84)90401-4). [PubMed: [6689810](https://pubmed.ncbi.nlm.nih.gov/6689810/)].
15. Sparks AK, Connor DH, Neafie RC. In: Pathology of tropical and extraordinary diseases. Binford CH, Connor DH, editors. 2. ; 1976. pp. 530-4. Echinococcosis.
16. Mandel GL, Bennet JE, Dolin R. Principles and practice of Infectious diseases. 4th ed. Churchill & Livingstone; 2000. pp. 2957-65.
17. Turgut M. Hydatid disease of the spine: a survey study from Turkey. *Infection.* 1997;**25**(4):221-6. doi: [10.1007/BF01713148](https://doi.org/10.1007/BF01713148). [PubMed: [9266261](https://pubmed.ncbi.nlm.nih.gov/9266261/)].
18. Alijani B, Emamhadi M, Chabok S. Hydatid cyst of cervical spine mimicking traumatic burst fracture. *Iranian J Neurosurg.* 2016;**1**(4):20-3.