

Case Report: Gorham's Disease of Cervicothoracic Spine



Khodakaram Raštegar, Hasan Ghandhari , Ebrahim Ameri, Farshad Nikouei , Mohammadreza Shakeri

1. Bone and Joint Reconstruction Research Center, Shafa Orthopedic Hospital, Iran University of Medical Sciences, Tehran, Iran.



Citation Raštegar K, Ghandhari H, Ameri E, Nikouei F, Shakeri MR. Gorham's Disease of Cervicothoracic Spine. Journal of Research in Orthopedic Science. 2019; 6(3):37-42. <http://dx.doi.org/10.32598/JROSI.6.3.37>

<http://dx.doi.org/10.32598/JROSI.6.3.37>



Article info:

Received: 20 Dec 2018

Revised: 26 Jan 2019

Accepted: 06 Jul 2019

Available Online: 01 Aug 2019

Keywords:

Gorham's disease, Spine, Symptoms, Spinal cord compression

ABSTRACT

Introduction: Gorham's disease is a rare enigmatic bone disorder associated with obscure osteolysis pattern, challenging diagnosis and treatment. Particularly, there is a high level of controversy regarding the diagnosis and strategy of treatment in the spinal involvement of Gorham's disease that is generally presented with a kind of spinal deformity.

Case Presentation: Here, we report a case of Gorham's disease of the spine manifested with spinal cord complications and lacking any spinal deformity. The patient was managed through a two-stage spinal cord decompression technique. The symptoms were resolved afterward and five-year visits did not demonstrate any significant complication.

Conclusion: This case reveals that the Gorham's disease of the spine could be presented with spinal cord complication alone. Accordingly, the strategy of treatment should be established based on the occurrence of spinal cord complications or magnitude of spinal deformity.

1. Introduction

Gorham's disease is an extremely rare disorder of the musculoskeletal system with unknown etiology characterized by progressive osteolysis of the involved bones. Till now, nearly 200 cases have been reported in the literature. Clinical manifestations of Gorham's disease depend on the site of involvement and ranges from a relatively abrupt onset of pain and swelling to the limitation of movement or progressive weakness in the affected limb. Specific patterns of regional osseous destruction investigated on the radiographs and

Computed Tomography (CT) scanning could enable physicians to suspect the diagnosis of Gorham's disease.

A bone scan may demonstrate increased uptake in regions with new vascularity and decreased uptake corresponding to the site of diminished osseous tissue. Although anti-osteoclastic medications (bisphosphonates) and interferon alfa-2b are used for the treatment of this disease, radiation therapy and/or surgery are considered as the main treatment modalities. The surgery includes resection of the lesion, and reconstruction using bone grafts or prostheses [1, 2].

* Corresponding Author:

Mohammadreza Shakeri, PhD.

Address: Bone and Joint Reconstruction Research Center, Shafa Orthopedic Hospital, Iran University of Medical Sciences, Tehran, Iran.

Phone: +98 (21) 33542041

E-mail: mshakeri3116@gmail.com

Spinal involvement in the Gorham's disease occurs very rare and usually is associated with a poor prognosis, mostly leading to progressive kyphosis, scoliosis, subluxation and even dislocation of the spine. Spinal cord compression may cause neurological deficits which highly complicates the diagnosis of the lesion.

In case of an unstable spine or severe kyphosis, surgical decompression and stabilization are the available options, although not encouraging, mainly due to the underlying osteoclastic process of the vertebra. Moreover, multiple revision surgeries may be required to achieve spinal stability [3, 4]. Accordingly, the treatment of Gorham's disease of the spine has become a challenge for spine surgeons, as well as its diagnosis. In this report, we aim to illustrate the management of Gorham's disease of the spine in a 30-years-old male initially presented with spinal cord complications, lacking any spinal deformity.

2. Case presentation

A 30-year-old male was referred to our center with a history of Gorham's disease of the arm that was diagnosed and confirmed four years earlier. The patient was presented with a progressive cervical pain, numbness,

and motor weakness in lower limbs from four months ago. He was not able to walk and control his urine and stool. At the clinical examination, hypoaesthesia was discovered at the T6 root distribution and was extended to the bottom the distal part.

The patient was completely paraplegic. Bilateral clonus was positive and a severe spasticity was present in the lower left limb. Bilateral Babinski test was upward. No motor and sensory impairment were noticed at the examination of upper left limbs. At the evaluation of upper right extremity, the patient was unable to move his shoulder and elbow. The shoulder abduction and elbow flexion were both 0/5. The movement of the wrist and fingers were normal (wrist extension, finger flexion and finger abduction all 5/5). Deep Tendon Reflexes (DTR) examination was (2+). The Hoffman's test was negative.

At the radiographic evaluation of the spine, bone destruction was detected in the C7-T1 region (Figure 1). A mixed signal pattern consisting of hyper and hypo-intense areas was also identified in the T2-weighted MRI of the same region along with minimal pressure on the cord (Figure 2). Whole body scintigraphy revealed an increased uptake in the lower cervical vertebrae and the upper thoracic vertebrae (Figure 3). Based

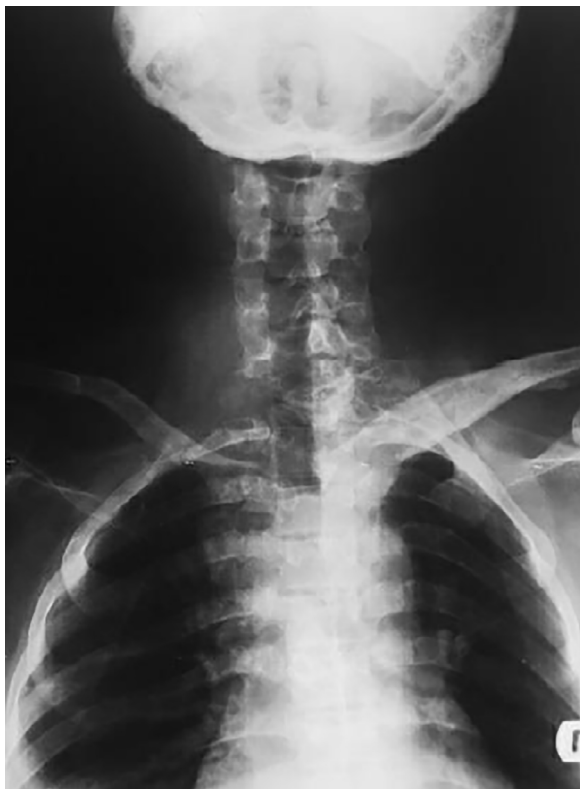

Figure 1. Anteroposterior radiograph of the spine showing the bone destruction in the C7-T1 region

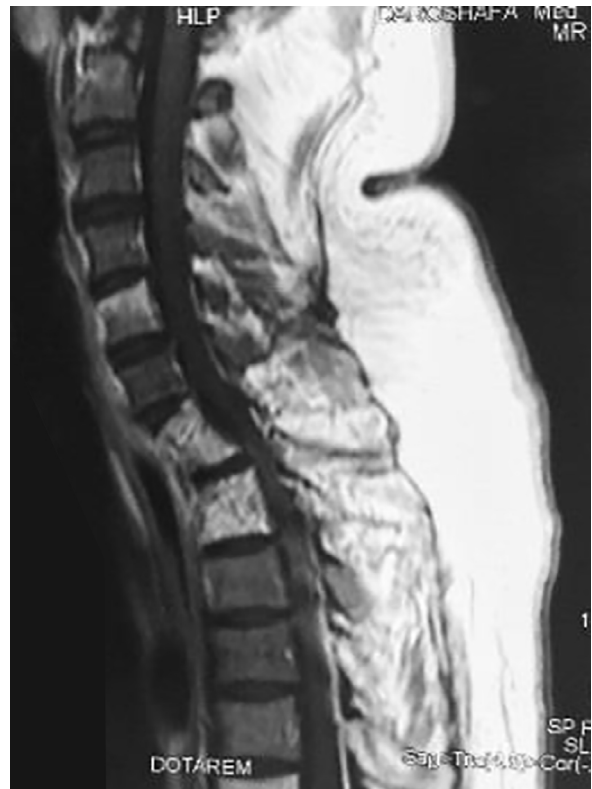
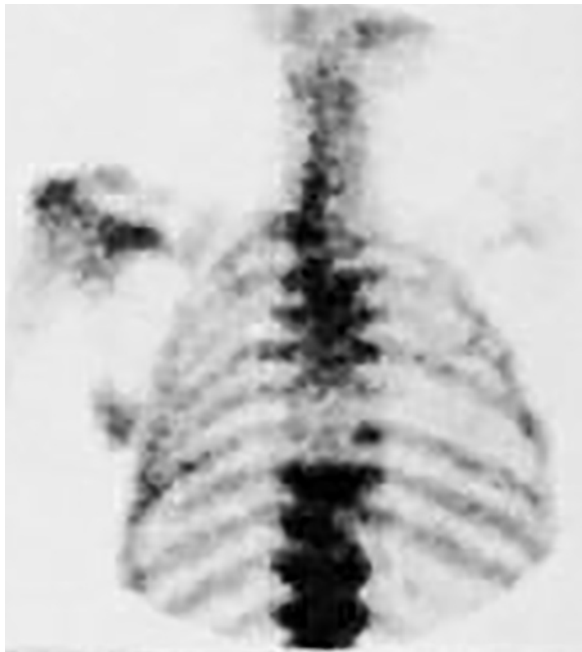
Figure 2. T2-weighted MRI showing a mixed pattern of hyper- and hypo-intense signal identified at C7-T1 region and minimal



Journal of Research in
Orthopedic Science

Figure 3. Bone scan of the spine showing an increased uptake in the lower cervical vertebrae and the upper thoracic vertebrae

on the imaging findings, an idiopathic lytic lesion such as Gorham's disease was suspected in the C7-T1 region that was compressing the spinal cord.

Accordingly, anterior cervical corpectomy and fusion was planned to decompress the spinal cord. The patient underwent anterior sternotomy associated with C7-T1 corpectomy to achieve cord decompression. Fibular autograft was implemented at the corpectomy site. The excised sample was sent to the pathology department for histologic examination.

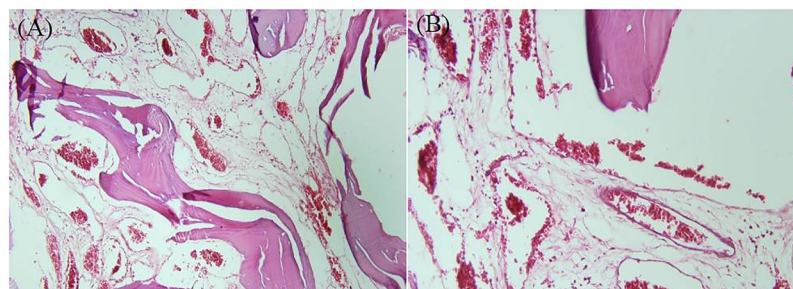
Four days after the surgery, the movement and muscle force of left lower limb were improved (approximately 3/5), but no improvement was observed on the right side. Eight days after the surgery, right ankle dorsiflexion occurred. Subsequently, the patient underwent

a second operation two weeks after the index surgery. At the prone position, laminectomy of C7-T1 vertebrae was performed and bilateral pedicular screws were applied in T2, T3, T4 vertebrae. Lateral mass screws were also placed at both sides of C4, C5, C6 vertebrae, and posterior spinal fusion was carried out by introducing two rods. Pathology report included the expansion of marrow spaces that were filled by numerous small and large vascular channels accomplished with flat ends and the lial linings, suggestive of the angiomatosis and Gorham's disease (Figure 4).

The patient was discharged with a good general health and wearing a Minerva brace. The rehabilitation process was initiated subsequently which included the range of motion and stretching exercises. Nowadays, the patient was able to walk without the crutch. Left lower limb motion, in addition to the left L2, L3, L4, L5, and S1 nerve roots function were at their normal strength and no sensory impairment was present. The force of right side hip flexors was approximately 3/5, but the force of ankle dorsiflexors was great. The force of knee extension was about 4/5. Hypoesthesia was present at the right lower limbs from the knee to the distal end. The patient regained his urine and stool control. Final follow-up radiographs of the patient revealed the fusion mass obtained by the fixation of lateral copper screws at C4, C5, C6 and bilateral pedicular screws at T2, T3, T4 vertebrae those were connected with rods (Figure 5).

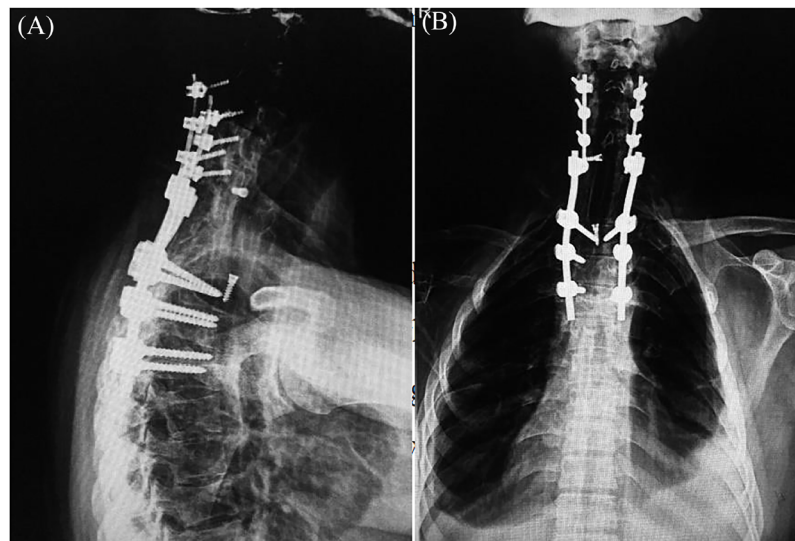
3. Discussion

Gorham's disease is an enigmatic bone disease with a difficult diagnosis and management. The diagnosis and treatment of Gorham's disease are even more challenging in the spine. Although the majority of patients represent with spinal deformity, some patients might present with the spinal cord compression symptoms alone. The treatment of the Gorham's disease of the spine could also get complicated with multiple revision surgeries to



Journal of Research in
Orthopedic Science

Figure 4. Histologic slides showing the expansion of marrow spaces filled by numerous small and large vascular channels with flat end and the lial linings; A: 10X; B: 20X



Journal of Research in
Orthopedic Science

Figure 5. Radiograph of seven years after the final surgery showing fixation of lateral screws at C4, C5, C6 and bilateral pedicular screws at T2, T3, T4 vertebra; A: Lateral; B: Anteroposterior

The fibular autograft which is fixed with two screws in corpectomy site (C7, T1) is also visible

achieve spinal stability. At the same time, the surgeon should observe other complications of spinal cord injury such as deep vein thrombosis, heterotopic ossification, and autonomic dysfunction [4].

In this report, we presented a case of Gorham's disease of spine primarily manifested with spinal cord compression symptoms and without any spinal deformity. Complementary imaging and histologic investigations led to the diagnosis of Gorham's disease of the spine. The patient's symptoms almost resolved after the surgical resection of the lesion and rehabilitation exercises.

To date, nearly 28 cases of Gorham's disease of the spine has also been reported in the literature [3]. Barman et al. reported two cases of Gorham's disease of the spine. One of their patients was a 23-year-old male that was referred with spinal cord compression symptoms including weakness of lower limbs, spasticity, impaired sensations, impaired bladder-bowel control, as well as a history of Gorham's disease at the age of 3. Multiple revision surgeries were performed for this patient to ensure spinal stability. The second patient was a 15-year-old boy presented with progressive spinal deformity since eight years ago, back pain for three months, complete weakness of lower limbs, and bowel-bladder incontinence [4]. This patient was also managed surgically.

Aizava et al. reported a case of Gorham's disease of the spine in a 10-year-old boy referred with back pain and spinal deformity. At the neurologic examination, muscle weakness was found at the left great toe. The

patient had a high fever and increase white blood cell count and C-reactive protein. The definitive diagnosis of Gorham's disease was made through the open biopsy and histologic examination. Treatment was started with bisphosphonate. Yet, the patient underwent surgery for progressive kyphosis [3].

Sekharappa et al. also reported two cases of Gorham's disease of the spine, both presented with the spinal deformity and spinal cord compression symptoms. The lesion was resected surgically and the symptoms removed in both patients after the rehabilitation period [5].

Even in the presence of spinal deformity or spinal cord compression symptoms, the diagnosis of Gorham's disease should only be suspected after excluding the other common underlying causes of osteolysis including aneurysmal bone cyst, extensive metastatic bone disease, and osteosarcoma that may resemble vanishing bone disease. Moreover, appropriate blood tests and radiographic studies should be done to rule out other common underlying causes of osteolysis such as infection, inflammatory or endocrine disorders [6, 7].

The natural history of Gorham's disease is unpredictable and spontaneous regression has been reported [8, 9]. Aizava et al. proposed that if the affected vertebrae show no deformity such as kyphosis, radiotherapy and/or medication should be chosen as the initial treatment [3]. Yet, our case indicates that spinal cord compression could be the initial presentation of Gorham's disease of the spine, necessitating performance of surgical decom-

pression surgery. Thus, we recommend basing the treatment option on the spinal cord compression symptoms, as well as spinal deformity.

4. Conclusion

Gorham's disease of the spine is an enigmatic bone disorder with obscure osteolysis pattern. Although many patients present with the spinal deformity, some patients, could be presented with spinal cord compression symptoms alone. The treatment approach should be based on either spinal deformity or the spinal cord compression symptoms, as the patients without spinal deformity still may require a spinal cord decompression surgery.

Ethical Considerations

Compliance with ethical guidelines

The patient provided written consent to use his medical files for publication.

Funding

This research did not receive any specific grant from funding agencies in the public, commercial, or not-for-profit sectors.

Authors' contributions

All authors contributed in preparing this article.

Conflict of interest

The authors declared no conflict of interests.

References

- [1] Patel DV. Gorham's disease or massive osteolysis. *Clin Med Res.* 2005; 3(2):65-74. [DOI:10.3121/cmr.3.2.65]
- [2] Saify FY, Gosavi SR. Gorham's disease: A diagnostic challenge. *J Oral Maxillofac Pathol.* 2014; 18(3):411. [DOI:10.4103/0973-029X.151333] [PMID] [PMCID]
- [3] Aizawa T, Sato T, Kokubun S. Gorham disease of the spine: A case report and treatment strategies for this enigmatic bone disease. *Tohoku J Exp Med.* 2005; 205(2):187-96. [DOI:10.1620/tjem.205.187] [PMID]
- [4] Barman A, Bhide R, Viswanathan A, George J, Thomas R, Tharion G. Gorham's disease of the spine. *Neurorehabil.* 2013; 33(1):121-6. [DOI:10.3233/NRE-130935] [PMID]
- [5] Sekharappa V, Arockiaraj J, Amritanand R, Krishnan V, David KS, David SG. Gorham's disease of spine. *Asian Spine J.* 2013; 7(3):242-7. [DOI:10.4184/asj.2013.7.3.242] [PMID] [PMCID]
- [6] Raghuvveer H, Jayalekshmy R. Gorham's massive osteolysis of the mandible-a progressive radiographic presentation. *Dentomaxillofac Radiol.* 2009; 38(5):292-5. [DOI:10.1259/dmfr/73198793] [PMID]
- [7] Kiran D, Anupama A. Vanishing bone disease: A review. *J Oral Maxillofac Surg.* 2011; 69(1):199-203. [DOI:10.1016/j.joms.2010.05.088] [PMID]
- [8] Campbell J, Almond H, Johnson R. Massive osteolysis of the humerus with spontaneous recovery: Report of a case. *J Bone Joint Surg.* 1975; 57(2):238-40. [DOI:10.1302/0301-620X.57B2.238] [PMID]
- [9] Choma ND, Biscotti CV, Bauer TW, Mehta AC, Licata AA. Gorham's syndrome: A case report and review of the literature. *Am J Med.* 1987; 83(6):1151-6. [DOI:10.1016/0002-9343(87)90959-4]

This Page Intentionally Left Blank