

Review Paper: The Effect of Partial Lateral Facetec- tomy of the Patella on the Radiographic and Clinical Outcome of Unresurfaced Patellar-retaining Total Knee Arthroplasty



Abolfazl Bagherifard¹ , Mahmoud Jabalameli¹ , Fouad Rahimi^{1*} , Mohamad Taher Ghaderi¹ , Mohamadreza Heidari Khoo¹ , Naseh Soleymani¹

1. Bone and Joint Reconstruction Research Center, Shafa Orthopedic Hospital, Iran University of Medical Sciences, Tehran, Iran.



Citation Bagherifard A, Jabalameli M, Rahimi F, Ghaderi MT, Heidari Khoo M, Soleymani N. The Effect of Partial Lateral Facetec-
tomy of the Patella on the Radiographic and Clinical Outcome of Unresurfaced Patellar-retaining Total Knee Arthro-
plasty. Journal of Research in Orthopedic Science. 2020; 7(1):1-6. <http://dx.doi.org/10.32598/JROSJ.7.1.1>

<http://dx.doi.org/10.32598/JROSJ.7.1.1>



Article info:

Received: 15 Aug 2019

Revised: 27 Aug 2019

Accepted: 26 Dec 2019

Available Online: 01 Feb 2020

Keywords:

Total knee arthroplasty,
Patella, Partial lateral
facetec-
tomy

ABSTRACT

Background: Management of patellar maltracking during primary TKA is of considerable importance. Lateral release, which is generally performed for this purpose, is associated with several complications.

Objectives: In this study, we aimed to evaluate the role of partial lateral facetec-
tomy in tracking the patella in Total Knee Arthroplasty (TKA).

Methods: In a retrospective study, the efficiency of partial lateral facetec-
tomy of the patella in achieving proper tracking of the patella was evaluated in 116 patients who underwent unresurfaced patellar-retaining TKA. The radiographic outcome measures included the patellar tilt and patellar shift. The functional outcome was assessed with Kujala anterior knee pain scale.

Results: The Mean±SD age of the patients was 66.3±7.6 years. The mean follow-up of patients was 20.6±8.9 months. The Mean±SD patellar tilt was 10.5±7.2° before the surgery and 4.4±5° after the operation (P<0.001). The Mean±SD preoperative patellar shift was 3.3±4.3 mm which improved to -0.2±2.8° after the surgery (P<0.001). The Mean±SD Kujala score of the patients was 74.6±7.1, ranging from 54 to 89. No complication was recorded during the follow-up period.

Conclusion: Partial lateral facetec-
tomy of the patella provides an acceptable radiographic and functional outcome in patients undergoing primary TKA. Therefore, it could be regarded as a valuable alternative to lateral release in unresurfaced patellar-retaining TKA.

* Corresponding Author:

Fouad Rahimi, MD.

Address: Bone and Joint Reconstruction Research Center, Shafa Orthopedic Hospital, Iran University of Medical Sciences, Tehran, Iran.

Phone: +98 (21) 33542041

E-mail: foadrahi76@gmail.com

1. Introduction

Osteoarthritis is the leading cause of pain and disability in the elderly population. As society ages, the number of people living with symptomatic osteoarthritis will increase [1]. Concurrently, the number of patients who need surgical intervention for the treatment of symptomatic osteoarthritis will increase, as well. Although total knee arthroplasty is considered one of the most successful operations of the century [2], up to 30% of patients are dissatisfied with the results of Total Knee Arthroplasty (TKA) [3]. Therefore, the optimization of this technique is of critical value to improve the postoperative quality of life of the patients.

Patellofemoral pain and instability have remained the frequent complications after TKA, so that 8%-12% of early revisions are due to patellar maltracking [4, 5]. Therefore, a successful TKA requires the prevention of patellar maltracking, which in non-resurfaced patella is mostly performed by the lateral retinacular release. Even so, the lateral release is associated with several complications, including avascular necrosis, anterior knee pain, patellar fractures, and loosening, and wound healing problems. It may also injure the lateral blood supply of the patella [6, 7].

Partial lateral facetectomy of the patella could be used for minimizing the pain caused by the contact of the lateral patellar facet and the lateral femoral trochlea. This technique has been reported to achieve effective bony decompression and retinacular lengthening while avoiding the complications of lateral retinacular release [8, 9].

In this study, we aimed to evaluate the efficiency of partial lateral facetectomy of the patella in achieving proper tracking of the patella. We also tried to assess the short-term functional outcomes of this procedure in unresurfaced patellar-retaining TKA.

2. Methods

In a retrospective study, the medical records of patients who underwent TKA in our center between 2012 and 2018 were reviewed for eligibility criteria. Patients who had a follow-up of fewer than six months, or underwent lateral retinacular release, patellar resurfacing, and other approaches than medial parapatellar were excluded from the study. Patients with a hinged or CCK prosthesis were excluded from the study as well. Out of 150 evaluated patients, 116 patients were eligible for the study.

Surgical technique

Under general or regional anesthesia and application of a tourniquet, arthrotomy was performed through the medial parapatellar approach. After the lateral displacement of the patella, a distal femoral cut and proximal tibia cut was made. The tibiofemoral and femoral component rotation were adjusted to the desired angles. Cement was used for the fixation of both tibial and femoral implants. For the patella, the patellar osteophytes were first removed to ease the patellofemoral movement. Then, denervation of the patella was performed using electrocautery. Subsequently, about 1 cm of the lateral patella was resected with an oscillating saw (Figure 1). After this step, patellar tracking was assessed during the operation, and, if necessary, a staged lateral retinacular release was performed. Range of motion exercises was started immediately after the surgery. Partial weight-bearing started a day after the operation.

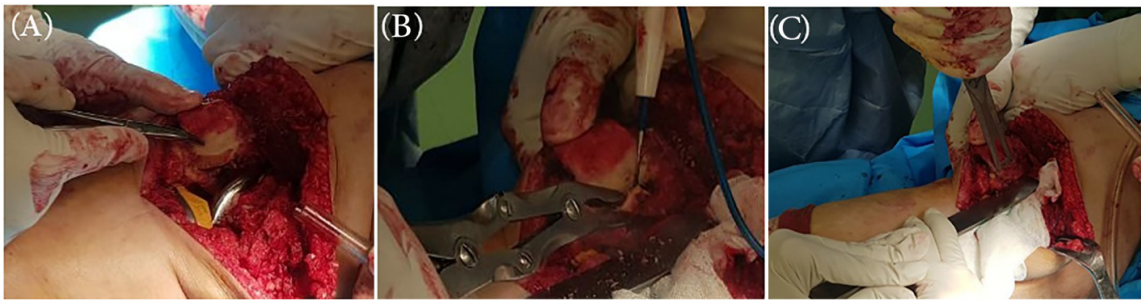
Outcome measures

The patients' demographic characteristics were extracted from the medical files. Radiographic evaluation of outcome included mechanical femorotibial angle (mFTA), patellar shift, and patellar tilt. mFTA was evaluated on standing anteroposterior radiograph. Patellar shift and tilt were evaluated on the merchant view radiographs while the knee was flexed at 45°. The angle between the anterior intercondylar line and the transverse patellar axis was considered as patellar tilt [10, 11] (Figure 2a). Patellar tilt was expressed as positive or negative whenever the transverse axis tilted laterally or medially relative to the anterior intercondylar axis, respectively. The distance between the intercondylar sulcus and the median patellar ridge was considered as the patellar shift [10, 11] (Figure 2b). The value was expressed as positive or negative when the median ridge of the patella located lateral or medial to the intercondylar sulcus, respectively.

The Persian version of the Kujala anterior knee pain scale was used for the evaluation of functional outcome [12]. It is a 13-item screening questionnaire with total scores ranging from 0 to 100. A higher score indicates a better function

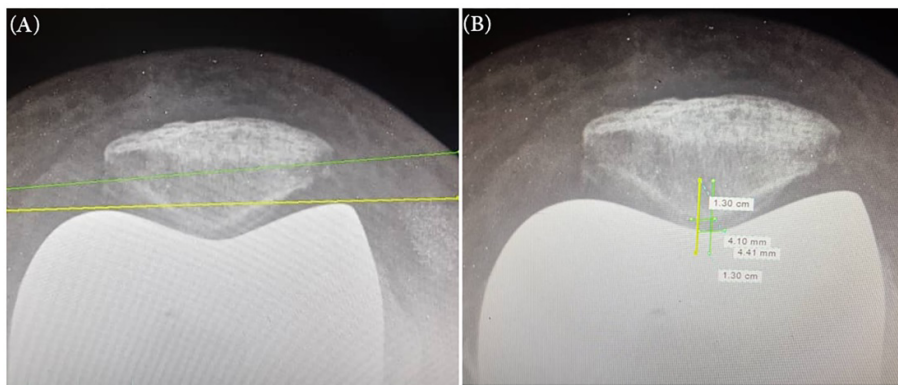
Statistical analysis

The obtained data were evaluated in SPSS V. 16. Descriptive data were presented as Mean±SD or number and percentage. A paired t test or its nonparametric counterpart (Wilcoxon signed-rank test) was used for the comparison of pre- and post-operative measures. The Pearson correlation



Journal of Research in
Orthopedic Science

Figure 1. Intraoperative photographs of lateral patellar facetectomy in unresurfaced patellar-retaining total knee arthroplasty



Journal of Research in
Orthopedic Science

Figure 2. Radologic measurements

A. Evaluation of patellar tilt, B. patellar shift on merchant view radiographs

was used to examine potential correlations. A P value of less than 0.05 was considered significant.

3. Results

The result of lateral patellar facetectomy was evaluated in 116 patients who underwent unresurfaced patellar-retaining TKA. The study population included 20 males

(17.2%) and 96 females (82.8%) with the Mean±SD age of 66.3±7.6 years, ranging from 47 to 85 years. The mean follow-up period of patients was 20.6±8.9 months, ranging from 7 to 47 months. Table 1 presents the demographic characteristics of the patients.

The Mean±SD preoperative mFTA was 13.9±6.9° which improved to 0.6±1.9° after the operation. This

Table 1. The demographic characteristics of the patients who underwent total knee arthroplasty with lateral patellar facetectomy (The data are presented as Mean±SD or number (%))

Variable		Patients (N=116)
Age (y)		66.3±7.6
Sex	Male	20 (17.2)
	Female	96 (82.8)
Follow-up (mo)		20.6±8.9
Preoperative MFTA (°)		13.9±6.9
Postoperative MFTA (°)		0.6±1.9
Preoperative patellar tilt (°)		10.5±7.2
Postoperative patellar tilt (°)		4.4±5
Preoperative patellar shift (mm)		3.3±4.3
Postoperative patellar shift (mm)		-0.2±2.8
Kujala scale		74.6±7.1

BMI: Body Mass Index; MFTA: Mechanical Femorotibial Angle.

Journal of Research in
Orthopedic Science

difference was statistically significant ($P < 0.001$). The Mean \pm SD patellar tilt was $10.5 \pm 7.2^\circ$ before the surgery and $4.4 \pm 5^\circ$ after the operation. This difference was statistically significant ($P < 0.001$) as well. The Mean \pm SD preoperative patellar shift was 3.3 ± 4.3 mm which improved to -0.2 ± 2.8 after the surgery. This difference was statistically significant, too ($P < 0.001$). The Mean \pm SD Kujala score of the patients was 74.6 ± 7.1 , ranging from 54 to 89.

Kujala score was significantly correlated with the improvement of patellar tilt ($r = 0.193$, $P = 0.038$). No significant correlation was found between the Kujala score and other radiographic outcome measures. No significant association was also found between the Kujala score and demographic characteristics of the patients. No complication was recorded during the follow-up period of the study.

4. Discussion

The patellar contact pressures will significantly increase after TKA so that the patella tracks 3 to 5 mm more laterally after the prosthesis placement. This excessive stress on the patella would result in inferior results and could predispose the initiation of the degenerative patella [13-15]. Therefore, the management of patellar maltracking during primary TKA is of considerable importance.

Partial facetectomy helps more appropriate placement of the patella inside the trochlea of the femoral prosthesis. It limitedly and partially releases the lateral retinaculum and produces a more congruent patella. This event results in better tracking of the patella in patients undergoing TKA [9].

In this study, we aimed to evaluate how partial lateral facetectomy helps the tracking of the patella, in unresurfaced patellar-retaining TKA. Based on the results of the present study, patellar facetectomy leads to the improved patellar tilt and patellar shift after the TKA. Moreover, the function of the knee, evaluated by the Kujala anterior knee scale, was in acceptable range in the majority of patients. No complication was noticed in association with partial lateral facetectomy.

Zhang et al. retrospectively evaluated the functional outcome of a partial lateral facetectomy in patellar-retaining TKA in 63 knees of 59 patients who underwent TKA for primary knee osteoarthritis. TKA was performed with patellar facetectomy in 32 knees of 30 patients and without patellar facetectomy in 31 knees

of 29 patients. Based on their results, patients of facetectomy group showed more significant improvements in the patellar score, Western Ontario and McMaster Universities score, knee and function scores. Fewer lateral patellar osteophytes were seen in radiographs of this group, as well. They concluded that partial lateral facetectomy was a practical approach to improve the function of patellar-retaining TKA [8]. Zhang et al. did not evaluate the effect of partial lateral facetectomy on the radiographic measures of the patella, including the patella shift and tilt.

Lakstein et al. evaluated the outcome of selective use of partial patellar lateral facetectomy for the management of patellar maltracking during primary TKA, as an alternative to lateral release.

Twenty-three partial facetectomies were performed in this study. In 22 knees, balanced tracking was obtained. Persistent anterior knee pain was noticed in two patients during the follow-up period. Mean Knee Society score and mean functional Knee Society score were 94 and 86, respectively. The average patellar score was 28. In 22 knees patellar tilt was within two degrees. The patellar translation was within two mm in all patients. No complications were recorded in this series. They concluded that if tracking is not satisfactory in TKA, partial lateral facetectomy could be used as the selected method of choice [9]. Similar to the study of Lakstein et al., patellar tilt was significantly improved in the present series. No complication was recorded in the current series, as well.

Our results, similar to the results of earlier investigations, reveal that partial lateral facetectomy is a valuable alternative to lateral release for the management of patellar tracking in unresurfaced patellar-retaining TKA.

The present investigation has some limitations, too. The main limitation of this study was the inability to record the preoperative Kujala score of the patients, which was caused by the retrospective nature of the patients. Moreover, a comparison of the outcome of patellar facetectomy in unresurfaced patellar-retaining TKA with patellar facetectomy in resurfacing patellar TKA would have resulted in more valuable data. However, this comparison was not possible in our center due to the small number of patients. Therefore, future studies with the prospective designs and control group are required to fully understand the role of partial lateral patellar facetectomy in the outcome of unresurfaced patellar-retaining TKA.

5. Conclusion

Partial lateral facetectomy of the patella provides an acceptable radiographic and functional outcome in patients undergoing primary TKA. The complication rates of this approach are negligible comparing to the lateral release technique. Therefore, it could be regarded as a valuable alternative to lateral release in unresurfaced patellar-retaining TKA.

Ethical Considerations

Compliance with ethical guidelines

The review board approved this research of our institute under the (Code: IR.BJRC.ER.1398.400). The written consent was obtained from the patients before their participation in the study.

Funding

This research did not receive any specific grant from funding agencies in the public, commercial, or not-for-profit sectors.

Authors' contributions

Conceptualization, Supervision: Abolfazl Bagherifard, Mahmoud Jabalameli; Methodology, investigation: All authors; Writing-original draft, resources: Fouad Rahimi; Writing-Review&editing: Abolfazl Bagherifard, Mahmoud Jabalameli, Fouad Rahimi

Conflict of interest

The authors declared no conflict of interest.

References

- [1] Zhang Y, Jordan JM. Epidemiology of osteoarthritis. *Clin Geriatr Med.* 2010; 26(3):355-69. [DOI:10.1016/j.cger.2010.03.001] [PMID] [PMCID]
- [2] Losina E, Katz JN. Total knee arthroplasty on the rise in younger patients: Are we sure that past performance will guarantee future success? *Arthritis Rheum.* 2012; 64(2):339. [DOI:10.1002/art.33371] [PMID] [PMCID]
- [3] Canovas F, Dagneaux L. Quality of life after total knee arthroplasty. *Orthop Traumatol Surg Res.* 2018; 104(Suppl. 1):S41-46 [DOI:10.1016/j.otsr.2017.04.017] [PMID]
- [4] Fehring TK, Odum S, Griffin WL, Mason JB, Nadaud M. Early failures in total knee arthroplasty. *Clin Orthop Relat Res.* 2001; 392:315-8. [DOI:10.1097/00003086-200111000-00041] [PMID]
- [5] Sharkey PF, Hozack WJ, Rothman RH, Shastri S, Jacoby SM. Why are total knee arthroplasties failing today? *Clin Orthop Relat Res.* 2002; 404:7-13. [DOI:10.1097/00003086-200211000-00003] [PMID]
- [6] Molyneux S, Brenkel I. Predictors and outcomes of lateral release in total knee arthroplasty: A cohort study of 1859 knees. *Knee.* 2012; 19(5):688-91. [DOI:10.1016/j.knee.2011.10.004] [PMID]
- [7] Ritter MA, Pierce MJ, Zhou H, Meding JB, Faris PM, Keating EM. Patellar complications (total knee arthroplasty). Effect of lateral release and thickness. *Clin Orthop Relat Res.* 1999; 367:149-57. [DOI:10.1097/00003086-199910000-00018]
- [8] Zhang LZ, Zhang XL, Jiang Y, Wang Q, Chen YS, Shen H. Lateral patellar facetectomy had improved clinical results in patients with patellar-retaining total knee arthroplasty. *J Arthroplasty.* 2012; 27(8):1442-7. [DOI:10.1016/j.arth.2011.12.018] [PMID]
- [9] Lakstein D, Naser M, Adar E, Atoun E, Edelman A, Hendel D. Partial lateral patellar facetectomy as an alternative to lateral release in Total Knee Arthroplasty (TKA). *J Arthroplasty.* 2014; 29(11):2146-9. [DOI:10.1016/j.arth.2014.06.013] [PMID]
- [10] Chia S-L, Merican AM, Devadasan B, Strachan RK, Amis AA. Radiographic features predictive of patellar maltracking during total knee arthroplasty. *Knee Surg Sports Traumatol Arthrosc.* 2009; 17(10):1217-24. [DOI:10.1007/s00167-009-0832-y] [PMID]
- [11] Kong CG, Cho HM, Suhl KH, Kim MU, In Y. Patellar tracking after total knee arthroplasty performed without lateral release. *Knee.* 2012; 19(5):692-5. [DOI:10.1016/j.knee.2011.09.007] [PMID]
- [12] Negahban H, Pouretzad M, Yazdi MJS, Sohani SM, Mazaheri M, Salavati M, et al. Persian translation and validation of the Kujala patellofemoral scale in patients with patellofemoral pain syndrome. *Disabil Rehabil.* 2012; 34(26):2259-63. [DOI:10.3109/09638288.2012.683480] [PMID]
- [13] Tanzer M, McLean CA, Laxer E, Casey J, Ahmed AM. Effect of femoral component designs on the contact and tracking characteristics of the unresurfaced patella in total knee arthroplasty. *Can J Surg.* 2001; 44(2):127-33. [PMID] [PMCID]
- [14] von Eisenhart-Rothe R, Siebert M, Bringmann C, Vogl T, Englmeier K-H, Graichen H. A new in vivo technique for determination of 3D kinematics and contact areas of the patello-femoral and tibio-femoral joint. *J Biomech.* 2004; 37(6):927-34. [DOI:10.1016/j.jbiomech.2003.09.034] [PMID]
- [15] McAlindon T, Snow S, Cooper C, Dieppe P. Radiographic patterns of osteoarthritis of the knee joint in the community: the importance of the patellofemoral joint. *Ann Rheum Dis.* 1992; 51(7):844-9. [DOI:10.1136/ard.51.7.844] [PMID] [PMCID]

This Page Intentionally Left Blank
