

Research Paper: Improvement of Spinopelvic Parameters Following the Surgical Treatment of Spondylolisthesis Using Interbody Fusion Cage



Hasan Ghandhari¹, Farshad Nikouei¹, Mohammad Reza Chehrassan¹, Mohamadreza Heidarikhoo¹, Mohammad Reza Shakeri^{1*}

1. Bone and Joint Reconstruction Research Center, Shafa Yahyaian Hospital, Iran University of Medical Sciences, Tehran, Iran.



Citation Ghandhari H, Nikouei F, Chehrassan MR, Heidarikhoo M, Shakeri MR. Improvement of Spinopelvic Parameters Following the Surgical Treatment of Spondylolisthesis Using Interbody Fusion Cage. Journal of Research in Orthopedic Science. 2020; 7(4):159-164. <http://dx.doi.org/10.32598/JROSJ.7.4.595.2>

doi: <http://dx.doi.org/10.32598/JROSJ.7.4.595.2>



Article info:

Received: 01 Sep 2020

Revised: 22 Sep 2020

Accepted: 10 Oct 2020

Available Online: 01 Nov 2020

Keywords:

Spondylolisthesis,
Interbody fusion,
Spinopelvic, Posterior
spinal fusion

ABSTRACT

Background: There is no consensus regarding the clinical benefit of interbody fusion cage in the treatment of Spondylolisthesis (SL). This study aimed to evaluate the effect of posterolateral fusion combined with interbody fusion cage on the spinopelvic parameters and the pain level of the patients.

Objectives: Role of interbody fusion in the treatment of spondylolisthesis

Methods: This prospective study included 40 SL patients who underwent surgery following the failure of conservative management. The Meyerding classification was used to grade SL. Also, the visual analog scale was used to measure the level of pain, before and after the operation. Spinopelvic parameters included total kyphosis, sagittal vertebral axis, pelvic tilt, pelvic incidence, and lumbar lordosis.

Results: The Mean±SD age of the patients was of 53.4±11.6 years. In four patients (10%), SL occurred at two levels. Besides, the etiology was degenerative in 21 cases (52.5%) and isthmic in 19 cases (47.5%). The grade I, II, and III of SL were detected respectively in 17, 17, and 6 cases (42.5%, 42.5%, and 15%, respectively). The Mean±SD preoperative value of the sagittal vertebral axis was 43.1±33.1 mm, which improved to 24.8±22.3 mm after the surgery (P<0.001). Also, the Mean±SD preoperative value of the pelvic tilt significantly improved from 19.2±10° to 17±9.1° (P=0.049). Moreover, the Mean±SD score of the visual analog scale improved from 9.1±0.8 to 2.8±1.2 (P<0.001). The clinical and spinopelvic parameters greatly improved in patients with degenerative SLs, single-level SLs, and the lower grades of SL.

Conclusion: Posterolateral fusion combined with interbody fusion cage improves both the clinical and spinopelvic parameters of SL patients and could be suggested as the treatment of choice for these patients.

* Corresponding Author:

Mohammad Reza Shakeri, MD.

Address: Bone and Joint Reconstruction Research Center, Shafa Yahyaian Hospital, Iran University of Medical Sciences, Tehran, Iran.

Phone: +98 (21) 33542000-8

E-mail: mshakeri3116@gmail.com

1. Introduction

Spondylolisthesis (SL) is the displacement of one vertebra and mainly occurs at the base of the spine. The SL results in the forward or anterior slippage of a vertebra over the vertebra inferior to it. Several etiologies have been introduced for SL. Etiologies explained for the isthmic and degenerative SL are most commonly accepted. At presentation, low-back pain is the main complication of the patients [1].

The symptomatic SL is currently treated with multiple treatment modalities. Conservative treatment is the primary means of treatment and most of the patients appropriately respond to this treatment. Also, surgical intervention is indicated in refractory cases. However, every treatment plan mainly aimed to relieve the back pain [1, 2]. Yet, SL is associated with a disturbed global sagittal balance of the spine, also, the restoration of global spinopelvic balance is an important factor in the improvement of the biomechanical environment for fusion [3-6].

A variety of surgical techniques, including decompression, vertebral reduction, instrumentation (pedicle screw, rod, plate, interspinous device, etc), and fusion (posterolateral or interbody) have been implicated alone or in combination with each other. However, there is no universal agreement on a sole surgical approach for the treatment of SL [6-8].

Interbody fusion cage was initially proposed to improve the fusion and prevent the loss of reduction following the SL surgery [9]. Later investigations demonstrated no clinical benefit of the interbody fusion cage, in addition to an increase in cost and more complication and morbidity [10, 11]. Consequently, the implication of the interbody fusion cage added a new layer of complexity to an already complicated surgery.

Considering the importance of sagittal balance in SL treatment, the present study aimed to investigate how posterolateral fusion combined with interbody fusion cage impacts the postoperative spinopelvic parameters and the pain level of the patients.

2. Materials and Methods

This study was approved by the review board of our institute. Also, written consent was obtained from the patients to use their medical data for publication. This prospective study included patients with the diagnosis of isthmic and degenerative SL, between 2010 and 2018.

The patients had back pain with or without spinal stenosis/claudeication and underwent surgery at our center following the failure of conservative management. The surgical approach was comprised of posterolateral fusion and interbody fusion cage. Moreover, decompressive surgery was done for all patients at the level of SL.

The study included both single-level and multilevel SL. The exclusion criteria were the SL cases with other etiologies, the follow-up time of less than 12 months, a previous history of spinal surgery, and treatment with other surgical approaches. All the surgeries were performed with the same senior surgeon.

Intraoperative assessments included incidental durotomy, the amount of blood loss, and the timing of the surgery. Besides, the Visual Analog Scale (VAS) was used to measure the level of pain before and after the operation (at the last follow-up session). The spinopelvic parameters were assessed on the pre and postoperative lateral whole-spine standing radiographs; the assessment comprised of total kyphosis, Sagittal Vertebral Axis (SVA), pelvic tilt (PT), Pelvic Incidence (PI), and Lumbar Lordosis (LL).

The Meyerding classification was used to grade SL. According to this classification, The caudal vertebra is divided into four sections, also, a translation of the cranial vertebra of up to 25%, 50%, 75%, and 100% are considered as grade I, II, III, and IV, respectively [12].

Statistical analysis

The SPSS-16 for Windows was used for the statistical analyses of the data. Descriptive statistics were provided as Mean±Standard or number and percentage (%). Also, the paired t test or Kruskal-Wallis test was used to compare the mean values before and after the surgeries. the parameters were compared between different groups, using the independent t test or the Mann-Whitney U test. A P value of lower than 0.05 was considered significant.

3. Results

This study included a total of 40 SL patients who underwent posterolateral fusion combined with an interbody fusion cage. The study population comprised of six males (15%) and 34 females (85%) and had the Mean±SD age of 53.4±11.6 years (range, 31 to 75 years). Also, L5-S1 was the most frequent level of involvement. In four patients (10%), SL occurred at two levels; it occurred at one level in the remaining patients (90%). Moreover, the etiology of SL was degenerative

in 21 cases (52.5%) and isthmic in 19 cases (47.5%). Based on the Meyerding classification, the grade I, II, and III of SL were detected respectively in 17, 17, and 6 cases (42.5%, 42.5%, and 15%, respectively). However, no case of grade IV SL was detected in our series. The mean±SD follow-up time of the patients was 25.7±9.4 months (range, 15 to 45 months).

While preoperative SVA was over 50 mm in 18 patients (45%), postoperative SVA was over 50 mm in only three patients (7.5%). The Mean±SD preoperative SVA was 43.1±33.1 mm, which was improved to 24.8±22.3 mm after the surgery ($P<0.001$). Furthermore, the Mean±SD preoperative PT was 19.2±10° and was improved to 17±9.1° ($P=0.049$). No other significant difference was found between the pre and postoperative spinopelvic parameters. The Mean±SD pre and postoperative VAS of the patients were 9.1±0.8 and 2.8±1.2, respectively ($P<0.001$). Table detailedly demonstrates the pre and postoperative parameters of the patients. Besides, the Mean±SD blood loss of the patients was 733.8±385.4 mL. The Mean±SD operation time was 186.1±40.6 min. A complete postoperative reduction was observed in all patients with grade I and II SL, based on the Meyerding classification. Out of six patients with grade III SL, three had a complete postoperative reduction while the remaining three turned into grade I SL (Table 1).

The mean age of the patients with isthmic SL was significantly lower, compared with patients with degenerative SL (49.2 years vs 57.3 years; $P=0.026$). Also, the mean SVA correction was significantly less in isthmic SLs (10.3 mm vs 25.6 mm; $P=0.025$). Moreover, the mean PT correction was significantly less in isthmic SLs

(-1.1° vs 5.2°; $P=0.004$). No other significant difference was found between the isthmic and degenerative SLs.

The mean SVA and PT corrections did not significantly differ between multilevel and single-level SLs ($P=0.72$ and $P=0.52$, respectively). Yet, the mean blood loss was significantly higher in multilevel SL, compared with single-level SL (1150 mL vs 687.5 mL; $P=0.021$). No other significant difference was found between multilevel and single-level SLs.

The mean SVA correction was 11.6 mm, 15.8 mm, and 44.4 mm in grade I, II, and III SLs, respectively ($P=0.003$). Moreover, the mean PT correction did not significantly differ between the different grades of SL ($P=0.55$). The mean operation time was 171.7 min, 188.8 min, and 219.2 min in grade I, II, and III SLs, respectively ($P=0.041$). Also, the mean blood loss was 644.1 mL, 779.4 mL, and 858.3 mL in grade I, II, and III SLs, respectively ($P=0.005$). No other significant difference was found between the different grades of SL (Figure 1).

Surgical complications

Incidental durotomy occurred in three patients; they were repaired appropriately and caused no postoperative complications. Moreover, we recorded no case of cage related complication, junctional degeneration, neurological complications, and infection, in this series.

4. Discussion

There is no consensus regarding the benefit of augmenting an interbody fusion cage in the treatment of SL. Therefore, this study evaluated the effect of this augmentation on the postoperative sagittal balance and

Table 1. Comparison of pre and postoperative vas and the spinopelvic parameters of spondylolisthesis patients

Variable	Preoperative ^a	Postoperative ^a	P ^{**}
SVA (mm)	43.1±33.1	24.8±22.3	<0.001
Total kyphosis (°)	38.9±14.5	38.4±11.2	0.76
LL	53.8±12.7	53.2±11.7	0.72
PT	19.2±10	17±9.1	0.05
PI	55.4±12.3	56±10.4	0.45
VAS	9.1±0.8	2.8±1.2	<0.001

SVA: Sagittal Vertebral Axis; LL: Lumbar Lordosis; PT: Pelvic Tilt; PI: Pelvic Incidence; VAS: Visual Analog Scale;

^a The data are provided as Mean±SD;

^{**} The $P<0.05$ is considered significant.

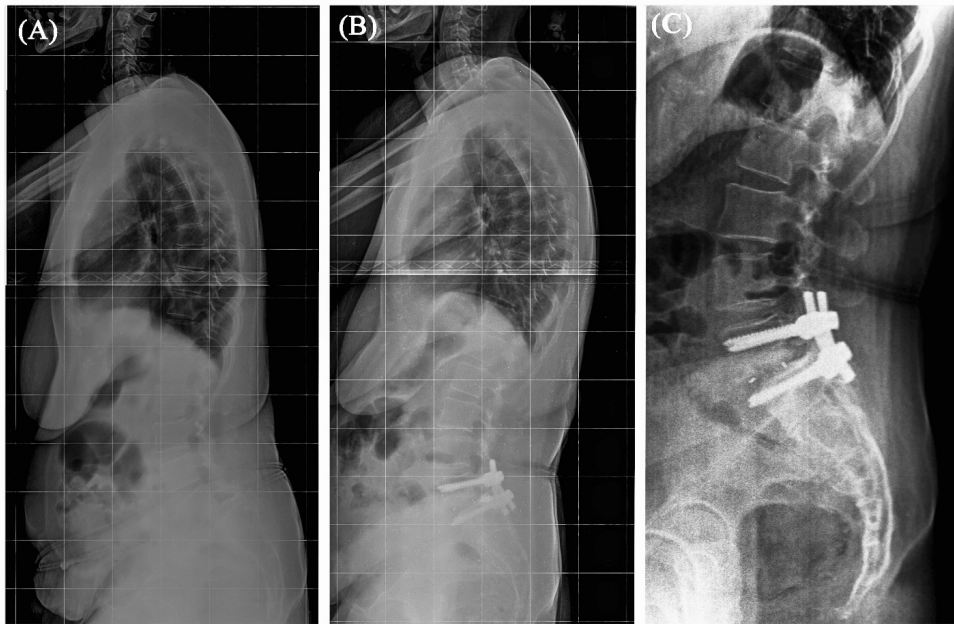


Figure 1. Posterior spinal fusion and instrumentation in combination with interbody fusion cage

A: Preoperative; B and C: Postoperative; Standing lateral radiographs of a 59-year-old female with L5-S1 degenerative spondylolisthesis and sagittal imbalance; The correction of sagittal balance is obvious in the postoperative images

pain level of the SL patients. According to our results, the interbody fusion cage significantly reduces the pain and improves the postoperative spinopelvic parameters, particularly SVA and PT, in SL patients. Besides, degenerative SLs, single-level SLs, and the lower grades of SL benefit more from using an interbody fusion cage.

Suk et al. compared the outcome of SL surgery between 40 patients treated with posterolateral fusion without posterior lumbar interbody fusion and 36 patients treated with additional posterior lumbar interbody fusion. Their results showed that using interbody fusions were associated with higher rates of fusion, better correction, and the maintenance of correction. Also, the subjective assessment of back pain revealed excellent results in 45% of the posterolateral fusion group and 75% of the posterior lumbar interbody fusion group. The authors recommended the addition of posterior lumbar interbody fusion to posterolateral fusion for the treatment of spondylolytic SL with spinal stenosis [11].

Gottschalk et al. compared the clinical, radiographical, and cost/value of posterolateral fusion with interbody arthrodesis (111 patients) with those of posterolateral fusion without interbody fusion (68 patients), in the treatment of degenerative SL. The addition of an interbody fusion to posterolateral instrumentation caused an increased cost and no clinical benefit [12].

Ha et al. assessed the benefit of interbody fusion in stable versus unstable degenerative SL. Also, the stability was defined as the slip length of lower than 4 mm and a slip angle of lower than 10°. While using an interbody fusion did not affect the clinical outcomes in the stable group, it greatly improved the function and relieved the pain in the unstable group. The authors suggested to consider preoperative segmental instability to determine whether the interbody fusion would be beneficial in the treatment of degenerative SL [13].

Kashani et al. studied 60 SL patients treated with posterolateral fusion with or without transforaminal lumbar interbody fusion. The addition of an interbody fusion cage was associated with a significant increase in operative time, intraoperative blood loss, and the cost of surgery. Yet, no significant difference was observed in the Oswestry Disability Index, VAS, fusion rate, and the loss of the correction between the two study groups. The authors concluded that using an interbody fusion cage did not significantly improve the radiologic and clinical outcomes of surgery in SL patients [14].

Eghbal et al. determined the functional, clinical, and radiological outcomes of 50 patients with low grade SL, who were treated with single or double level transforaminal lumbar interbody fusion. After the surgery, the PI, PT, and sacral slope did not statistically change from the baseline. However, LL and segmental LL were significantly increased. Furthermore, both back and leg

VAS were significantly improved after the surgery [15]. Consistent with the present study, Eghbal et al. revealed that using an interbody fusion could improve both the spinopelvic and clinical parameters of the patients.

Yijian et al. compared the sagittal balance and clinical outcomes of patients with degenerative SL who were treated with posterolateral fusion and posterior lumbar interbody fusion. The scores of the numerical rating scale and the Oswestry Disability Index were significantly improved in both groups. However, the spinopelvic parameters were significantly restored only in the posterior lumbar interbody fusion group. Also, this group revealed less incidence of postoperative chronic low-back pain [16]. The results of this study supported the positive effect of interbody fusion on the spinopelvic parameters and the pain level of the SL patients.

In accordance with the study of Yijian et al., we revealed that the addition of an interbody fusion cage to posterolateral fusion significantly improved the spinopelvic parameters of the SL patients. The restoration of sagittal alignment is known as one of the determining factors in the success of spinal interventions [17]. Thus, our findings suggest the application of fusion interbody cage in the treatment of SL, even if it causes higher blood loss, operation time, and cost of the surgery.

The main limitation of this study was the absence of a control group treated with posterolateral fusion without an interbody fusion cage. Thus, future controlled studies are needed to shed more light on the implication of the interbody fusion cage in the postoperative spinopelvic parameters of SL patients.

Ethical Considerations

Compliance with ethical guidelines

All procedures performed in studies involving human participants were in accordance with the ethical standards of the institutional and/or national research committee and with the 1964 Helsinki declaration and its later amendments or comparable ethical standards.

Funding

This research did not receive any specific grant from funding agencies in the public, commercial, or not-for-profit sectors.

Authors' contributions

Study design: Hasan Ghandhari; Revision of the paper: Mohammadreza Chehrassan; Revision of the paper: Farshad Nikouei; Data interpretation: Mohammadreza Heidarkhoo; Writing the paper: Mohammadreza Shakeri.

Conflict of interest

The authors declared no conflict of interest.

References

- [1] Kalichman L, Kim DH, Li L, Guermazi A, Berkin V, Hunter DJ. Spondylolysis and spondylolisthesis: Prevalence and association with low back pain in the adult community-based population. *Spine*. 2009; 34(2):199-205. [DOI:10.1097/BRS.0b013e31818edcfd] [PMID] [PMCID]
- [2] Weinstein JN, Lurie JD, Tosteson TD, Hanscom B, Tosteson ANA, Blood EA, et al. Surgical versus nonsurgical treatment for lumbar degenerative spondylolisthesis. *N Engl J Med*. 2007; 356(22):2257-70. [DOI:10.1056/NEJMoa070302] [PMID] [PMCID]
- [3] Labelle H, Mac-Thiong JM, Roussouly P. Spinopelvic sagittal balance of spondylolisthesis: A review and classification. *Eur Spine J*. 2011; 20(5):641-6. [DOI:10.1007/s00586-011-1932-1] [PMID] [PMCID]
- [4] Tebet MA. Current concepts on the sagittal balance and classification of spondylolysis and spondylolisthesis. *Rev Bras Ortop*. 2014; 49(1):3-12. [DOI:10.1016/j.rbo.2013.04.011] [PMID] [PMCID]
- [5] Lamartina C, Berjano P, Petruzzi M, Sinigaglia A, Casero G, Cecchinato R, et al. Criteria to restore the sagittal balance in deformity and degenerative spondylolisthesis. *Eur Spine J*. 2012; 21(1):S27-31. [DOI:10.1007/s00586-012-2236-9] [PMID] [PMCID]
- [6] Vahid Tari SH, Ameri Mahabadi E, Ghandehari H, Nikouei F, Javaheri R, Safdari F. Spinopelvic sagittal alignment in patients with adolescent idiopathic scoliosis. *J Res Orthop Sci*. 2015; 2(3):e739. [DOI:10.17795/soj-739]
- [7] Spiker WR, Goz V, Brodke DS. Lumbar Interbody Fusions for Degenerative Spondylolisthesis: Review of Techniques, Indications, and Outcomes. *Global Spine J*. 2019; 9(1):77-84 [DOI:10.1177/2192568217712494] [PMID] [PMCID]
- [8] Eismont FJ, Norton RP, Hirsch BP. Surgical management of lumbar degenerative spondylolisthesis. *J Am Acad Orthop Surg*. 2014; 22(4):203-13. [DOI:10.5435/JAAOS-22-04-203] [PMID]
- [9] Steiger F, Becker H-J, Standaert CJ, Balague F, Vader J-P, Porchet F, et al. Surgery in lumbar degenerative spondylolisthesis: indications, outcomes and complications. A systematic review. *Eur Spine J*. 2014; 23(5):945-73. [DOI:10.1007/s00586-013-3144-3] [PMID]

- [10] Khalsa AS, Mundis GM, Ledesma JB, Hosseini P, Bruffey JD, Nguyen SN, et al. Radiographic and Surgical Outcomes After Stand-Alone Lateral Lumbar Interbody Fusion. *J Res Orthop Sci.* 2018; 5(3): e81419. [DOI:10.5812/soj.81419]
- [11] Suk SI, Lee CK, Kim WJ, Lee JH, Cho KJ, Kim HG. Adding posterior lumbar interbody fusion to pedicle screw fixation and posterolateral fusion after decompression in spondylolytic spondylolisthesis. *spine.* 1997; 22(2):210-9. [DOI:10.1097/00007632-199701150-00016] [PMID]
- [12] Gottschalk MB, Premkumar A, Sweeney K, Boden SD, Heller J, Yoon ST, et al. Posterolateral lumbar arthrodesis with and without interbody arthrodesis for L4-L5 degenerative spondylolisthesis: A comparative value analysis. *Spine.* 2015; 40(12):917-25. [DOI:10.1097/BRS.0000000000000856] [PMID]
- [13] Ha KY, Na KH, Shin JH, Kim KW. Comparison of posterolateral fusion with and without additional posterior lumbar interbody fusion for degenerative lumbar spondylolisthesis. *J Spinal Disord Tech.* 2008; 21(4):229-34. [DOI:10.1097/BSD.0b013e3180eaa202] [PMID]
- [14] Omid-Kashani F, Jalilian R, Golhasani-Keshtan F. Effect of interbody fusion cage on clinical and radiological outcome of surgery in L4-L5 lumbar degenerative spondylolisthesis. *J Spine Surg.* 2018; 4(1):109-14. [DOI:10.21037/jss.2018.03.17] [PMID] [PMCID]
- [15] Eghbal K, Pourabbas B, Abdollahpour HR, Mousavi R. Clinical, functional, and radiologic outcome of single-and double-level transforaminal lumbar interbody fusion in patients with low-grade spondylolisthesis. *Asian J Neurosurg.* 2019; 14(1):181-7. [DOI:10.4103/ajns.AJNS_156_18] [PMID] [PMCID]
- [16] Yijian Z, Hao L, Huilin Y, Bin P. Comparison of posterolateral fusion and posterior lumbar interbody fusion for treatment of degenerative spondylolisthesis: Analysis of spinopelvic sagittal balance and postoperative chronic low back pain. *Clin Neurol Neurosurg.* 2018; 171:1-5. [DOI:10.1016/j.clineuro.2018.04.020] [PMID]
- [17] Makhni MC, Shillingford JN, Laratta JL, Hyun SJ, Kim YJ. Restoration of sagittal balance in spinal deformity surgery. *J Korean Neurosurg Soc.* 2018; 61(2):167-79. [DOI:10.3340/jkns.2017.0404.013] [PMID] [PMCID]