



Short-Term Outcome of Shelf-Autograft in Uncemented Total Hip Arthroplasty

Ali Yeganeh¹, Mehdi Moghtadaei¹, Hosein Farahini¹ and Ehsan Shekarchizadeh^{1,2,*}

¹Department of Orthopedic Surgery, Rasool-e-Akram Hospital, Iran University of Medical Sciences, Tehran, Iran

²Bone and Joint Reconstruction Research Center, Shafa Orthopedic Hospital, Iran University of Medical Sciences, Tehran, Iran

*Corresponding author: Department of Orthopedic Surgery, Rasool-e-Akram Hospital, Iran University of Medical Sciences, Tehran, Iran. Email: imedinet@gmail.com

Received 2018 July 17; Revised 2018 September 24; Accepted 2018 September 28.

Abstract

Background: Management of acetabular bone defects, especially massive ones, is a challenging issue for surgeons during total hip arthroplasty (THA). Inadequate bone coverage can lead to weakness of acetabular component fixation and instability, and finally, failure of surgery. In recent decades, different techniques and methods have been reported in literature to manage these defects according to their size and location. However, the routine use of many of these new methods is impossible in the majority of patients because of existing financial limitations. The aim of the present study was to evaluate the clinical and radiographic outcomes of THA with acetabular defect reconstruction using shelf-autograft.

Methods: This study was designed and conducted in two phases of retrospective and prospective. Between 2012 and 2017, 423 THA surgeries were performed in two hospitals by senior surgeon. A total of 38 THA procedures using shelf autograft were performed. The short-term clinical and radiological results were evaluated in the present study.

Results: The mean coverage angle by graft was $45.5 \pm 7.3\%$ (range: 33 - 72%) and horizontal coverage percentage by graft was $79.3 \pm 12.8\%$ (range: 54 - 100%). After a mean follow-up of 26 months (range: 12 - 56 months), no evidence of instability was found in any of these hips. Considering loosening and revision as an end-point, the survival rate was 100%. The patients' mean Harris hip score (HHS) improved from a mean of 35.50 ± 9.11 preoperatively to 95.10 ± 4.71 at the last follow-up. Rigid fixation of graft to host bone, medial insertion of acetabular cementless cup, and avoidance of lateral or high hip center were found to result in excellent THA with shelf graft outcomes.

Conclusions: Despite the development of more advanced methods to manage acetabular defects during total hip replacement, using shelf-graft is a valuable and accessible strategy for hip surgeons, and by the use of suitable techniques, we can expect excellent outcomes even in massive defects.

Keywords: Shelf Graft, Shelf Autograft, Total Hip Arthroplasty, Total Hip Replacement, Acetabular Defect, Primary Total Hip Arthroplasty, Harris Hip Score, THA

1. Background

In total hip arthroplasty (THA), reconstruction of large-scale acetabular defects is often challenging for surgeons, in such a way that inadequate bone coverage causes a potentially unstable fixation of the acetabular component (1, 2).

Different techniques have been proposed for the reconstruction of these defects according to their size and location, and many of these methods are subject to limitations due to their high costs, especially in the developing countries.

Although good results have been reported for the use of autologous (autograft) bone grafts and for the reinforcement techniques with rings or metal plates, there is still no

consensus on the survival of graft after THA in dysplastic hips.

In this study, the short- and mid-term results of total hip replacement surgery using shelf-graft were studied during a period of seven years in two hospitals. In addition, the effectiveness of surgery, the incidence of postoperative complications, and the rate of success were examined through clinical and radiographic evaluations.

2. Methods

To perform this study, all patients who underwent primary total hip replacement surgery (regardless of etiology) and were candidates for shelf-graft due to acetabular bone defects during the years 2011 to 2017 were inves-

tigated. The inclusion criteria were total hip replacement surgery with shelf autograft.

2.1. Surgery Method

The modified Hardlinge lateral approach was used for all patients. After sufficient acetabular exposure and identifying the lower edge of the acetabular medial wall, where the transverse ligament is located, in the medial wall center, the sizes ranging from 44 mm to 2 mm below the best anteroposterior diameters were rimmed. In addition, the size of the acetabular defect was estimated after insertion of the trial cup.

In case of a defect of more than 30% of the surface, structural grafts from the femoral head (autograft) were used among patients with primary THA. At first, in the false acetabulum with a very large rimmer, the host site was decorticated. Then, the same area of the femoral head, which matched the defect, was used for grafting.

Fixation was performed after the graft was prepared at the appropriate place by means of two or three 3.5 cortical or cancellous screws depending on the bone density of the patient. Prior to placement of the main acetabular cup, acetabular rimming was continued until exposing the live bone. After ensuring of the lack of fluctuation instability and an appropriate stability in the test with the trial component, the uncemented main cup was placed.

In the clinical evaluations, the Harris hip score (HHS), as a valid scoring system (3), was used for evaluation before and after surgery in routine visits. Standard anteroposterior (AP) radiographs of the pelvis consisting of the two hips and lateral views of the operated hip (s) were analyzed in postoperative visits.

The vertical (V) and horizontal (H) positions of the hip center (Figure 1A), the length of the interface between the graft and the host bone (Figure 1H), the craniocaudal height and the mediolateral width of the grafts were measured in AP radiographs (Figure 1F and 1G).

Coverage angle (CA), the angle between the lateral edge of the host bone and the lateral edge of the acetabular component with the hip center, was measured in degrees in AP radiography (Figure 1I). Socket/graft CA percentage was calculated using the following equation: $(CA/180) \times 100$ (Figure 1J).

The horizontal coverage was determined by calculating the ratio of the cup horizontally covered by the graft to the total horizontal width of the cup as a percentage in AP radiographs (Figure 1K). The inclination angle of the socket was determined by the angle formed between the lateral face of the socket and the inter-teardrop line in AP radiography. When the inter-teardrop line was not clear, the trans-ischial line was used as an alternative (Figure 1C).

The distance from the Kohler line to the interior edge of the acetabular component was measured (Figure 1B). The vertical and horizontal positions of the acetabular socket were also determined according to the method described by Russotti and Harris (4).

The horizontal distance between the center of rotation and the teardrop and the vertical distance between the center of rotation and the inter-teardrop line were measured in millimeters in the radiographs immediately after the operation and on the last visit. The acetabular component fixation was evaluated in radiographs of postoperative follow-up visits using the Tompkins et al. method (5).

In case of creation of radiolucent lines in the interface between the bone and acetabular implant, AP radiographs of postoperative visits were recorded as described by DeLee and Charnley (6). Probable or definite loosening of the acetabulum was defined as a change in the socket position in the form of an inclination of more than 4 degrees, socket migration of more than 5 mm, loosening or fracture of the screw, or complete radiolucency in the bone-implant interface of 2 mm or more in each of three areas of DeLee and Charnley (6-10). The presence or absence of heterotopic ossification was evaluated among patients as described by Brooker et al. (11).

The results of the study were analyzed in SPSS, version 18.

3. Results

Of the 423 hips that underwent THA in the two hospitals from April 2011 to December 2017, 38 hips of 34 patients were investigated in the present study. Of the 34 patients studied, 12 and 22 were men and women, respectively, with a mean age of 47.4 years (age range: 17 - 70 years). The average follow-up period was 26 months, with a minimum and maximum follow-up of 12 and 56 months, respectively. Of the 34 patients, 19 and 15 had unilateral and bilateral hip involvements, respectively. In addition, of these patients, four patients had experienced THA with shelf-graft on both sides of the hip. During THA, 11 (29%) and 27 (71%) pelvises underwent and did not undergo trochanteric osteotomy, respectively. Table 1 demonstrates the incidence rate of various hip diseases in the subjects.

The results related to graft characteristics are provided in Table 2.

Union was observed in radiography among all the patients. The mean coverage angle percentage by graft was $45.5 \pm 7.3\%$ (range: 33 - 72%) and horizontal coverage percentage by graft was $79.3 \pm 12.8\%$ (range: 54 - 100%) after surgery. After a mean follow-up of 26 months (range: 12-56 months), no evidence of instability was found in any of

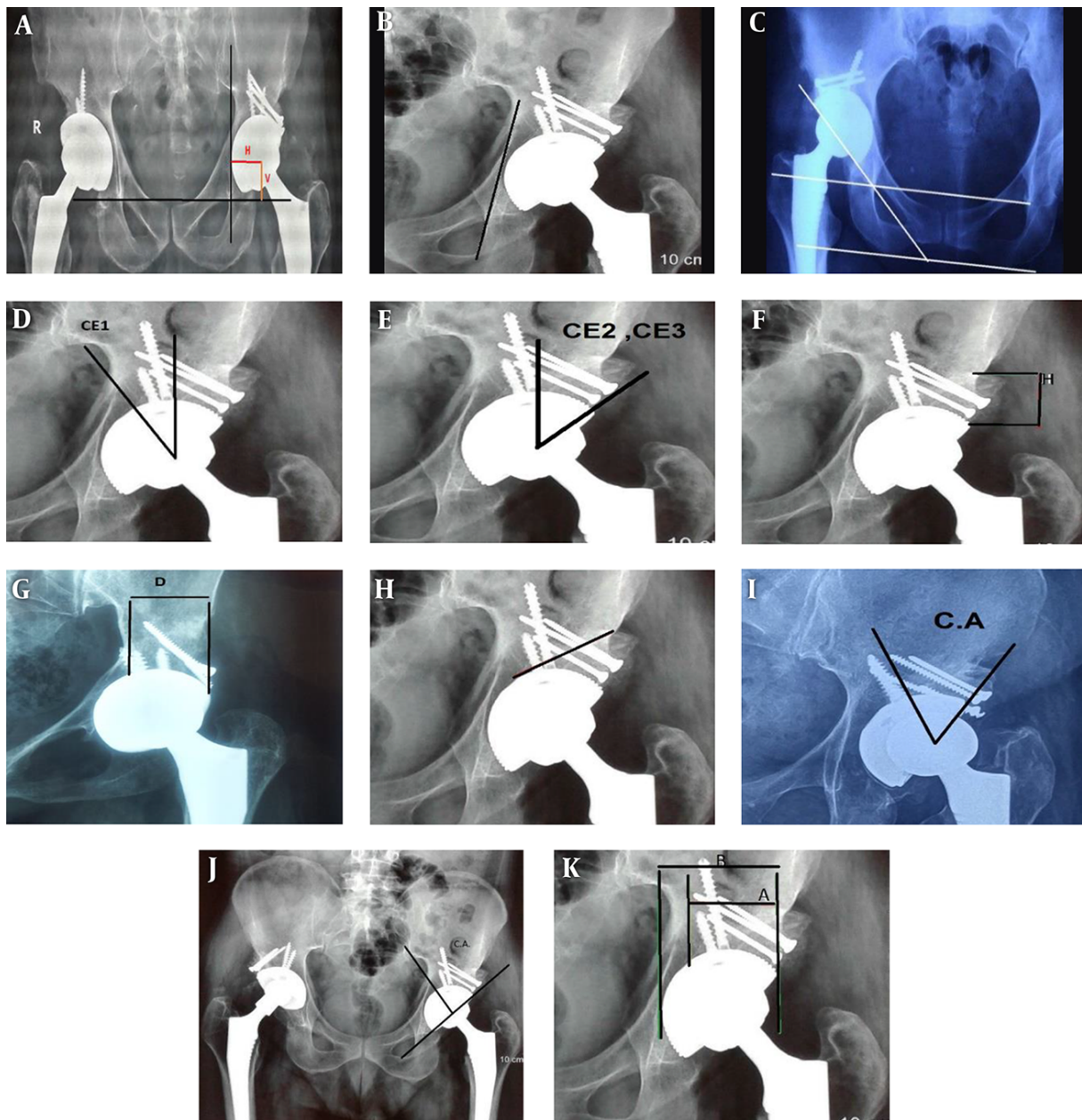


Figure 1. How the variables were measured. A, Determination of vertical (V) and horizontal (H) positions of the center of the hip; B, Cup distance to the Kohler line; C, Cup inclination angle and inter-teardrop and trans-ischial lines; D, Center-edge angle₁ (CE₁); E, Center edge angle₂ immediately after the operation (CE₂) and center edge angle₃ on the last visit (CE₃); F, Graft height; G, Graft width; H, Graft bone and host bone interface; I, Coverage angle (CA); J, Coverage angle (CA) and coverage angle percentage ($\frac{CA}{180} \times 100$); K, Horizontal coverage percentage ($\frac{A}{B} \times 100$)

these hips. Considering loosening and revision as an endpoint, the survival rate was 100%.

The patients' mean Harris hip score (HHS) improved from a mean of 35.50 ± 9.11 preoperatively to 95.10 ± 4.71 at the last follow-up, which showed a significant difference ($P = 0.0001$).

As to postoperative complications, there was only one case of dislocation two weeks after surgery, which was subjected to close reduction and it was not repeated. Only in one patient, radiolucency with a width of 1 to 2 mm was observed in zones I and II (DeLee and Charnley) around the acetabulum. There were no clinical symptoms at the

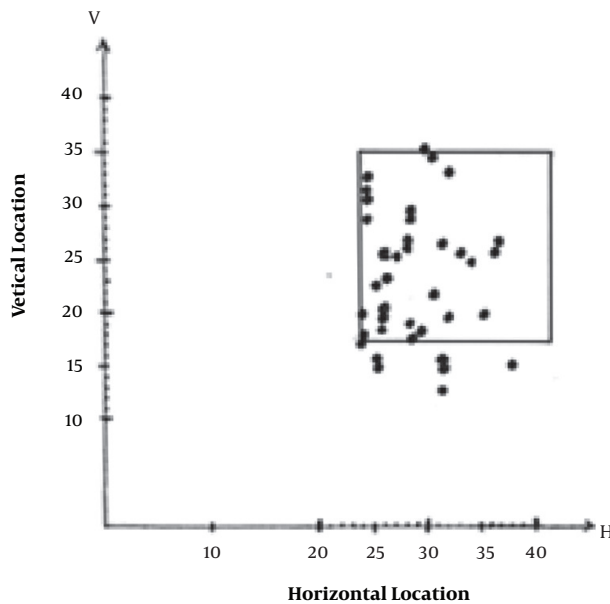


Figure 2. Center of rotation of hips after surgery. Exhibits the horizontal and vertical positions of the center of rotation of hips after surgery. Most hip centers were distributed over a certain range. The square is the ideal range of hip center in a normal THA according to the study by Russotti and Harris (4). However, the mean and the range of distribution of values of the above variables were 28.5 ± 3.8 mm (24 - 38) and 23.6 ± 6.1 mm (13 - 36) horizontally and vertically, respectively

patient’s bedside. No evidence of instability or displacement of the cup was found in the radiographs. Only one of the patients after the operation had leg length differences (LLD) of more than 2 cm, and she was also a candidate for THA surgery of her contralateral hip.

During the follow-up period, grade 3 heterotopic ossification, as described by Brooker et al. (11), was observed in one hip despite heterotopic ossification prophylaxis. In this patient, there was grade 3 heterotopic ossification before THA surgery in radiographs. He had a history of acetabulum fracture, open reduction internal fixation (ORIF), and failure of previous surgeries.

No other intraoperative and postoperative complica-

tions, including nerve injury, vascular injury, infection, thromboembolic disease, aseptic loosening, cup migration, socket breakout, periprosthetic fracture, and implant failure or fracture, were observed.

4. Discussion

In this study, the short- and mid-term outcomes of total hip replacement surgery using shelf-graft were evaluated. In the short-term investigation, a survival rate of 100% was obtained. In this study, larger grafts were used among the patients, while in other studies (1, 2, 10, 12), a smaller wedge-shaped cut of bone from the femoral head was used to fill the defects of the acetabulum.

Some previous studies have indicated good survival rates of grafts in the short term (13). In some others, less suitable results were obtained in the long term (7, 14). It was thought that failure was due to the larger size of the graft used. Jasty and Harris (15) and Shinar and Harris (14) believed that there was a correlation between the extent of graft coverage and the degree of loosening of the acetabular component, and the smaller the grafts, the higher the survival rates.

The use of a high hip center has the advantage of reducing the complexity of surgery by spending normal and bone stock biomechanics for possible future revisions (4, 16). Studies have yielded contradictory results on this approach. Some studies have reported high loosening rates (16), while some others have presented more favorable results (4).

High costs in the manufacturing process and financial constraints are influential factors limiting the use of highly porous metal cups with augmentation. Principally, autografts are preferable to allografts because of their high incorporation capacity (17). However, in cases of revision, since autografts are not always available, allograft bone is widely used to rebuild acetabular defects.

In the present study, the average distance of the acetabular component from the Kohler line was 1.8 mm. In a previous study (18), the average distance between the Kohler line and the medial margin of the acetabular component in radiographs was about 6.1 mm. They believed that one of the important reasons for the success of THA using a shelf-graft was the use of the acetabular component near the Kohler line. This method increases the contact surface of the component with the host bone. Iida et al. (19) reported that the lateral placement of the acetabular component is one of the risk factors for loosening.

Some authors believe that cup stability dependence with more than 60% graft bone should be avoided to prevent stress on the graft bone to the extent possible (7). However, in 36 out of the 38 hips studied, horizontal coverage

Table 1. Incidence Rate of Various Hip Diseases

Variable	Rate	%
DDH	24	63
Unknown etiology	5	13
AVN	4	11
Acetabulum fractures	3	8
Infection	2	5

Abbreviations: AVN, avascular necrosis; DDH, developmental dysplasia of the hip.

Table 2. Graft Characteristics and Comparison of Changes in Other Radiographic Variables of the Patients Immediately After Surgery with the Last Visit

Variable, mm	Lowest	Highest	Mean \pm SD	P Value
Size of cup, mm	42	58	51.4 \pm 3.8	
Cup to Kohler distance, mm	-3	9	1.18 \pm 2.6	
Host/graft contact area, mm	27	58	44.5 \pm 7.8	
Center-edge angle 1, degree (Figure 1D)	-82	-14	-35.7 \pm 12.2	
Graft height, mm				0.32
After surgery	14	50	27.9 \pm 9.25	
Final visit	13	50	27.9 \pm 9.33	
Graft width, mm				0.32
After surgery	16	58	43.2 \pm 9.48	
Final visit	16	58	43.1 \pm 9.57	
Horizontal coverage percentage, %				0.32
After surgery	54	100	79.3 \pm 12.18	
Final visit	54	100	79.1 \pm 12.47	
Coverage angle percentage, %				0.32
After surgery	33	72	45.1 \pm 7.35	
Final visit	32	72	44.9 \pm 7.62	
Coverage angle, deg				0.32
After surgery	60	130	81.8 \pm 13.05	
Final visit	60	130	81.4 \pm 13.46	
Socket inclination				0.32
After surgery	40	60	45 \pm 3.24	
Final visit	40	60	45 \pm 3.24	

Abbreviation: SD: standard deviations.

percentage was higher than 60% with a mean transverse coverage of 79.3%, and no significant change was observed in the last follow-up radiographs. Among patients of the present study, the overall stability of the acetabular cup and graft integrity were investigated until the last follow-up. Adequate bone graft stability was 100%.

In the present study, 85% of hip centers were located in the square area defined by Russotti and Harris (4). There was no case of high hip center. The key factor for the stability of the acetabular cup in dysplastic hip reconstruction is the anatomical and biomechanical relationships of the components (20, 21). The insertion of the acetabular component in the appropriate location of the center of rotation along with the acetabular angle, degree of anteversion in the appropriate condition, and ideal cup coverage are essential to achieve this goal. Therefore, various surgical techniques have been developed and published.

Considering several key factors, in addition to the discussed cases, can result in a success rate of 100% in the short-term outcomes of the patients:

1. Placing the cup in a medial position closer to the Kohler line,
2. Careful placement of the hip center in the anatomical area and avoidance of high hip center,
3. Correct fixation of graft with 2 to 3 cortical or cancellous screws, depending on bone quality,
4. Use of uncemented acetabulum components for all patients.

Concurrent application of these cases led to excellent results among the patients under study, despite the high percentage of coverage of the cup by graft, namely 45.5% angular coverage percentage and 79.3% horizontal coverage percentage, which are significantly higher than similar studies.

Finally, this study showed that despite the development of new methods to compensate for the defects of the acetabulum in total hip replacement, due to the high cost of these prostheses, especially in the developing countries faced with limited funding and construction technology, the use of shelf-graft is still a worthwhile solution for these

patients. Furthermore, one can ensure the success of this process by observing the technical points that have been recognized in the process of upgrading this method, even in cases with massive defects.

The limitations of this study included the absence of a control group, necessity of a relatively long-term follow-up to investigate the structural graft lifetime, the use of uncemented cups, and the impossibility of generalizing the results to cement cups. Computed tomography (CT) scan during or after follow-up was only performed in some patients, which, if performed in future studies, is likely to provide us with additional information. These patients will be followed up to study long-term outcomes among them.

References

- Ho KT, Wong KY. Use of structural bone graft for reconstruction of acetabular defects in primary total hip arthroplasty: A 13-year experience. *J Orthop Trauma Rehabil.* 2016;**20**:30-4. doi: [10.1016/j.jotr.2015.06.002](https://doi.org/10.1016/j.jotr.2015.06.002).
- de Jong PT, Haverkamp D, van der Vis HM, Marti RK. Total hip replacement with a superolateral bone graft for osteoarthritis secondary to dysplasia: A long-term follow-up. *J Bone Joint Surg Br.* 2006;**88**(2):173-8. doi: [10.1302/0301-620X.88B2.16769](https://doi.org/10.1302/0301-620X.88B2.16769). [PubMed: 16434519].
- Harris WH. Traumatic arthritis of the hip after dislocation and acetabular fractures: Treatment by mold arthroplasty. An end-result study using a new method of result evaluation. *J Bone Joint Surg Am.* 1969;**51**(4):737-55. doi: [10.2106/00004623-196951040-00012](https://doi.org/10.2106/00004623-196951040-00012). [PubMed: 5783851].
- Russotti GM, Harris WH. Proximal placement of the acetabular component in total hip arthroplasty. A long-term follow-up study. *J Bone Joint Surg Am.* 1991;**73**(4):587-92. doi: [10.2106/00004623-199173040-00016](https://doi.org/10.2106/00004623-199173040-00016). [PubMed: 2013598].
- Tompkins GS, Jacobs JJ, Kull LR, Rosenberg AG, Galante JO. Primary total hip arthroplasty with a porous-coated acetabular component. Seven-to-ten-year results. *J Bone Joint Surg Am.* 1997;**79**(2):169-76. doi: [10.2106/00004623-199702000-00002](https://doi.org/10.2106/00004623-199702000-00002). [PubMed: 9052536].
- DeLee JG, Charnley J. Radiological demarcation of cemented sockets in total hip replacement. *Clin Orthop Relat Res.* 1976;**121**:20-32. doi: [10.1097/00003086-197612000-00003](https://doi.org/10.1097/00003086-197612000-00003). [PubMed: 991504].
- Mulroy RD, Jr, Harris WH. Failure of acetabular autogenous grafts in total hip arthroplasty. Increasing incidence: A follow-up note. *J Bone Joint Surg Am.* 1990;**72**(10):1536-40. doi: [10.2106/00004623-199072100-00017](https://doi.org/10.2106/00004623-199072100-00017). [PubMed: 2254363].
- Spanghel MJ, Berry DJ, Trousdale RT, Cabanela ME. Uncemented acetabular components with bulk femoral head autograft for acetabular reconstruction in developmental dysplasia of the hip: Results at five to twelve years. *J Bone Joint Surg Am.* 2001;**83**-A(10):1484-9. doi: [10.2106/00004623-200110000-00004](https://doi.org/10.2106/00004623-200110000-00004). [PubMed: 11679597].
- Oommen AT, Krishnamoorthy VP, Poonnoose PM, Korula RJ. Fate of bone grafting for acetabular defects in total hip replacement. *Indian J Orthop.* 2015;**49**(2):181-6. doi: [10.4103/0019-5413.152462](https://doi.org/10.4103/0019-5413.152462). [PubMed: 26015607]. [PubMed Central: PMC4436484].
- Kim M, Kadowaki T. High long-term survival of bulk femoral head autograft for acetabular reconstruction in cementless THA for developmental hip dysplasia. *Clin Orthop Relat Res.* 2010;**468**(6):1611-20. doi: [10.1007/s11999-010-1288-6](https://doi.org/10.1007/s11999-010-1288-6). [PubMed: 20309659]. [PubMed Central: PMC2865593].
- Brooker AF, Bowerman JW, Robinson RA, Riley LH, Jr. Ectopic ossification following total hip replacement. Incidence and a method of classification. *J Bone Joint Surg Am.* 1973;**55**(8):1629-32. doi: [10.2106/00004623-197355080-00006](https://doi.org/10.2106/00004623-197355080-00006). [PubMed: 4217797].
- Ito H, Matsuno T, Minami A, Aoki Y. Intermediate-term results after hybrid total hip arthroplasty for the treatment of dysplastic hips. *J Bone Joint Surg Am.* 2003;**85**-A(9):1725-32. doi: [10.2106/00004623-200309000-00011](https://doi.org/10.2106/00004623-200309000-00011). [PubMed: 12954831].
- Delimar D, Bicanic G, Pecina M, Korzinek K. Acetabular roof reconstruction with pedicled iliac graft: Early clinical experience. *Int Orthop.* 2004;**28**(5):319-20. doi: [10.1007/s00264-004-0555-0](https://doi.org/10.1007/s00264-004-0555-0). [PubMed: 15057487]. [PubMed Central: PMC3456979].
- Shinar AA, Harris WH. Bulk structural autogenous grafts and allografts for reconstruction of the acetabulum in total hip arthroplasty. Sixteen-year-average follow-up. *J Bone Joint Surg Am.* 1997;**79**(2):159-68. doi: [10.2106/00004623-199702000-00001](https://doi.org/10.2106/00004623-199702000-00001). [PubMed: 9052535].
- Jasty M, Harris WH. Salvage total hip reconstruction in patients with major acetabular bone deficiency using structural femoral head allografts. *J Bone Joint Surg Br.* 1990;**72**(1):63-7. doi: [10.1302/0301-620X.72B1.2298796](https://doi.org/10.1302/0301-620X.72B1.2298796). [PubMed: 2298796].
- Pagnano W, Hanssen AD, Lewallen DG, Shaughnessy WJ. The effect of superior placement of the acetabular component on the rate of loosening after total hip arthroplasty. *J Bone Joint Surg Am.* 1996;**78**(7):1004-14. doi: [10.2106/00004623-199607000-00004](https://doi.org/10.2106/00004623-199607000-00004). [PubMed: 8698717].
- Tian JL, Sun L, Hu RY, Tian XB. Cementless total hip arthroplasty with structural allograft for massive acetabular defect in hip revision. *Chin J Traumatol.* 2014;**17**(6):331-4. [PubMed: 25471427].
- Yamaguchi T, Naito M, Asayama I, Shiramizu K. Cementless total hip arthroplasty using an autograft of the femoral head for marked acetabular dysplasia: Case series. *J Orthop Surg (Hong Kong).* 2004;**12**(1):14-8. doi: [10.1177/230949900401200104](https://doi.org/10.1177/230949900401200104). [PubMed: 15237116].
- Iida H, Matsusue Y, Kawanabe K, Okumura H, Yamamuro T, Nakamura T. Cemented total hip arthroplasty with acetabular bone graft for developmental dysplasia. Long-term results and survivorship analysis. *J Bone Joint Surg Br.* 2000;**82**(2):176-84. doi: [10.1302/0301-620X.82B2.0820176](https://doi.org/10.1302/0301-620X.82B2.0820176). [PubMed: 10755422].
- Bicanic G, Delimar D, Delimar M, Pecina M. Influence of the acetabular cup position on hip load during arthroplasty in hip dysplasia. *Int Orthop.* 2009;**33**(2):397-402. doi: [10.1007/s00264-008-0683-z](https://doi.org/10.1007/s00264-008-0683-z). [PubMed: 19015852]. [PubMed Central: PMC2899080].
- Traina F, De Fine M, Biondi F, Tassinari E, Galvani A, Toni A. The influence of the centre of rotation on implant survival using a modular stem hip prosthesis. *Int Orthop.* 2009;**33**(6):1513-8. doi: [10.1007/s00264-008-0710-0](https://doi.org/10.1007/s00264-008-0710-0). [PubMed: 19099304]. [PubMed Central: PMC2899177].