



The Outcome of Elbow Release Surgery in Patients with Elbow Stiffness Caused by Different Etiologies

Hooman Shariatzadeh¹, Farid Najd Mazhar¹, Reza Babaei¹, Roozbeh Taghavi¹ and Hamidreza Dehghani^{1,*}

¹Bone and Joint Reconstruction Research Center, Shafa Orthopedic Hospital, Iran University of Medical Sciences, Tehran, Iran

*Corresponding author: Bone and Joint Reconstruction Research Center, Shafa Orthopedic Hospital, Iran University of Medical Sciences, Tehran, Iran. Email: drhrdehghani@yahoo.com

Received 2018 December 28; Accepted 2019 January 07.

Abstract

Background: Elbow stiffness is a debilitating condition with different etiologies including trauma, head injury, and burns, which seriously interferes with the patient's daily activities.

Objectives: Here, we aimed to report the outcome of elbow release surgery in patients with elbow stiffness caused by different etiologies.

Methods: In a retrospective study, the outcome of surgery was evaluated in 18 patients with elbow stiffness. The indication for surgery was the functional loss of elbow range of motion that failed at least six months of conservative management. Elbow range of motion was evaluated before and after the surgery. Mayo elbow performance score (MEPS) was used to assess elbow function at the final follow-up session.

Results: The mean follow-up period of the patients was 4.5 ± 2.6 years, ranging from 2 to 10 years. The etiology of stiffness was trauma in 11 cases, central nervous system injury in six patients, and burns in one patient. The mean pre-operative supination, pronation, and flexion arc improved by 15.3° , 20.9° , and 62.2° at the final follow-up evaluation, respectively ($P = 0.028$, $P = 0.008$, and $P < 0.001$, respectively). The mean MEPS of the patients was 85 ± 9.1 , ranging from 65 to 95. According to the MEPS scores, the functional outcome was excellent in 8 (44.4%) patients, good in 7 (38.9%) patients, and fair in 3 (16.7%) patients.

Conclusions: The release of stiff elbow could be regarded as an effective treatment that provides an acceptable gain in the range of motion and considerable improvement of elbow function.

Keywords: Elbow Stiffness, Range of Movement, Functional Outcome

1. Background

Elbow range of motion is necessary for proper function of the upper extremity. Yet, elbow joint is prone to stiffness following plenty of traumatic and atraumatic etiologies (1, 2). Elbow stiffness is a debilitating condition that interferes with daily activities and imposes many difficulties to the affected patients (3). Trauma is the most common cause of stiffness in the elbow joint. Contracture of soft tissue following elbow trauma, most especially the capsule, is observed in patients with severe elbow stiffness (4). Head injuries and burns are the other causes of elbow stiffness. Myositis ossificans (MO) is a frequent reason for elbow joint stiffness that is seen in a great percentage of patients following head injury, elbow injury, and burns (5). Elbow stiffness may also be secondary to heterotopic ossification (HO) (6) that frequently develops around the el-

bow following head injury, burns, surgery, and most commonly, direct trauma (7).

The timing of presentation, the progression of symptoms, and pre-injury functional level are the factors that could influence the treatment process and must be reviewed for proper decision-making. Assessment of the specific structures directs the development of an effective treatment program as well. Nonoperative management is performed with elbow splinting or manipulation under anesthesia (8). Static progressive and dynamic elbow splinting could also be used to regain elbow motion (8). In case nonoperative treatment fails, operative treatment could be considered, provided that the patient shows the motivation and ability to complete a challenging long-term rehabilitation program. The surgical approach to elbow stiffness must address all the pathologic structures inhibiting proper elbow motion (9, 10).

2. Objectives

In this study, we aimed to report the outcome of elbow release surgery in patients with elbow stiffness following trauma, head (central nervous system) injury, or burns.

3. Methods

This study was approved by the review board of our center and written consent was obtained from patients before participation in the study. In a retrospective design, patients with elbow stiffness who were referred to our center from October 2007 to January 2017 were reviewed and patients who were managed surgically were included in the study. The indication for surgery was the functional loss of elbow range of motion (elbow flexion of $< 100^\circ$) (5) that failed at least six months of conservative therapy (11). Patients with no motivation or inability to complete the rehabilitation program were excluded from the study. Patients with the age of less than 18 years and follow-up of less than six months were excluded from the study as well.

Radiographic evaluation of the elbow was performed by an orthopedic fellow. In this respect, plain radiographs of anteroposterior and lateral views were used to see joint congruity, osteophytes loose bodies, and myositis mass. A computed tomography (CT) scan was obtained to better delineate the diagnosis. Pre-, intra- and post-operative range of motion was assessed by a large hand-held goniometer, the validity of which was confirmed in an earlier investigation (12). Elbow performance was scored using the mayo elbow performance score (MEPS), where a score of 90 to 100 was considered as the excellent functional outcome, and scores of 75 to 89, 60 to 74, and < 60 were regarded as the good, fair, and poor functional outcome, respectively (13).

3.1. Surgical Technique

After precise radiographic evaluation of the case, elbow release surgery was planned for patients based on their indications. All the surgeries were performed with two surgeons (Hooman Shariatzadeh and Farid Najd Mazhar). The surgeries were performed in supine position, under general anesthesia, and with the use of a tourniquet. The site of skin incision was determined considering the factors such as the site of the HO, the location of previous incision (if available), and the presence of ulnar neuropathy. Accordingly, a lateral, medial or both skin incisions were used based on the patients' clinical picture and radiographic characteristics. In patients with HO, its extent was defined initially. A sufficient amount of HO was resected

to release the movement of the elbow. Capsular release was performed afterwards if a persistent deficit of flexion or extension was present. Posterior capsulectomy was carried out in all the patients. Anterior capsulectomy was performed in case of persistent extension limitation. The anterior band of the medial collateral ligament and the lateral collateral ligament were always preserved.

Tenotomy or lengthening of the biceps, triceps or brachialis muscles was not required in any of the patients. In patients with pre-operative ulnar nerve symptoms, or in those the nerve was found to be entrapped at operation, the ulnar nerve was released with or without transposition. Finally, the elbow was passively flexed and extended to assess the range of movement. After the release of the tourniquet and obtaining hemostasis, the wound was closed with suction drainage. Subsequently, a long-arm splint was applied with the elbow in the appropriate extension or flexion based on the direction of the major limitation (the direction in which the movement was more resistant to passive manipulation) or in 90° of flexion if there was no major direction of limitation. Hinged external fixator was not used as the collateral ligaments were not damaged in any of the cases after the release of the elbow. Figures 1 and 2 demonstrate the pre-operative and post-operative radiographs of two patients with traumatic and atraumatic elbow stiffness, respectively.

3.2. Post-Operative Protocol

All the patients received a 75 mg of sustained release prophylactic indomethacin once a day for six weeks. Elbow range of movement was begun the day after the surgery, which included active-assisted and passive flexion and extension exercises of the elbow. A night splint was used with the elbow in the maximum flexion or extension that was discontinued within two to three weeks after the surgery. The post-operative elbow range of motion and MEPS were assessed at the final follow-up session.

3.3. Statistical Analysis

SPSS was used for the statistical analysis. The data are presented as mean \pm standard deviation (SD) or number and percentage. Comparison of the mean difference between the preoperative and postoperative range of motions was carried out with paired *t*-test or its non-parametric counterpart (Wilcoxon signed-rank test). P value of less than 0.05 was considered statistically significant.

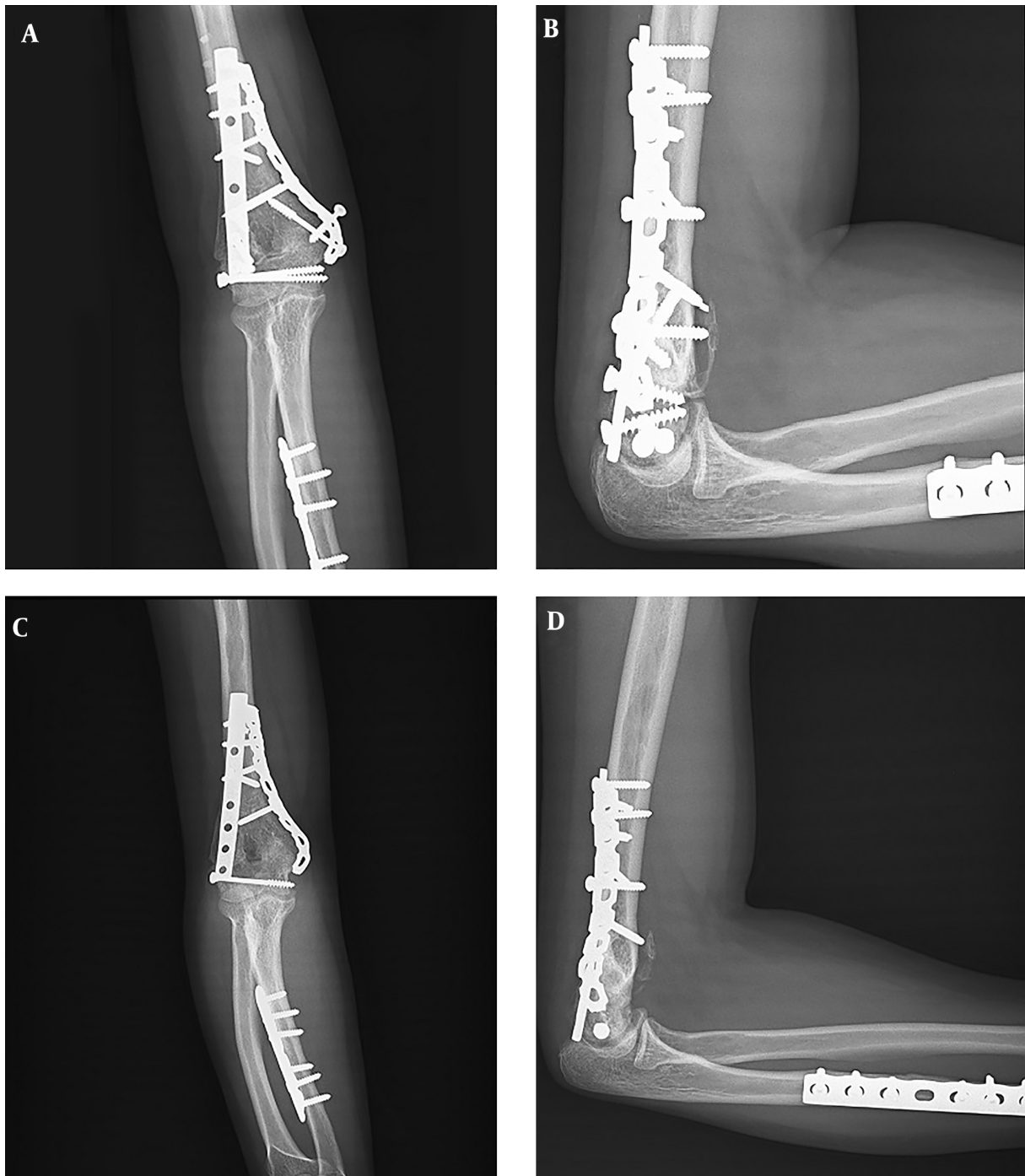


Figure 1. A, anteroposterior and B, lateral pre-operative radiographs of a patient with traumatic elbow stiffness; C, anteroposterior and D, lateral post-operative radiographs of the same patient

4. Results

Of 31 patients who underwent elbow release surgery, 18 were eligible for the final assessment and were included

in the study. The mean age of the patients was 34.05 ± 7 years, ranging from 22 to 48 years. The etiology of injury was trauma in 11 cases, central nervous system injury in

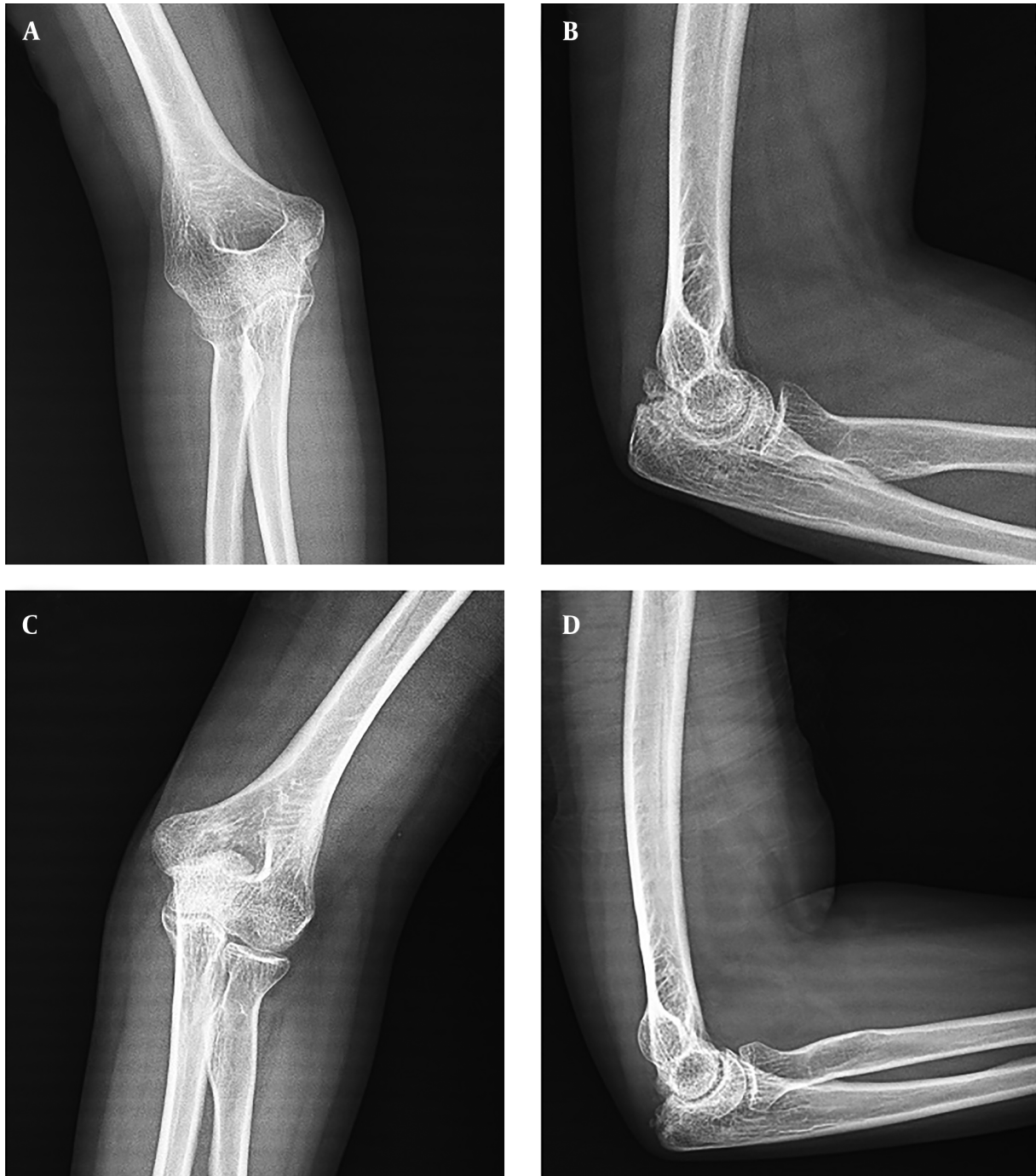

Figure 2. A, anteroposterior and B, lateral pre-operative radiographs of a patient with atraumatic elbow stiffness; C, anteroposterior and D, lateral post-operative radiographs of the same patient

six patients, and burns in one patient. The mean time period from the diagnosis to the surgery was 14 ± 6.4 months, ranging from 5 to 24 months. The mean follow-up period

of the patients was 4.5 ± 2.6 years, ranging from 2 to 10 years. The clinical and demographic characteristics of the patients are demonstrated in [Table 1](#).

Table 1. The Clinical and Demographic Characteristics of the Patients Who Underwent Elbow Release Surgery (N = 18)^a

| Variable | Values |
|---|--------------|
| Age, y | 34.05 ± 7 |
| Gender | |
| Male | 12 (66.7) |
| Female | 6 (33.3) |
| Hand dominance | |
| Dominant | 8 (44.4) |
| Non-dominant | 10 (55.6) |
| Time from detection to surgery, mo | 14 ± 6.4 |
| Etiology | |
| Trauma | 11 (61.1) |
| Central nervous system injury | 6 (33.3) |
| Burns | 1 (5.6) |
| Follow-up, y | 4.5 ± 2.6 |
| Pre-operative ROM, ° | |
| Supination | 47.2 ± 39.9 |
| Pronation | 44.4 ± 32.6 |
| Flexion arc | 22.2 ± 21.6 |
| Intra-operative ROM, ° | |
| Supination | 65.6 ± 25.7 |
| Pronation | 68 ± 6.2 |
| Flexion arc | 111.4 ± 12.7 |
| Post-operative ROM, ° | |
| Supination | 62.5 ± 32.2 |
| Pronation | 65.3 ± 12.9 |
| Flexion arc | 84.4 ± 17.4 |
| MEPS | 85 ± 9.1 |

Abbreviations: MEPS, mayo elbow performance score; ROM, range of motion.

^aValues are expressed as mean ± SD or No. (%).

The means of pre-operative, intra-operative, and post-operative supination, pronation, and flexion arc are demonstrated in Table 1. The differences between the mean pre-operative and post-operative (final follow-up) supination, pronation, and flexion were statistically significant ($P = 0.028$, $P = 0.008$, and $P < 0.001$, respectively). In this respect, a 15.3° improvement in the mean supination, a 20.9° improvement in the mean pronation, and a 62.2° improvement in the mean flexion arc was recorded.

The mean intra-operative supination, pronation, and flexion arc revealed a 3.1°, 2.7°, and 27° reduction at the final evaluation, while the means of intraoperative supination and pronation were not significantly different from

the means of post-operative supination and pronation ($P = 0.41$ and $P = 0.33$, respectively). The mean post-operative flexion arc was significantly lower than the mean intra-operative flexion arc ($P < 0.001$).

The mean MEPS of the patients was 85 ± 9.1, ranging from 65 to 95. According to the MEPS scores, the functional outcome was excellent in 8 (44.4%) patients, good in 7 (38.9%) patients, and fair in 3 (16.7%) patients.

4.1. Post-Operative Complications

Superficial infection occurred in two patients that were managed with antibiotics. Post-operative transient paresthesia of the ulnar nerve was observed in one patient. No recurrence of stiffness was observed in our cohort that could be attributed to the good adherence of the patients to the rehabilitation protocol. No case of post-operative HO was seen in our patients, as well.

5. Discussion

Surgical intervention in elbow stiffness is generally indicated for patients who present less than 100° of flexion-extension or 50° to -50° of pronosupination (5). Several surgical methods have been introduced in the literature. Whatever technique is used, the final goal would be to gain a range of motion that provides a functional limb (> 100° flexion-extension) (14).

Here, we reported the long-term outcome of open release in 24 patients with a stiff elbow. Our final follow-up analysis revealed a 15.3°, 20.9°, and 62.2° improvement in the mean pre-operative supination, pronation, and flexion arc. The function of the elbow at the final evaluation was excellent in eight patients, good in seven patients, and fair in three patients. It is worth mentioning that the mean intra-operative range of motion, specifically flexion arc, was reduced considerably as the time passed, as the mean final post-operative flexion arc was 27° lower than the mean intra-operative flexion arc.

The outcome of elbow release surgery using different techniques and approaches has been reported by many authors. Othman et al. evaluated the outcome of open elbow release in 16 patients with post-traumatic elbow stiffness (15). The mean time interval between the detection of stiffness and surgical release was 8.3 months. At a mean follow-up of 8.5 months, the total flexion/extension arc of their patients improved from a mean of 40° to 105° (gain of 65°). The mean preoperative MEPS was 60 points that improved to 85 ± 6 points (gain of 25 points). Accordingly, a satisfactory functional outcome was seen in 81.25% of cases (15).

The flexion/extension arc of our patients improved from a mean value of 25.9° to 86.6° that was comparable with the results of Othman et al. Although we did not assess the preoperative MEPS in our patients, the post-operative MEPS was excellent or good in the 82.6% of the patients. This result was in accordance with the results of Othman et al. as well. One recurrence of elbow stiffness was reported in the study of Othman et al. that occurred in an old patient who did not complete the rehabilitation program. This further highlights the role of patient's motivation and cooperation in the outcome of release surgery of stiff elbow. As we excluded the non-motivated patients from the study, no case of recurrence was observed in our series.

Tan et al. retrospectively reviewed the profile of 52 patients who underwent open surgical treatment for post-traumatic elbow stiffness (16). At an average follow-up of 18.7 months, the mean extension-flexion arc of their patients improved from 57° to 116° and forearm rotation improved from 119° to 145°. Five patients needed a second elbow release surgery at an average of 12 months after the index surgery. Painful motion or elbow instability led to the failure of surgery in four patients (16). Second elbow contracture release was not needed in any of our patients. Moreover, the surgery did not fail in any of our patients.

Park et al. evaluated the outcome of surgical elbow release in 27 patients with post-traumatic stiffness at a mean of 14.5 months. The elbow arc of movement improved in all patients following the surgery. The mean final arc was 110° in patients with HO and 86° in those without HO. The gain of motion was also significantly higher in patients with HO. They concluded that the careful assessment of the cause of stiffness is critical to achieving a satisfactory result from surgery (17).

Many other studies have also reported the outcome of release surgery with different approaches for the treatment of elbow stiffness (18-21). The favorable results of surgical procedures to address the extrinsic and/or intrinsic causes of elbow contracture have been reported in the majority of these investigations. It could be concluded that the release of stiff elbow provides an acceptable gain in the range of motion and considerable improvement of elbow function, especially in motivated cooperative patients. Yet, it is recommended to discuss it with patients in order to avoid disappointment due to unexpected events and outcomes. Although the range of motion could be reduced as the time passes, the considerable improvement in the post-operative range of motion still warrants performing elbow release surgery in patients with the required indications.

There are several limitations to the current study. This

study was a retrospective review with all the shortcomings that are attributed to this type of study. Due to the small number of patients, patients with different etiologies were included in the study that could be regarded as a cause of heterogeneity. Finally, the limited sample size did not allow the multivariate analysis of the results.

Footnotes

Conflict of Interests: The authors declare no conflict of interests.

Ethical Considerations: This study was approved by the review board of our center and written consent was obtained from the patients before participation in the study.

Funding/Support: None.

References

1. Najd Mazhar F, Jafari D, Mirzaei A. Evaluation of functional outcome after nonsurgical management of terrible triad injuries of the elbow. *J Shoulder Elbow Surg.* 2017;**26**(8):1342-7. doi: [10.1016/j.jse.2017.05.012](https://doi.org/10.1016/j.jse.2017.05.012). [PubMed: [28734536](https://pubmed.ncbi.nlm.nih.gov/28734536/)].
2. Mazhar FN, Ebrahimi H, Jafari D, Mirzaei A. Radial head resection versus prosthetic arthroplasty in terrible triad injury: A retrospective comparative cohort study. *Bone Joint J.* 2018;**100-B**(11):1499-505. doi: [10.1302/0301-620X.100B11.BJJ-2018-0293.R1](https://doi.org/10.1302/0301-620X.100B11.BJJ-2018-0293.R1). [PubMed: [30418065](https://pubmed.ncbi.nlm.nih.gov/30418065/)].
3. Abbott LC, Carpenter WF. Surgical approaches to the knee joint. *J Bone Joint Surg.* 1945;**27**(2):277-310.
4. Morrey BF. Surgical treatment of extraarticular elbow contracture. *Clin Orthop Relat Res.* 2000;**370**:57-64. doi: [10.1097/00003086-200001000-00007](https://doi.org/10.1097/00003086-200001000-00007). [PubMed: [10660702](https://pubmed.ncbi.nlm.nih.gov/10660702/)].
5. Mittal R. Posttraumatic stiff elbow. *Indian J Orthop.* 2017;**51**(1):4-13. doi: [10.4103/0019-5413.197514](https://doi.org/10.4103/0019-5413.197514). [PubMed: [28216745](https://pubmed.ncbi.nlm.nih.gov/28216745/)]. [PubMed Central: [PMC5296847](https://pubmed.ncbi.nlm.nih.gov/PMC5296847/)].
6. Ring D, Jupiter JB. Operative release of complete ankylosis of the elbow due to heterotopic bone in patients without severe injury of the central nervous system. *J Bone Joint Surg Am.* 2003;**85-A**(5):849-57. doi: [10.2106/00004623-200305000-00012](https://doi.org/10.2106/00004623-200305000-00012). [PubMed: [12728035](https://pubmed.ncbi.nlm.nih.gov/12728035/)].
7. Abrams GD, Bellino MJ, Cheung EV. Risk factors for development of heterotopic ossification of the elbow after fracture fixation. *J Shoulder Elbow Surg.* 2012;**21**(11):1550-4. doi: [10.1016/j.jse.2012.05.040](https://doi.org/10.1016/j.jse.2012.05.040). [PubMed: [22947234](https://pubmed.ncbi.nlm.nih.gov/22947234/)].
8. Jones V. Conservative management of the post-traumatic stiff elbow: A physiotherapist's perspective. *Shoulder Elbow.* 2016;**8**(2):134-41. doi: [10.1177/1758573216633065](https://doi.org/10.1177/1758573216633065). [PubMed: [27583012](https://pubmed.ncbi.nlm.nih.gov/27583012/)]. [PubMed Central: [PMC4950468](https://pubmed.ncbi.nlm.nih.gov/PMC4950468/)].
9. Mellema JJ, Lindenhovius AL, Jupiter JB. The posttraumatic stiff elbow: An update. *Curr Rev Musculoskelet Med.* 2016;**9**(2):190-8. doi: [10.1007/s12178-016-9336-9](https://doi.org/10.1007/s12178-016-9336-9). [PubMed: [26984466](https://pubmed.ncbi.nlm.nih.gov/26984466/)]. [PubMed Central: [PMC4896879](https://pubmed.ncbi.nlm.nih.gov/PMC4896879/)].
10. Davila SA, Johnston-Jones K. Managing the stiff elbow: Operative, non-operative, and postoperative techniques. *J Hand Ther.* 2006;**19**(2):268-81. doi: [10.1197/j.jht.2006.02.017](https://doi.org/10.1197/j.jht.2006.02.017). [PubMed: [16713873](https://pubmed.ncbi.nlm.nih.gov/16713873/)].
11. Morrey BF, Askew LJ, Chao EY. A biomechanical study of normal functional elbow motion. *J Bone Joint Surg Am.* 1981;**63**(6):872-7. doi: [10.2106/00004623-198163060-00002](https://doi.org/10.2106/00004623-198163060-00002). [PubMed: [7240327](https://pubmed.ncbi.nlm.nih.gov/7240327/)].

12. de Carvalho RM, Mazzer N, Barbieri CH. Analysis of the reliability and reproducibility of goniometry compared to hand photogrammetry. *Acta Ortop Bras.* 2012;**20**(3):139-49. doi: [10.1590/S1413-78522012000300003](https://doi.org/10.1590/S1413-78522012000300003). [PubMed: [24453594](https://pubmed.ncbi.nlm.nih.gov/24453594/)]. [PubMed Central: [PMC3718433](https://pubmed.ncbi.nlm.nih.gov/PMC3718433/)].
13. Cusick MC, Bonnaig NS, Azar FM, Mauck BM, Smith RA, Throckmorton TW. Accuracy and reliability of the Mayo Elbow Performance Score. *J Hand Surg Am.* 2014;**39**(6):1146-50. doi: [10.1016/j.jhsa.2014.01.041](https://doi.org/10.1016/j.jhsa.2014.01.041). [PubMed: [24656392](https://pubmed.ncbi.nlm.nih.gov/24656392/)].
14. Filh GM, Galvao MV. Post-traumatic stiffness of the elbow. *Rev Bras Ortop.* 2010;**45**(4):347-54. doi: [10.1016/S2255-4971\(15\)30380-3](https://doi.org/10.1016/S2255-4971(15)30380-3). [PubMed: [27022563](https://pubmed.ncbi.nlm.nih.gov/27022563/)]. [PubMed Central: [PMC4799099](https://pubmed.ncbi.nlm.nih.gov/PMC4799099/)].
15. Othman M, El-Malt A, Nahla A. The outcome of open surgical treatment of posttraumatic elbow stiffness. *J Orthop Ther.* 2018;**2018**(1):2575-8241. doi: [10.29011/2575-8241](https://doi.org/10.29011/2575-8241).
16. Tan V, Daluiski A, Simic P, Hotchkiss RN. Outcome of open release for post-traumatic elbow stiffness. *J Trauma.* 2006;**61**(3):673-8. doi: [10.1097/01.ta.0000196000.96056.51](https://doi.org/10.1097/01.ta.0000196000.96056.51). [PubMed: [16967006](https://pubmed.ncbi.nlm.nih.gov/16967006/)].
17. Park MJ, Kim HG, Lee JY. Surgical treatment of post-traumatic stiffness of the elbow. *J Bone Joint Surg Br.* 2004;**86**(8):1158-62. doi: [10.1302/0301-620X.86B8.14962](https://doi.org/10.1302/0301-620X.86B8.14962). [PubMed: [15568530](https://pubmed.ncbi.nlm.nih.gov/15568530/)].
18. Urbaniak JR, Hansen PE, Beissinger SF, Aitken MS. Correction of post-traumatic flexion contracture of the elbow by anterior capsulotomy. *J Bone Joint Surg Am.* 1985;**67**(8):1160-4. doi: [10.2106/00004623-198567080-00003](https://doi.org/10.2106/00004623-198567080-00003). [PubMed: [4055840](https://pubmed.ncbi.nlm.nih.gov/4055840/)].
19. Gates HS 3rd, Sullivan FL, Urbaniak JR. Anterior capsulotomy and continuous passive motion in the treatment of post-traumatic flexion contracture of the elbow. A prospective study. *J Bone Joint Surg Am.* 1992;**74**(8):1229-34. doi: [10.2106/00004623-199274080-00013](https://doi.org/10.2106/00004623-199274080-00013). [PubMed: [1400551](https://pubmed.ncbi.nlm.nih.gov/1400551/)].
20. Mansat P, Morrey BF. The column procedure: A limited lateral approach for extrinsic contracture of the elbow. *J Bone Joint Surg Am.* 1998;**80**(11):1603-15. doi: [10.2106/00004623-199811000-00006](https://doi.org/10.2106/00004623-199811000-00006). [PubMed: [9840628](https://pubmed.ncbi.nlm.nih.gov/9840628/)].
21. Wada T, Ishii S, Usui M, Miyano S. The medial approach for operative release of post-traumatic contracture of the elbow. *J Bone Joint Surg Br.* 2000;**82**(1):68-73. doi: [10.1302/0301-620X.82B1.9782](https://doi.org/10.1302/0301-620X.82B1.9782). [PubMed: [10697317](https://pubmed.ncbi.nlm.nih.gov/10697317/)].