

Case Report

Irreducible Dislocation of Thumb Interphalangeal Joint: A Case Report



Farid Najd Mazhar¹ , Hooman Shariatzadeh¹ , Meysam Fathi Choghadeh^{1*} , Farhad Soltani¹

1. Bone and Joint Reconstruction Research Center, Shafa Orthopedic Hospital, Iran University of Medical Sciences, Tehran, Iran.



Citation Najd Mazhar F, Shariatzadeh H, Fathi Choghadeh M, Soltani F. Irreducible Dislocation of Thumb Interphalangeal Joint: A Case Report. *Journal of Research in Orthopedic Science*. 2021; 8(4):201-206. <http://dx.doi.org/10.32598/JROSJ.8.4.770.2>

<http://dx.doi.org/10.32598/JROSJ.8.4.770.2>



Article info:

Received: 11 Sep 2021

Revised: 29 Sep 2021

Accepted: 21 Oct 2021

Available Online: 01 Nov 2021

Keywords:

Thumb dislocation,
Irreducible, Interphalangeal
joint

ABSTRACT

Closed dislocation of thumb Interphalangeal (IP) joint is rare, due to the inherent stability of the thumb IP joint. The interposition of the volar plate, flexor pollicis longus, sesamoids, and digital nerves can treat the joint closed reduction. In this study, we report a case of three-week-old irreducible closed dislocation of thumb IP joint in a 33-year-old woman. We planned to perform open reduction surgery using a dorsal approach on the IP joint and the ulnar side opening. The volar plate was interposed in the joint. Seven months after surgery, the patient achieved 0-45 degrees of IP range of motion. No sign of degenerative joint changes on the x-ray images was observed in the final visit. This study suggests the high probability of open reduction for these injuries and recommends the use of dorsal approach, excluding the complications of volar approach.

1. Introduction

The dislocation of the thumb Interphalangeal (IP) joint is not common because of its intrinsic stability; only a few case reports of this method exist in the literature [1-12]. Closed dislocation is even more uncommon. Most reported cases were irreducible to the closed reduction method because of blockade by Flexor Pollicis Longus (FPL), volar plate, sesamoids, and digital nerves. Therefore, many attempts at reducing the joint may cause more injury

[1, 7]. The case we are going to present in this study would be the sixth case of the closed dislocation of the thumb IP joint [1, 7, 8]. We present a case of irreducible closed dislocation of thumb IP joint and share our experience with this rare injury.

2. Case Presentation

The case was a 33-year-old right-hand dominant woman referred to our hand surgery clinic for irreducible closed dislocation of left thumb IP joint. She was a passenger in a car accident when a jammed finger occurred

* Corresponding Author:

Meysam Fathi Choghadeh, MD.

Address: Bone and Joint Reconstruction Research Center, Shafa Orthopedic Hospital, Iran University of Medical Sciences, Tehran, Iran.

Phone: +98 (912) 1168836

E-mail: mchfathi@gmail.com

in her right thumb when wanted to grasp the car seat to maintain her balance resulting in a hyperextended and twisting injury. The patient noted that her right thumb was deformed considerably, and she pulled it back to set with the other hand. Three weeks prior to her presentation, she was diagnosed with the thumb IP joint dislocation in another center and had undergone closed reduction under local anesthesia and splinting. However, after removing the splint, the physician noticed a stiffness. After repeating the x-ray, a persistent dislocation was reported and closed reduction was conducted again which was unsuccessful and she was referred to our clinic. The appearance of the injured thumb was almost the same as the uninjured one; she had only stiffness and slight swelling around the IP joint. At first, she had doubts about receiving further treatment, as her both thumbs looked almost the same. The skin was intact, and capillary filling and sensation of both thumbs were the same. A radiograph was taken which showed the IP joint was still dislocated (Figure 1).

The patient was scheduled for surgery on the same day. Under GA, the closed reduction did not seem possible since there was no obvious deformity. After tourniquet inflation using a lazy S incision, the extensor tendon exposed from the ulnar side of the joint, which was displaced and wide open; we detected the radial collateral ligament rupture. A freer elevator was introduced into the joint through the dorso-radial soft tissue opening created by the injury. The volar plate was interposed in the joint which blocked the reduction; it was pushed back to its place and the joint was reduced. The stability was then checked, which was good during flexion and extension. There was only a slight instability under stress testing radially. The joint was fixed with a 1-mm K-wire, and the reduction was checked under C-arm, which was at good condition (Figure 2). Three weeks after the surgery, K-wire and sutures were removed (Figure 3), and the patient was sent for rehabilitation. However, the patient took only five physiotherapy sessions due to her business. Seven months after surgery, the patient was examined for the outcome. The scar was flat and painless. She was free of pain with 45 degrees of active and passive IP flexion. There was about 5 degrees of extension lag compared to the contralateral side. The pinch strength of her right and left hands were 6.5 kg and 5 kg, respectively. The grip force for both hands was 20 kg. At the final follow-up session seven months after surgery, the visual analog scale score was two, and the quick Disabilities of Arm, Shoulder & Hand (DASH) score was 4.54.

3. Discussion

The Thumb IP joint is inherently stable and does not dislocate easily [7, 9, 11]. The dislocation occurs after hyperextension under either axial load or rotatory force. [2] To our knowledge, there are only five cases of irreducible closed dislocation of thumb IP joint in the literature among sixteen reported cases [1, 7, 8]. Most of the previously reported cases were irreducible because of interposed FPL, Sesamoids, digital nerve, or a combination of them [2, 7, 9-12]. The most common blocking structure is the volar plate avulsion in the proximal phalanx, as reported in our case [1-5, 10, 11]. There are still controversies in managing this injury; most of the studies have used different techniques to reduce the joint [2]. Due to its rarity, reaching a consensus on its management is complicated, since each patient needs its own approach. According to previous reports, each patient can choose a method that is better for him/her based on the patient-specific injury. We classified the information in previously published case reports in Table 1.

Nakae et al. [8] treated two cases with closed reduction; other authors, although initially tried the closed reduction under the regional block, had to shift to open reduction because of the joint irreducibility. Close reduction should be performed with caution at least two times because of the possibility of imposing more injury to the blocking structures [8]. In our case, we did not try to perform closed reduction because it seemed impossible to reduce the dislocated joint after three weeks; hence, we first preferred open reduction using a dorsal approach.

Kubota et al. used volar approach in two cases as the dislocations were irreducible [1], and Naito et al. used a radial-side minimally invasive approach to unblock the joint by pulling out the FPL tendon [7]. The dorsal approach may be proper for closed dislocations as one can push the interposed structures back to their place via the dorsal joint line. Moreover, the dorsal approach is less invasive and imposes less soft tissue irritation, minimizing the possibility of post-operative complications. However, it is logical to start with the volar approach in open dorsal dislocations as there is already a wound on the volar aspect. Most studies have used only the volar approach in open dislocated cases of the thumb IP joint. However, after facing difficulties, Sabapathy et al. and Greenfield et al. used the dorsal approach to reduce the joint with a volar injury [5, 9]. Kitawaga and Kashimoto used the ulnar mid-lateral incision [6].

Table 1. Summary of previously published case reports

Author(s)	Year of Publication	Patients	Blocking Structure	Open/Closed Reduction	Manipulation Before Surgery	Cause of Injury	Time of Admission	F/U	Approach	Outcome
Kubota et al. [1]	2009	A 46-year-old F at R	VP	Closed	Before surgery	Falling from ladder	Immediately after the injury	15 months	Volar	0-45 degrees
		29-year-old M at R	VP	Closed	Before surgery	During playing basketball	Immediately after the injury.	13 months	Volar	0-70 degrees
Naito et al. [7]	2014	A 63-year-old F at R	FPL	Closed	Before surgery	Falling	Immediately after the injury	12 months	Radial-side minimally invasive	0-45 degrees
Nakae et al. [8]	1996	A 38-year-old M at R	-	Closed	-	During playing Ski	Immediately after the injury	Eight months	Axial traction	Full painless
		A 21-year-old M at R	-	Closed	-	Pulled	Immediately after the injury	Three months	Axial traction and flexion	Full painless
Shah et al. [11]	2010	A 32-year-old M at R	VP, digital nerve, FPL	Open	0	In an alteration	Immediately after injury	Lost to follow-up	Volar	Lost to follow-up
Sabathy et al. [9]	1994	A 32-year-old M R	Sesamoid	Open	Three efforts	Falling from motorcycle	Two days earlier	12 months	Dorsal application after failed volar	Stiffness at ten flexion; no passive and active motion (due to sepsis)
Kitawaga & Kashimoto [6]	1984	A 36-year-old M	Sesamoid	Open	Once by bonesetter	During playing softball	Ten days after injury	Three months	Ulnar midlateral incision	0-45 degrees
Salamon & Gelberman [10]	1978	A 26-year-old F at R	FPL	Open	One effort	Falling	not mentioned	-	Volar	No sequelae
		A 31-year-old M at L	VP	Open	Several	Falling	not mentioned	-	Volar	No sequelae
		A 14-year-old M at R	VP	Open	Several	Falling	not mentioned	-	Volar	No sequelae
Alexander [2]	2020	A 36-year-old M at L	VP, sesamoid, FPL, radial digital nerve	Open	Several by ED physicians	During playing football	Immediately after the injury.	Six months	Volar	0-80 degrees of active motion, 0-85 degrees of passive motion
Brown et al. [12]	2016	A 23-year-old M at R	Digital nerve	Open	Several	During playing basketball	Immediately after the injury.	-	-	Not mentioned
Failla [3]		A 24-year-old M at L	VP, FPL	Open	One effort	During playing softball	Immediately after the injury	Three months	Volar	0-45 degrees
Gerard [4]	1998	A 34-year-old M at R	VP	Open	0	Falling from the bicycle	Not mentioned	Seven months	Volar	0-40 degrees
Greenfield [5]	1981	A 23-year-old M at R	VP, sesamoid	Open		not remembered	Immediately after the injury	One month	Dorsal longitudinal application after failed volar	Full pain free range of motion

M: Male; F: Female; R: Right hand; L: Left hand; VP: Volar Plate; F/L: Follow up.

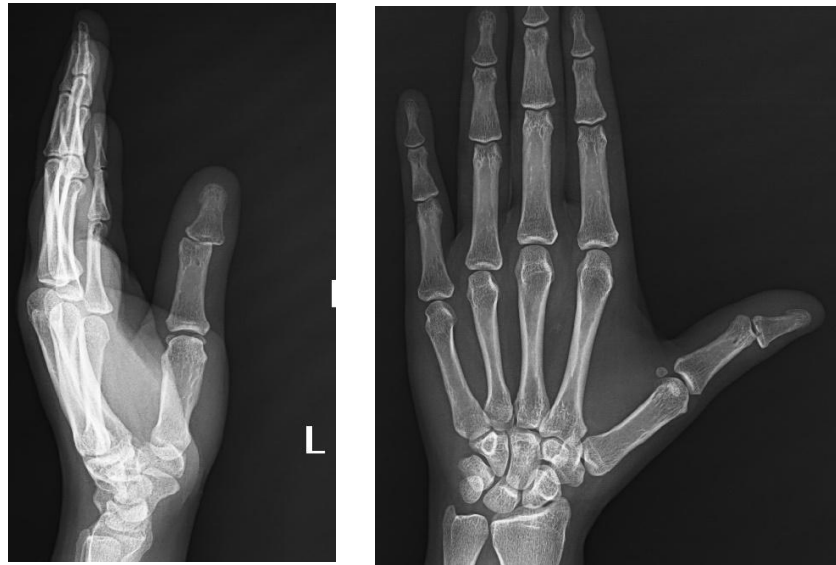


Figure 1. Pre-operative x-ray showing the thumb IP joint dislocation

Journal of Research in
Orthopedic Science

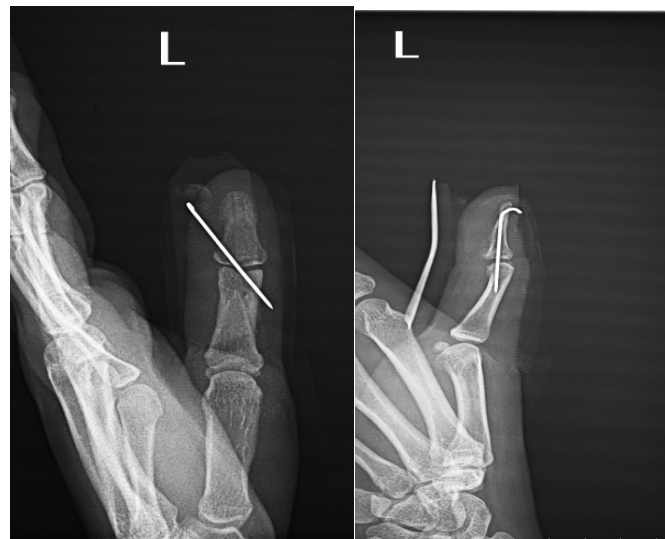

Figure 2. Post-operative x-ray

Journal of Research in
Orthopedic Science

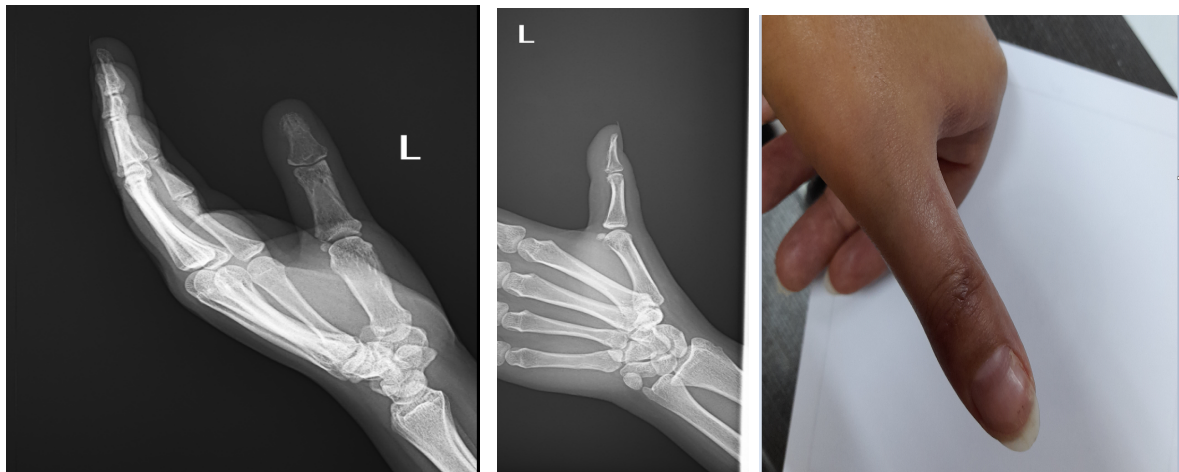


Figure 3. The photo and x-ray of the thumb seven months after surgery

Journal of Research in
Orthopedic Science

There is still no consensus on repairing the volar plate and collaterals after open reduction. Different surgeons used various treatments for volar plate and collateral ruptures; some prefer to repair them and some leave the ruptures to be healed spontaneously. The proponents of repair approach believe that the instability after reduction indicates the need for repair. With the anatomic reduction and three weeks of immobilization, we believe that there might be no need for additional repair as there is no such phenomenon as a stener lesion in interphalangeal joints. Gerard stated that a congruous joint immobilization with moderate flexion for three weeks is enough for fingers' proximal IP joint dislocations.

Gerard et al. did not use the repair method [4]. Kitagawa and Kashimoto used the pull-out technique to repair the collateral ligaments [6], while Salamon and Gelberman left them unrepaired [10]. Kubota et al. also performed no repair of the collaterals in two cases; instead, they fixed the joint in slight flexion with k-wire, and the joints were stable postoperatively [1]. All authors agreed on splinting the joint in slight flexion (10-20 degrees) after reduction. In these studies, about half of the patients in both closed and open thumb IP dislocations have regained full pain free range of motion and others achieved almost 45 degrees of IP flexion.

The patient in our study gained 0-45 degrees of range of motion using just three physiotherapy sessions and left the rehabilitation program as she was satisfied with her thumb function. It seems that 45 degrees of flexion is the least range of motion, and the surgeons should acknowledge the possibility of joint stiffness.

Closed dislocation of thumb IP joint is rare. It can be easily neglected, and its treatment is challenging. We recommend that physicians should examine the thumb IP joint after any trauma and speculate carefully based on the radiography images and consider the possibility of dislocations. Since many attempts to reduce the joint can make it more complicated and cause more injury, it is better to refer the patient to a physician; the attempt for closed reduction should be made by the physician, and be ready for open reduction, if necessary.

Ethical Considerations

Compliance with ethical guidelines

There were no ethical considerations to be considered in this research.

Funding

This research did not receive any grant from funding agencies in the public, commercial, or non-profit sectors.

Authors' contributions

Conceptualization and design: Hooman Shariatzadeh and Farid Najd Mazhar; Data collection, Writing-original draft: Meysam Fathi Choghadeh; Data collection: Farhad Soltani.

Conflict of interest

The authors declared no conflict of interest.

References

- [1] Kubota R, Nozawa M, Matsuda K, Kim S. Closed irreducible dislocation of the interphalangeal joint of the thumb: Report of two cases. *Chir Organi Mov.* 2009; 93(2):85-8. [DOI:10.1007/s12306-009-0026-2] [PMID]
- [2] Alexander L. Complex irreducible dorsal dislocation of thumb interphalangeal joint: Controversies and consensus in management. *J Hand Surg Asian Pac Vol.* 2020; 25(3):378-83. [DOI:10.1142/S2424835520720133] [PMID]
- [3] Failla JM. Irreducible thumb interphalangeal joint dislocation due to a sesamoid and palmar plate: A case report. *J Hand Surg Am.* 1995; 20(3):490-1. [DOI:10.1016/S0363-5023(05)80114-5]
- [4] Gerard F, Pem R, Garbuio P, Obert L, Tropet Y. Irreducible dorsal dislocation of the interphalangeal joint of the thumb due to the palmar plate. A case report. *Ann Chir Main Memb Super.* 1998; 17(1):63-7. [DOI:10.1016/S0753-9053(98)80022-7]
- [5] Greenfield GQ, Jr. Dislocation of the interphalangeal joint of the thumb. *J Trauma.* 1981; 21(10):901-2. [PMID]
- [6] Kitagawa H, Kashimoto T. Locking of the thumb at the interphalangeal joint by one of the sesamoid bones. A case report. *J Bone Joint Surg Am Vol.* 1984; 66(8):1300-1. [DOI:10.2106/00004623-198466080-00022]
- [7] Naito K, Sugiyama Y, Igeta Y, Kaneko K, Obayashi O. Irreducible dislocation of the thumb interphalangeal joint due to displaced flexor pollicis longus tendon: Case report and new reduction technique. *Arch Orthop Trauma Surg.* 2014; 134(8):1175-8. [DOI:10.1007/s00402-014-2024-6] [PMID]
- [8] Nakae H, Endo S, Hoshi S. Two cases of closed dislocation of the interphalangeal joint of the thumb. *Arch Orthop Trauma Surg.* 1996; 115(3-4):236-7. [DOI:10.1007/BF00434563] [PMID]

- [9] Sabapathy SR, Bose VC, Rex C. Irreducible dislocation of the interphalangeal joint of the thumb due to sesamoid bone interposition: A case report. *J Hand Surg.* 1995; 20(3):487-9. [DOI:10.1016/S0363-5023(05)80113-3]
- [10] Salamon PB, Gelberman RH. Irreducible dislocation of the interphalangeal joint of the thumb. *J Bone Joint Surg.* 1978; 60(3):400-1. [DOI:10.2106/00004623-197860030-00025]
- [11] Shah SR, Bindra R, Griffin JW. Irreducible dislocation of the thumb interphalangeal joint with digital nerve interposition: Case report. *J Hand Surg Am.* 2010; 35(3):422-4. [PMID]
- [12] Brown DJ, Parcels AL, Granick MS. Thumb interphalangeal joint dislocation. *Eplasty.* 2016; 16:ic2. [PMID]